

**PATIENT**

Imoen Covi

**SPECIES**

Feline

**BREED**

Domestic Shorthair

**SEX**

Intact female

**AGE**

10 years

**WEIGHT**

7.6 lbs

**INTERPRETED BY**

Eric Lindquist, DMV,  
 DABVP, Cert. IVUSS,  
 CEO of SonoPath.com

**IMAGING PERFORMED BY**

Amanda Stewart

**HOSPITAL NAME**

Halton Peel AH

**REFERRING VET**

Dr. Walters

**INVOICE**

69615

**DATE**

12/12/25

**PRESENTING CLINICAL SIGNS**

History: Findings: Blood including feline viral test NAF Primary Question to Be Answered in This Exam Cat was adopted from rescue as a spayed female, but owner describes cycling since she got her (and no evidence of scar); Specifically looking for uterus

**ULTRASONOGRAPHIC EXAMINATION OF THE ABDOMEN**

**Urinary System**

The **urinary bladder**, trigone, and pelvic urethra presented normal thicknesses and normal tone. The ureters were not visible which is normal. No uroliths or sediment were visualized and anechoic urine was present. No evidence of inflammatory or neoplastic changes was noted. Ureteral papillae were normal.

The **kidneys** revealed normal size and structure, corticomedullary definition and ratio for this age. The cortices presented largely uniform texture with normal echogenic relationship to liver and spleen. Medullary structure differed distinctly from the cortex and no evidence of pelvic dilation was present. The capsules were acceptably uniform without significant irregularities. The right kidney measured 3.8 cm. The left kidney measured 3.7 cm.

The left ovary was uniform and measured 0.95 cm. The right ovary was cystic and measured 1.4 cm. The uterus was mildly thickened in this patient and measured 0.93 cm. The uterine horns were dilated and measured up to 1.4 cm with echogenic fluid. This is consistent with pyometra.

**Adrenal Glands**

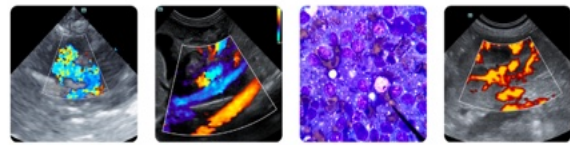
Both **adrenal glands** were visualized and recognized as having normal shape, size, position and echogenicity for this breed. The phrenic vasculature, glandular echogenicity and detail were unremarkable. Capsule, cortex, and medullary definition were normal for this age patient. The right adrenal gland measured 0.35 cm. The left adrenal gland measured 0.4 cm.

**Spleen**

The **spleen** presented a smooth homogeneous parenchyma hyperechoic to liver and renal cortical parenchyma. The capsule was smooth without noticeable expansion or deviation from within the spleen or adjacent pathology. The splenic vasculature demonstrated normal volume without signs of congestion or thrombosis. No sonographic evidence of acute or chronic inflammatory, neoplastic, or infarctual changes was noted.

**Liver**

The **liver** images submitted revealed subjectively normal liver size, contour, and structure. Parenchymal echogenicity was naturally coarse and hypoechoic to the spleen. Vascular and biliary tracts were of normal volume with no evidence of congestion. The gallbladder presented acceptably thin walls with



**PATIENT**

Imoen Covi

primarily anechoic content. The cystic and common bile ducts were normal. No pathological hepatic lymphadenopathy was evident. No overt structural evidence of inflammatory, infiltrative or regenerative pathology was evident.

**SPECIES**

Feline

**Gastrointestinal**

**BREED**

Domestic Shorthair

Examination of the **gastrointestinal tract** revealed a stomach and intestine free of stasis, of normal wall thickness, acceptable curvilinear mural detail, and peristaltic activity. Hairball density was noted in the stomach. Small and large intestine demonstrated normal luminal chyme and stool consistency respectively. No obstructive or overt infiltrative disease was noted. No associated abnormal lymphatic activity was noted.

**SEX**

Intact female

**Pancreas**

**AGE**

10 years

The base and limbs of the **pancreas** were observed to be largely isoechoic to surrounding omental fat. Pancreatic duct and capsular contour were acceptably normal and parenchyma respected normal curvilinear patterns. No overt evidence of active inflammatory or neoplastic disease was noted.

**WEIGHT**

7.6 lbs

**ULTRASONOGRAPHIC FINDINGS**

**INTERPRETED BY**

Eric Lindquist, DMV,  
DABVP, Cert. IVUSS,  
CEO of SonoPath.com

- Cystic right ovary and pyometra.
- Hairball density in the stomach.

**INTERPRETATION OF THE FINDINGS & FURTHER RECOMMENDATIONS**

Immediate ovariohysterectomy is recommended in this patient. Medical management for hairballs should prove adequate for management of the GI presentation.

**IMAGING PERFORMED BY**

Amanda Stewart

**HOSPITAL NAME**

Halton Peel AH

**REFERRING VET**

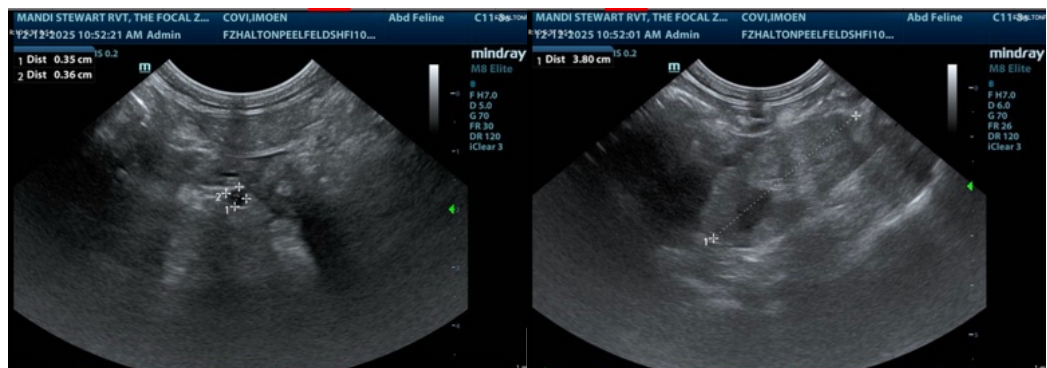
Dr. Walters

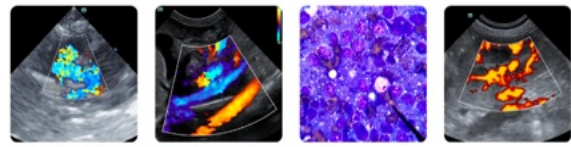
**INVOICE**

69615

**DATE**

12/12/25





**PATIENT**

Imoen Covi

**SPECIES**

Feline

**BREED**

Domestic Shorthair

**SEX**

Intact female

**AGE**

10 years

**WEIGHT**

7.6 lbs

**INTERPRETED BY**

Eric Lindquist, DMV,  
 DABVP, Cert. IVUSS,  
 CEO of SonoPath.com

**IMAGING PERFORMED BY**

Amanda Stewart

**HOSPITAL NAME**

Halton Peel AH

**REFERRING VET**

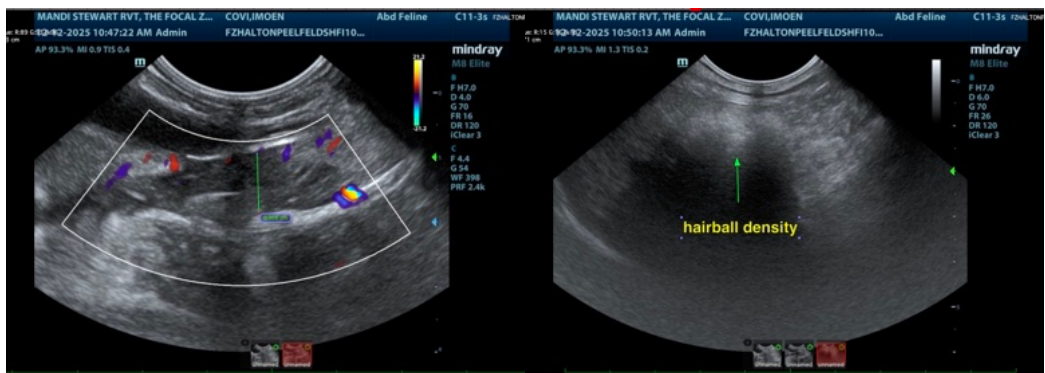
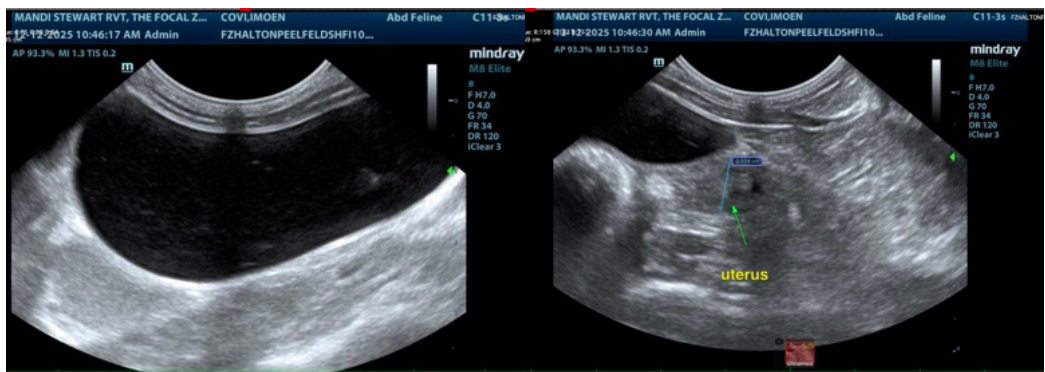
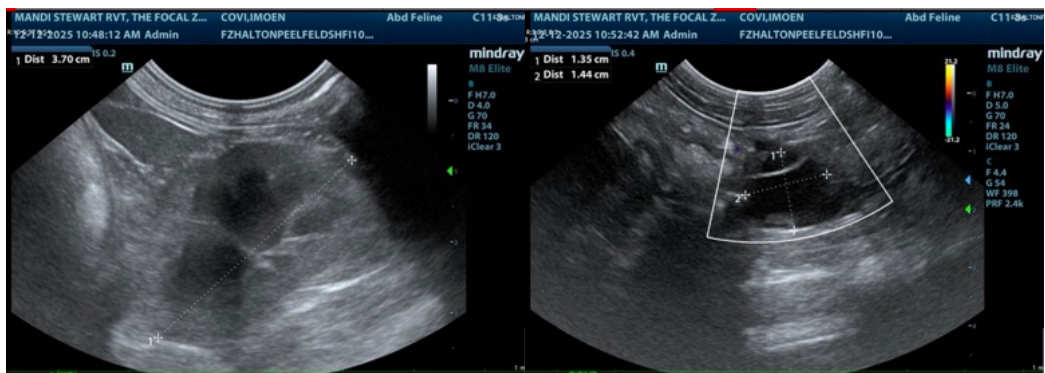
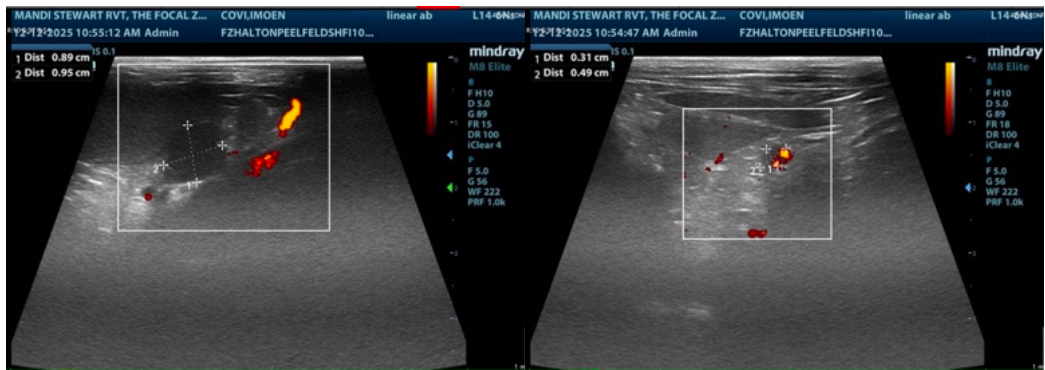
Dr. Walters

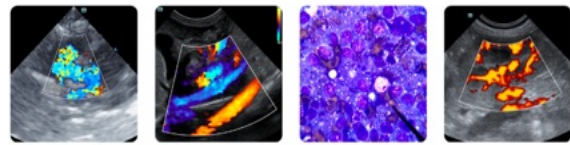
**INVOICE**

69615

**DATE**

12/12/25





**PATIENT**

Imoen Covi

**SPECIES**

Feline

**BREED**

Domestic Shorthair

**SEX**

Intact female

**AGE**

10 years

**WEIGHT**

7.6 lbs

**INTERPRETED BY**

Eric Lindquist, DMV,  
DABVP, Cert. IVUSS,  
CEO of SonoPath.com

**IMAGING PERFORMED BY**

Amanda Stewart

**HOSPITAL NAME**

Halton Peel AH

**REFERRING VET**

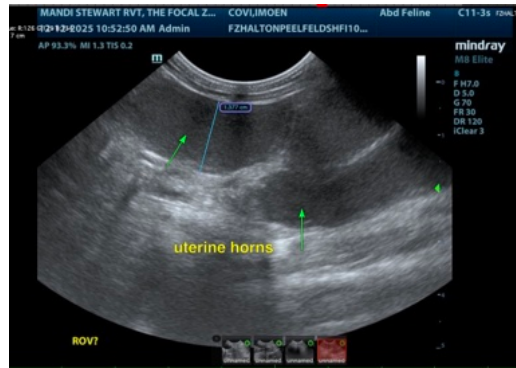
Dr. Walters

**INVOICE**

69615

**DATE**

12/12/25



The information and recommendations provided are based on the images presented by the referring veterinarian/sonographer. No evaluation can be communicated regarding pathology that was not visible in the image/video clips provided.

Thank you for this referral. If the clinical or image interpretation does not parallel your findings or if I can be of any further assistance please contact me.

**Eric Lindquist**, DMV, DABVP, Cert. IVUSS, CEO of SonoPath.com

[info@SonoPath.com](mailto:info@SonoPath.com)