



**PATIENT**

Fibi Oulette Lucier

**SPECIES**

Canine

**BREED**

Poodle

**SEX**

Spayed Female

**AGE**

6 years

**WEIGHT**

9.6 lbs

**INTERPRETED BY**

Eric Lindquist, DMV  
DABVP, Cert. IVUSS

**IMAGING  
PERFORMED BY**

Kelly Reshny, RVT

**HOSPITAL NAME**

Southside Pet Hospital

**REFERRING VET**

Dr. Honda

**INVOICE**

94117

**DATE**

11/25/21

**PRESENTING CLINICAL SIGNS**

History: Off food for 7 days but hasn't been eating well for most of her life so initially owner not worried. Suddenly Pu/Pd in last 3 days. No vomiting. Wt loss noted. nsf on GPE currently on: Convenia injection, stomach support meds declined for now  
Abnormal PE/Chem/CBC/UA Results: SDMA 28, Urea 19.5, Creat 253 (normally has been low at 40 - poorly muscled dog) K+ 3.9 USG 1.010, quiet sediment UPC 1

**ULTRASONOGRAPHIC EXAMINATION OF THE ABDOMEN**

**Urinary System**

The **urinary bladder**, trigone, and pelvic urethra presented normal thicknesses and normal tone. The ureters were not visible which is normal. No uroliths or sediment were visualized and anechoic urine was present. No evidence of inflammatory or neoplastic changes was noted. Ureteral papillae were normal.

The **kidneys** were both hypervascular and swollen with enhanced, pericapsular inflammatory pattern. Structurally the kidneys were unremarkable. The left kidney measured 4.64 cm. The right kidney measured 5.0 cm with mild pyelectasia.

**Adrenal Glands**

The right **adrenal gland** is slightly enlarged at the cranial pole measuring 0.96 cm and 1.75 cm in length and 0.51 cm at the caudal pole. The left adrenal gland measured 1.94 x 0.42 cm at the caudal pole and 0.5 cm at the cranial pole.

**Spleen**

The **spleen** presented a smooth homogeneous parenchyma hyperechoic to liver and renal cortical parenchyma. The capsule was smooth without noticeable expansion or deviation from within the spleen or adjacent pathology. The splenic vasculature demonstrated normal volume without signs of congestion or thrombosis. No sonographic evidence of acute or chronic inflammatory, neoplastic, or infarctual changes was noted.

**Liver**

The **liver** images submitted revealed subjectively normal liver size, contour, and structure. Parenchymal echogenicity was naturally coarse and hypoechoic to the spleen. Vascular and biliary tracts were of normal volume with no evidence of congestion. The gallbladder presented acceptably thin walls with primarily anechoic content. The cystic and common bile ducts were normal. No pathological hepatic lymphadenopathy was evident. No overt structural evidence of inflammatory, infiltrative or regenerative pathology was evident.



**PATIENT**

**Gastrointestinal**

Fibi Oulette Lucier

Examination of the **gastrointestinal tract** revealed a stomach and intestine free of stasis, of normal wall thickness, acceptable curvilinear mural detail, and peristaltic activity. Small and large intestine demonstrated normal luminal chyme and stool consistency respectively. No obstructive or overt infiltrative disease was noted. No associated abnormal lymphatic activity was noted.

**SPECIES**

Canine

**BREED**

Poodle

**SEX**

Spayed Female

**AGE**

6 years

**WEIGHT**

9.6 lbs

**Pancreas**

The base and limbs of the **pancreas** were observed to be largely isoechoic to surrounding omental fat. Pancreatic duct and capsular contour were acceptably normal and parenchyma respected normal curvilinear patterns. No overt evidence of active inflammatory or neoplastic disease was noted.

**ULTRASONOGRAPHIC FINDINGS**

Non-specific acute aggressive, bilateral nephritis pattern.

Acute renal injury such as Leptospirosis. Other infectious toxin exposure is all possible.

**INTERPRETATION OF THE FINDINGS & FURTHER RECOMMENDATIONS**

Blood pressure, coagulation panel and 25 gauge FNA of either renal cortex could be considered. There is a mild potential for emerging renal neoplasia/lymphoma that can appear similarly at a very early stage. The prognosis is extremely guarded.

**INTERPRETED BY**

Eric Lindquist, DMV  
DABVP, Cert. IVUSS

**IMAGING PERFORMED BY**

Kelly Reshny, RVT

**HOSPITAL NAME**

Southside Pet Hospital

**REFERRING VET**

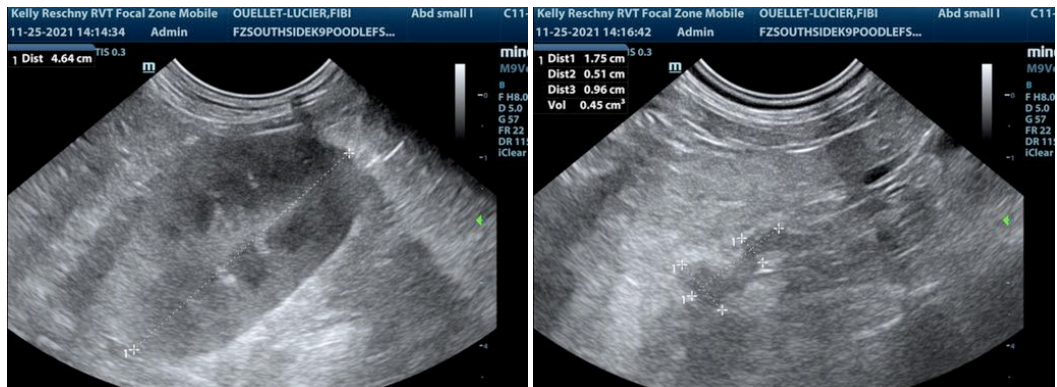
Dr. Honda

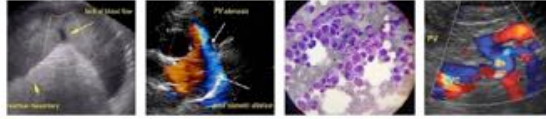
**INVOICE**

94117

**DATE**

11/25/21





**PATIENT**

Fibi Oulette Lucier

**SPECIES**

Canine

**BREED**

Poodle

**SEX**

Spayed Female

**AGE**

6 years

**WEIGHT**

9.6 lbs

**INTERPRETED BY**

Eric Lindquist, DMV  
DABVP, Cert. IVUSS

**IMAGING  
PERFORMED BY**

Kelly Reshny, RVT

**HOSPITAL NAME**

Southside Pet Hospital

**REFERRING VET**

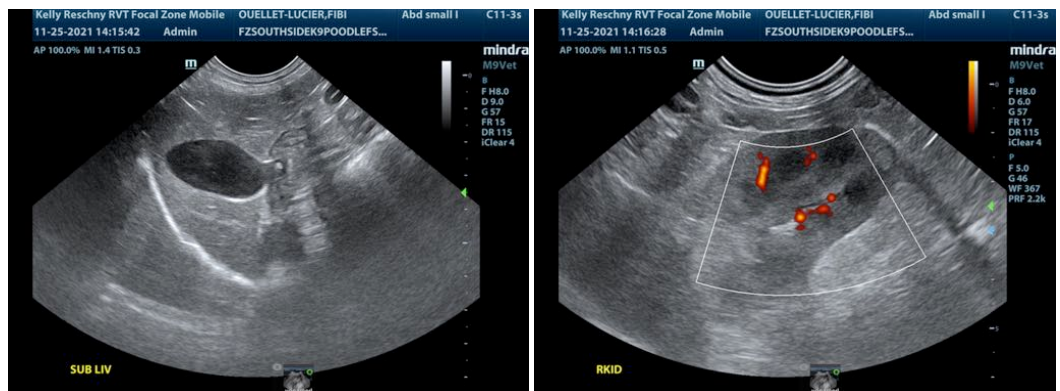
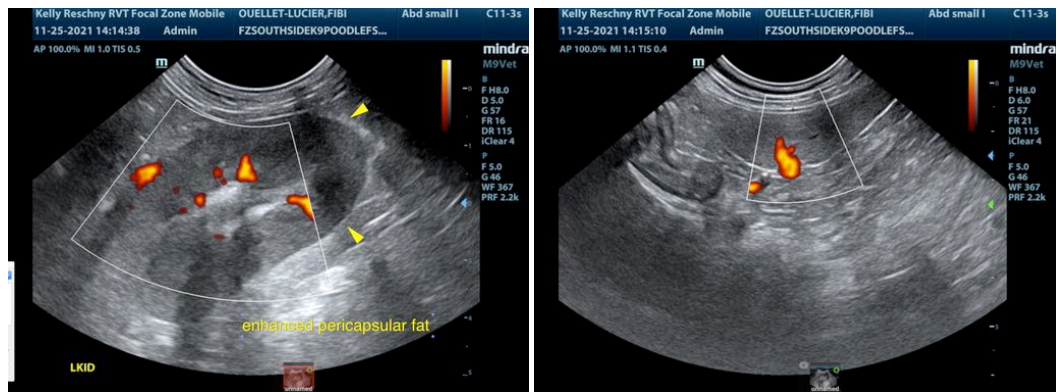
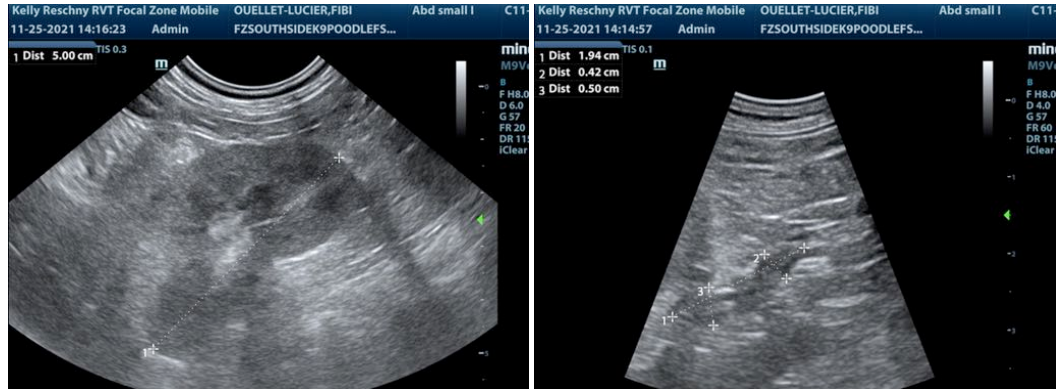
Dr. Honda

**INVOICE**

94117

**DATE**

11/25/21



The information and recommendations provided are based on the images presented by the referring veterinarian. No evaluation can be communicated regarding pathology that was not visible in the image/video clips provided.

Thank you for this referral. If the clinical or image interpretation does not parallel your findings or if I can be of any further assistance please contact me.

Eric Lindquist, DMV, DABVP, Cert. IVUSS, CEO of SonoPath.com  
[Eric.Lindquist@SonoPath.com](mailto:Eric.Lindquist@SonoPath.com)



**PATIENT**

Fibi Oulette Lucier

**SPECIES**

Canine

**BREED**

Poodle

**SEX**

Spayed Female

**AGE**

6 years

**WEIGHT**

9.6 lbs

**INTERPRETED BY**

Eric Lindquist, DMV  
DABVP, Cert. IVUS

**IMAGING  
PERFORMED BY**

Kelly Reshny, RVT

**HOSPITAL NAME**

Southside Pet Hospital

**REFERRING VET**


Dr. Honda

**INVOICE**

94117

**DATE**

11/25/21



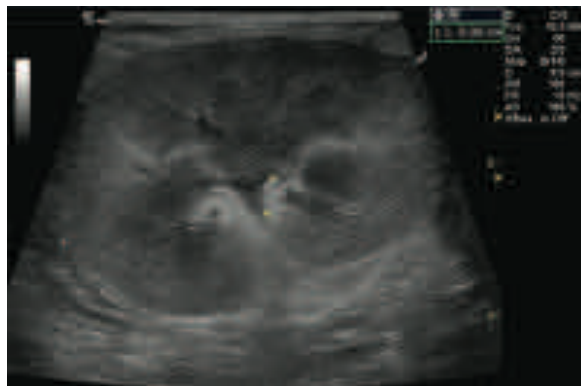The following is an applicable excerpt from the *Curbside Guide to Diagnosis & Treatment of Sonographic Disease* offered by [SonoPath.com](http://SonoPath.com) Lindquist, Frank, Lobetti, and Modler.

An essential quick guide for every general practitioner and sonographer.

<https://sonopath.com/products/curbside-guide-editing-due-release-12012015>

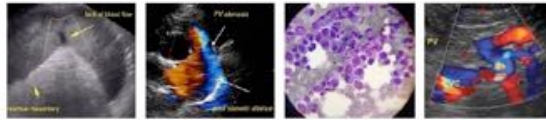
**Acute Renal Failure**

<http://www.sonopath.com/ARF>



Long axis of the kidney in a cat with a renal transplant and acute renal failure. Note the generalized swelling of the kidney with loss of corticomedullary definition. The renal pelvis shows mild dilation with anechoic content (arrow heads). The renal crest and sinus are hyperechoic.

**Description:** Acute renal failure (ARF)—also referred to as acute kidney injury—is defined as a rapid deterioration in renal function that results in the accumulation of metabolic waste in the body. It is characterized by an impaired regulation of water and solute balances, and may be due to prerenal, postrenal, and/or primary renal causes. Prerenal azotemia reflects a reduced glomerular filtration rate (GFR), which is a consequence of renal hypoperfusion; it is not the result of structural renal damage. Immediate restoration of renal blood flow will reverse the azotemia over a period of time; however, if the hypoperfusion is severe or prolonged, or if there is prior renal dysfunction, acute primary renal failure due to ischemic acute tubular necrosis will be induced. Postrenal azotemia occurs when urine flow is obstructed or the excretory pathway is ruptured and there is subsequent urine resorption. Persistent urinary obstruction may cause irreversible renal damage. Early detection of postrenal azotemia will result in complete restoration of renal function. Acute tubular necrosis accounts for the majority of acute primary renal failure cases and is characterized by an abrupt and sustained reduction in GFR due to an ischemic or toxic renal insult. The conditions that incite ischemia are the same as those for prerenal azotemia; however, the duration of the ischemia is important. Nephrotoxins are a frequent cause of tubular necrosis. The high rates of blood flow and metabolic activity in the kidneys as well as their excretory function predispose dogs and cats to the toxic effects of drugs as well as endogenous or exogenous toxins.



**PATIENT**

Fibi Oulette Lucier

**SPECIES**

Canine

**BREED**

Poodle

**SEX**

Spayed Female

**AGE**

6 years

**WEIGHT**

9.6 lbs

**INTERPRETED BY**

Eric Lindquist, DMV  
DABVP, Cert. IVUSS

**IMAGING PERFORMED BY**

Kelly Reshny, RVT

**HOSPITAL NAME**

Southside Pet Hospital

**REFERRING VET**

Dr. Honda

**INVOICE**

94117

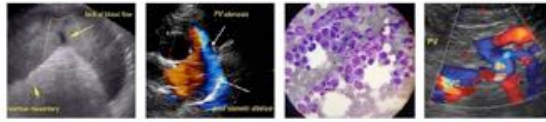
**DATE**

11/25/21

**Clinical Signs:** The clinical course in acute tubular necrosis can be divided into three phases: an initiating phase, a maintenance phase, and a recovery phase. The initiating phase, which is marked by the onset of renal injury, is the period in which there is the greatest potential for preventing or reversing tubular damage and the progression to overt renal failure because it is during this period that renal cell damage develops. The challenge, however, is that the initiating phase may only become evident in retrospect as it generally lacks characteristic signs. The maintenance phase is characterized by the onset of oliguria (i.e., urine production is less than 1ml/kg/hour). The onset of this phase typically occurs during the first 24 hours, but may be delayed for up to 1 week. The duration of this phase is highly variable, but usually persists for up to 2 weeks. It is characterized by: fluid and electrolyte imbalances, including an alteration in hydration; hyponatremia; hyperkalemia; high anion gap metabolic acidosis; hypocalcemia; hyperphosphatemia; and azotemia. Clinical signs include gastrointestinal, hematological, and neurological manifestations of renal failure. The recovery phase commences when the GFR increases, which consequently slows down and reverses the azotemia. There is a progressive increase in urine volume, and although the tubular function begins to improve, it nevertheless remains impaired. Diuresis persists because of the diminished ability of the tubules to reabsorb sodium and respond to vasopressin. Clinical manifestations observed in the maintenance phase persist into the recovery phase. In some patients, infections and/or gastrointestinal bleeding may occur. Sites of infection include the respiratory tract, operative sites, and the urinary tract. Septicemia may also occur and is sometimes the result of intravenous and urinary indwelling catheters.

**Diagnostics:** Extraordinary disorders that produce prerenal azotemia are associated with concentrated, hypersthenuric urine, which contains a relatively low concentration of sodium and high concentration of creatinine. ARF is typically characterized by enlarged or swollen kidneys, elevated hematocrit, and azotemia. Urine is isosthenuric or minimally concentrated, and contains high concentrations of creatinine. Proteinuria or glycosuria may also accompany this condition. The sediment will show casts and RTE cells. Complete anuria is usually associated with postrenal azotemia. Features that are typical for acute tubular necrosis include: anuria in the absence of a urinary tract obstruction or rupture; severe proteinuria; significant hematuria with red cell casts; and prolonged oliguria. In these cases, a diagnostic renal biopsy is indicated.

**Treatment:** Most patients with ARF are volume depleted. Fluid therapy is indicated to correct dehydration, which will restore adequate renal perfusion and may prevent further renal damage. If the etiology was prerenal in origin, then urine volume will increase. In the maintenance phase, fluid therapy should be directed toward maintaining fluid balance and preventing both overhydration and dehydration. In cases of renal disease it is important that only maintenance needs and ongoing losses are attended to as overhydration can develop if there is reduced renal function. Insensible losses are calculated at 20 ml/kg/day. Aggressive fluid therapy during the recovery phase may perpetuate polyuria. As the urine volume stabilizes, the volume of fluid administered should be reduced correspondingly. Because dehydration may occur during this phase, one should monitor body weight and clinically assess the hydration status as fluid therapy is being reduced. Oliguric patients who are unresponsive to fluid volume replacement can be treated with mannitol, furosemide, and/or dopamine in an attempt to increase GFR and urine volume. Hyperkalemia is commonly associated with the maintenance phase of ARF. Concentrations greater than 6 mmol/l may require treatment with sodium bicarbonate, dextrose, insulin and/or calcium gluconate. Hemodialysis should be considered in patients with severe, persistent uremia, acidosis, or hyperkalemia. It may also be used to treat overhydration and hasten the elimination of nephrotoxins.



**PATIENT**

Fibi Oulette Lucier

**Conclusion:** Because ARF is frequently iatrogenic and associated with nephrotoxic drugs or inadequate fluid therapy, prevention is the best therapy.

**SPECIES**

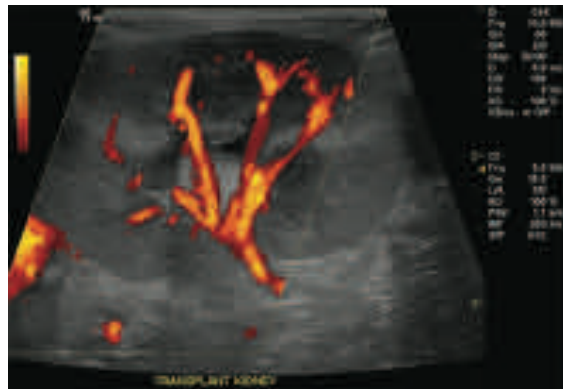Canine

**BREED**

Poodle

**SEX**

Spayed Female



Long axis of the kidney of the same cat as in the previous title image. Note the non-uniform power Doppler signal distribution with significant hypovascularity of the cranial pole compatible with regional infarction and transplant failure.

**AGE**

6 years

**References:**

**WEIGHT**

9.6 lbs

Acierno MJ, Maeckelbergh V. Continuous renal replacement therapy. *Compend Contin Educ Vet* 2008;30:264-72.

**INTERPRETED BY**

Eric Lindquist, DMV  
DABVP, Cert. IVUSS

Grauer GF. Early detection of renal damage and disease in dogs and cats. *Vet Clin North Am Small Anim Pract* 2005;35:581-96.

**IMAGING PERFORMED BY**

Kelly Reshny, RVT

Labato MA. Strategies for management of acute renal failure. *Vet Clin North Am Small Anim Pract* 2001;31:1265-87.

**HOSPITAL NAME**

Southside Pet Hospital

Ross L. Acute kidney injury in dogs and cats. *Vet Clin North Am Small Anim Pract* 2011;41:1-14.

**REFERRING VET**

Dr. Honda

**INVOICE**

94117

**DATE**

11/25/21