

**PATIENT**

Josie Tryhorn

**SPECIES**

Canine

**BREED**

Doberman Cross

**SEX**

Spayed female

**AGE**

12 years

**WEIGHT**

55 lbs

**INTERPRETED BY**

Eric Lindquist, DMV,  
 DABVP, Cert. IVUSS,  
 CEO of SonoPath.com

**IMAGING PERFORMED BY**

Kelly Reschny

**HOSPITAL NAME**

Maples AH

**REFERRING VET**

Dr. Kazienko

**INVOICE**

68085

**DATE**

10/28/25

**PRESENTING CLINICAL SIGNS**

History: Lump(suspected lipoma) medial upper thigh noticed Feb 2025. Has been growing continuously for past few months. Skin is tight. Josie is showing some favoring of her LH leg as it is a little awkward to walk. Current Medications Hepato Support

**ULTRASONOGRAPHIC EXAMINATION**

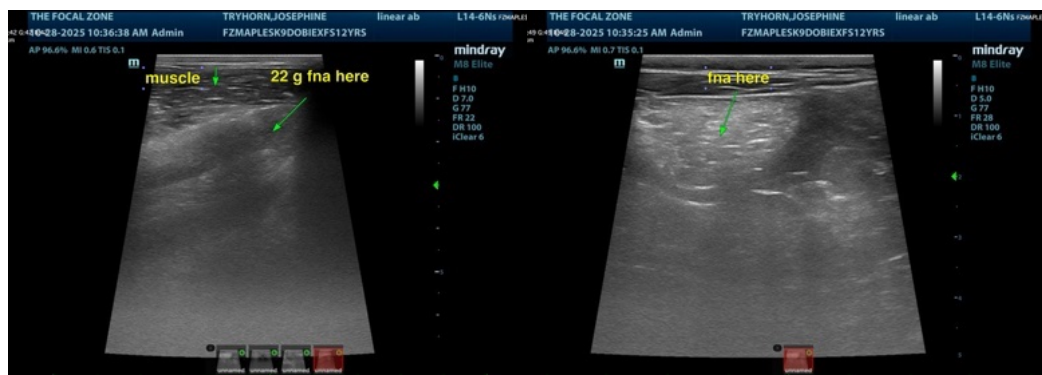The lipomatous mass noted on the prior sonogram approximately a year ago appears to have disorganized and appears to be infiltrating between the muscle bellies in the region of the upper left thigh and also compresses regional vasculature such as the femoral artery.

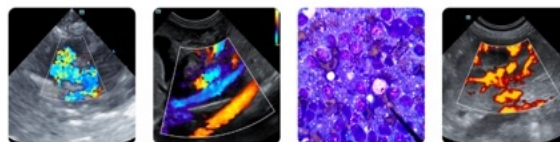
**ULTRASONOGRAPHIC FINDINGS**

Lipomatous mass appears to be infiltrating the muscle bellies.

**INTERPRETATION OF THE FINDINGS & FURTHER RECOMMENDATIONS**

Ultrasound-guided FNA of the various areas indicated in the images attached is recommended to assess for persistent lipoma versus potential liposarcoma. This is not a cleanly resectable presentation. Debulking effort can be considered or limb amputation may be necessary in this patient. 22-gauge FNA is likely best for optimal recovery. No significant inflammation was noted and no fluid pockets were evident.





**PATIENT**

Josie Tryhorn

**SPECIES**

Canine

**BREED**

Doberman Cross

**SEX**

Spayed female

**AGE**

12 years

**WEIGHT**

55 lbs

**INTERPRETED BY**

Eric Lindquist, DMV,  
DABVP, Cert. IVUSS,  
CEO of SonoPath.com

**IMAGING PERFORMED BY**

Kelly Reschny

**HOSPITAL NAME**

Maples AH

**REFERRING VET**

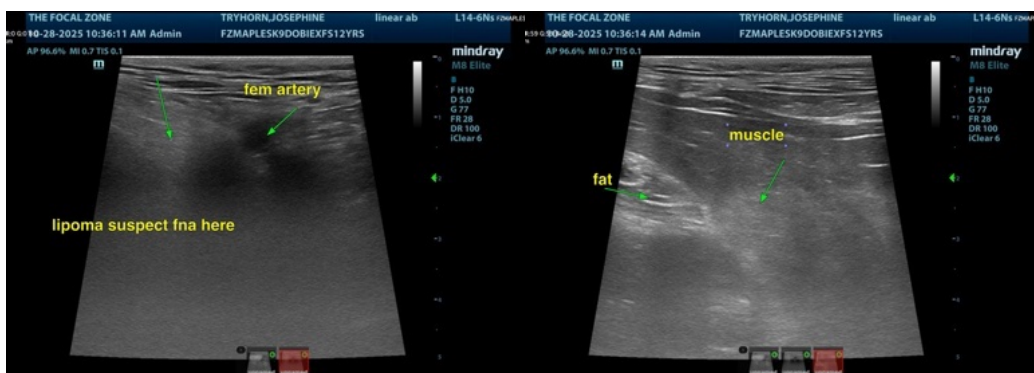Dr. Kazienko

**INVOICE**

68085

**DATE**

10/28/25



The information and recommendations provided are based on the images presented by the referring veterinarian/sonographer. No evaluation can be communicated regarding pathology that was not visible in the image/video clips provided.

Thank you for this referral. If the clinical or image interpretation does not parallel your findings or if I can be of any further assistance please contact me.

Eric Lindquist, DMV, DABVP, Cert. IVUSS, CEO of SonoPath.com

[info@SonoPath.com](mailto:info@SonoPath.com)