

PATIENT PRESENTING CLINICAL SIGNS

Mercy Murre History: Ultrasound request to confirm viable pregnancy. Tied on Sept 13th and 15th.

SPECIES ULTRASONOGRAPHIC EXAMINATION

Canine Positive pregnancy was noted in this patient. The fetuses from head to tail measured approximately 3.0 cm. Viable heartbeats were noted. The amniotic sac presented anechoic fluid. The fetal sac appeared to be unremarkable. There are at least 4 live fetuses; however, fetal count is best assessed radiographically. The uterus appeared healthy with normal curvilinear patterns without fluid filled lumen. The patient is approximately at 3-4 weeks of gestation.

BREED ULTRASONOGRAPHIC FINDINGS

Morkie Positive pregnancy.

SEX

Intact female

AGE

2 ½ years

INTERPRETATION OF THE FINDINGS & FURTHER RECOMMENDATIONS

There are at least 4 live fetuses. A more accurate count would require radiographs.

WEIGHT

3 kg

INTERPRETED BY

Eric Lindquist, DMV
DABVP, Cert. IVUSS

IMAGING PERFORMED BY

Crystal Hill, RVT

HOSPITAL NAME

Hillview VC

REFERRING VET

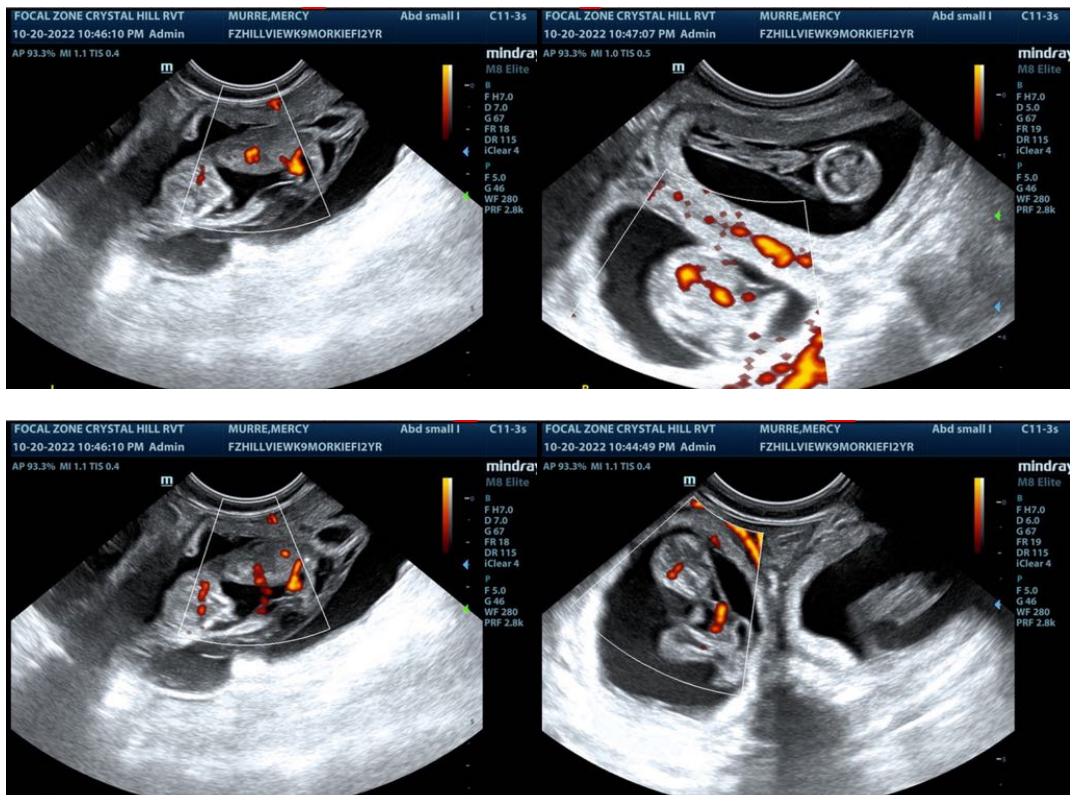
Dr. Stevenson

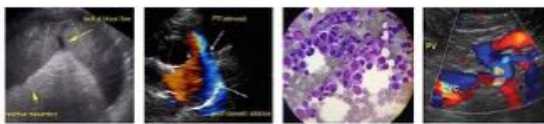
INVOICE

40202

DATE

110/20/22





PATIENT

Mercy Murre

SPECIES

Canine

BREED

Morkie

SEX

Intact female

AGE

2 ½ years

WEIGHT

3 kg

INTERPRETED BY

Eric Lindquist, DMV
DABVP, Cert. IVUSS

**IMAGING
PERFORMED BY**

Crystal Hill, RVT

HOSPITAL NAME

Hillview VC

REFERRING VET

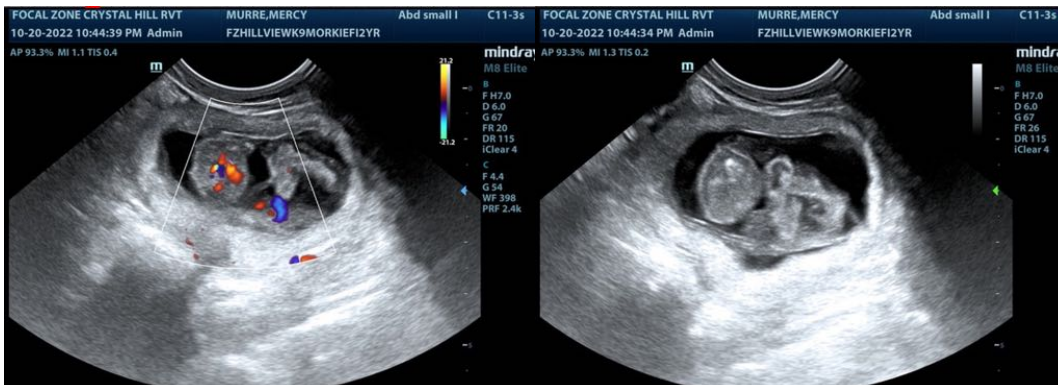
Dr. Stevenson

INVOICE

40202

DATE

110/20/22



The information and recommendations provided are based on the images presented by the referring veterinarian/sonographer. No evaluation can be communicated regarding pathology that was not visible in the image/video clips provided.

Thank you for this referral. If the clinical or image interpretation does not parallel your findings or if I can be of any further assistance please contact me.

Eric Lindquist, DMV, DABVP, Cert. IVUSS, CEO of SonoPath.com
Eric.Lindquist@SonoPath.com