



PATIENT

Lily Bradley

SPECIES

Feline

BREED

Domestic Shorthair

SEX

Spayed Female

AGE

2 years

WEIGHT

4.6 kg

INTERPRETED BY

Eric Lindquist, DMV
DABVP, Cert. IVUSS

**IMAGING
PERFORMED BY**

Kelly Reshny, RVT

HOSPITAL NAME

Downtown AH

REFERRING VET

Dr. Ahn

INVOICE

40146

DATE

10/19/22

PRESENTING CLINICAL SIGNS

History: Hx of recurring hematuria and frequenturia, had ammonium biurate bladder stones. during cystotomy, she didn't not recover fully from midazolam and diazepam over 24 hours currently her PE is unremarkable. concern for microhepatica or shunt

Abnormal PE/Chem/CBC/UA Results: rads: bladder stones seen, chest normal please see attached labs

ULTRASONOGRAPHIC EXAMINATION OF THE ABDOMEN

Urinary System

The **urinary bladder** presented a small amount of sand and calculi. Minor bladder wall thickening was noted measuring 0.5 cm at mild repletion.

The **kidneys** revealed normal size and structure, corticomedullary definition and ratio for this age. The cortices presented largely uniform texture with normal echogenic relationship to liver and spleen.

Medullary structure differed distinctly from the cortex and no evidence of pelvic dilation was present. The capsules were acceptably uniform without significant irregularities. The left kidney measured 4.08 cm. The right kidney measured 4.06 cm.

Adrenal Glands

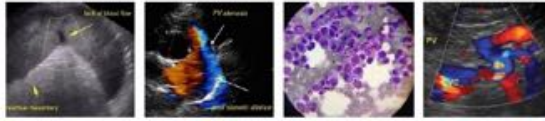
Both **adrenal glands** were visualized and recognized as having normal shape, size, position and echogenicity for this breed. The phrenic vasculature, glandular echogenicity and detail were unremarkable. Capsule, cortex, and medullary definition were normal for this age patient. The left adrenal gland measured 0.53 cm. The right adrenal gland measured 0.22 cm.

Spleen

The **spleen** presented a smooth homogeneous parenchyma hyperechoic to liver and renal cortical parenchyma. The capsule was smooth without noticeable expansion or deviation from within the spleen or adjacent pathology. The splenic vasculature demonstrated normal volume without signs of congestion or thrombosis. No sonographic evidence of acute or chronic inflammatory, neoplastic, or infarctual changes was noted.

Liver

The **liver** images submitted revealed subjectively normal liver size, contour, and structure. Parenchymal echogenicity was naturally coarse and hypoechoic to the spleen. The vena cava to aortic ratio was 1:1 measuring 0.5 cm each. The portal vein measured 0.4 cm. There was no obvious extrahepatic or intrahepatic shunts noted; however, given the patient's history portal hypoplasia/microvascular dysplasia may be an issue. The region of double aorta or azygos shunting was also imaged with no evidence of pathology. The gallbladder presented acceptably thin walls with primarily anechoic content. The cystic and common bile ducts were normal. No pathological hepatic lymphadenopathy was evident. No overt structural evidence of inflammatory, infiltrative or regenerative pathology was evident.



PATIENT

Gastrointestinal

Lily Bradley

Minor soft ingesta was noted in the **stomach**. The small intestines and colon were unremarkable.

SPECIES

Pancreas

Feline

The base and limbs of the **pancreas** were observed to be largely isoechoic to surrounding omental fat. Pancreatic duct and capsular contour were acceptably normal and parenchyma respected normal curvilinear patterns. No overt evidence of active inflammatory or neoplastic disease was noted.

BREED

Domestic Shorthair

ULTRASONOGRAPHIC FINDINGS

SEX

Spayed Female

No obvious portosystemic shunting, possible portal hypoplasia/microvascular dysplasia. This would necessitate liver biopsy for further definition.

AGE

2 years

INTERPRETATION OF THE FINDINGS & FURTHER RECOMMENDATIONS

WEIGHT

4.6 kg

CT evaluation can be considered for further elimination of potential shunting, yet no obvious shunting was noted in the typical areas for extrahepatic or intrahepatic shunt was noted. An alternative option would be to perform cystostomy and liver biopsy at that time. Utilization of Propofol and Isoflurane for sedation and anesthesia would allow for bypass of liver metabolism, which may be a better option for this particular patient. Bile acid profile is indicated.

INTERPRETED BY

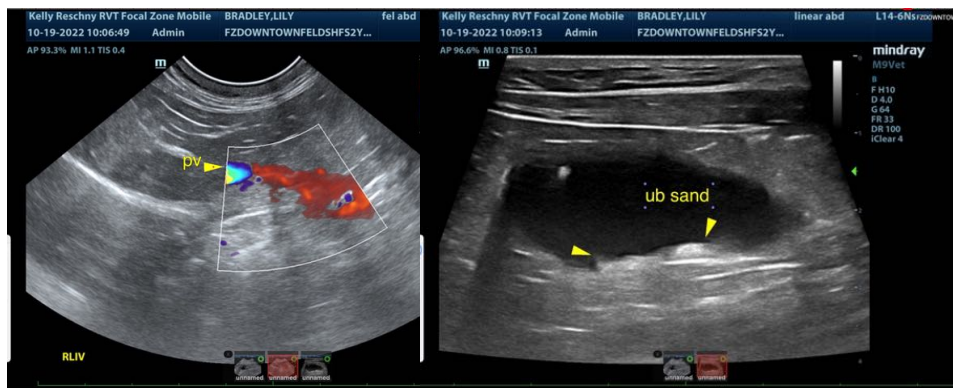
Eric Lindquist, DMV
DABVP, Cert. IVUSS

IMAGING PERFORMED BY

Kelly Reshny, RVT

HOSPITAL NAME

Downtown AH



REFERRING VET

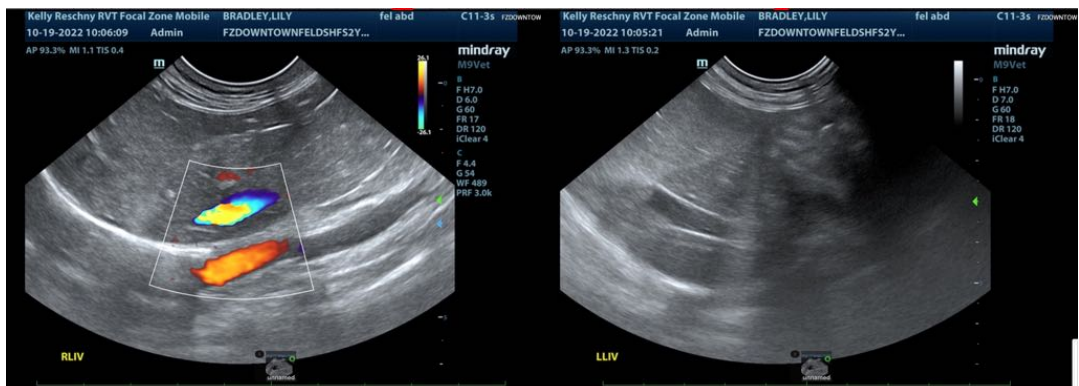
Dr. Ahn

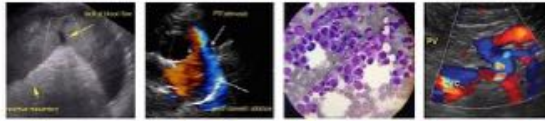
INVOICE

40146

DATE

10/19/22





PATIENT

Lily Bradley

SPECIES

Feline

BREED

Domestic Shorthair

SEX

Spayed Female

AGE

2 years

WEIGHT

4.6 kg

INTERPRETED BY

Eric Lindquist, DMV
DABVP, Cert. IVUSS

**IMAGING
PERFORMED BY**

Kelly Reshny, RVT

HOSPITAL NAME

Downtown AH

REFERRING VET

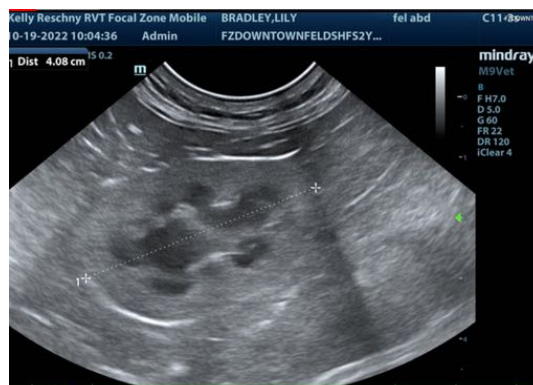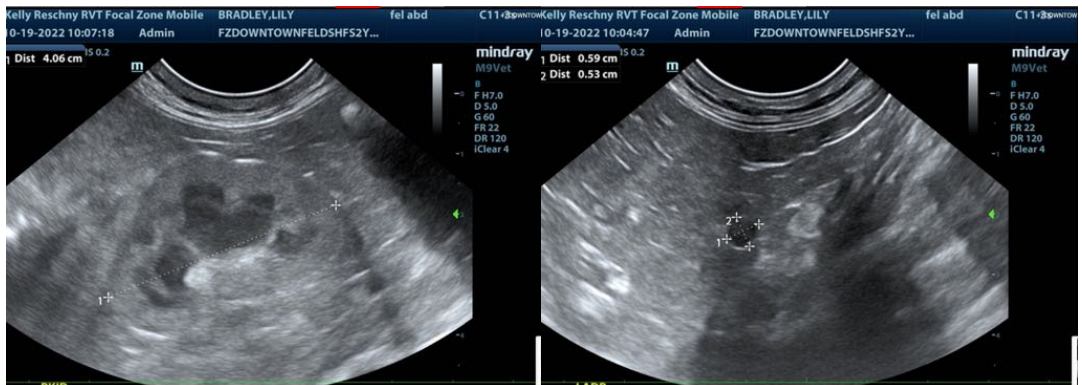
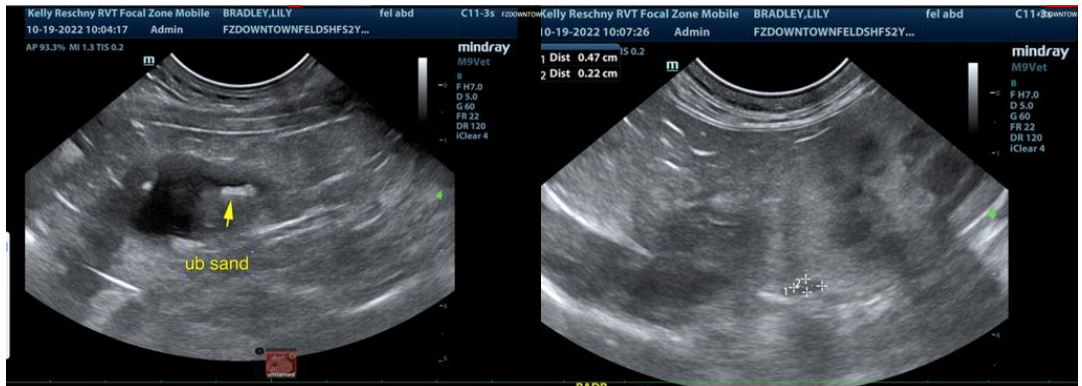
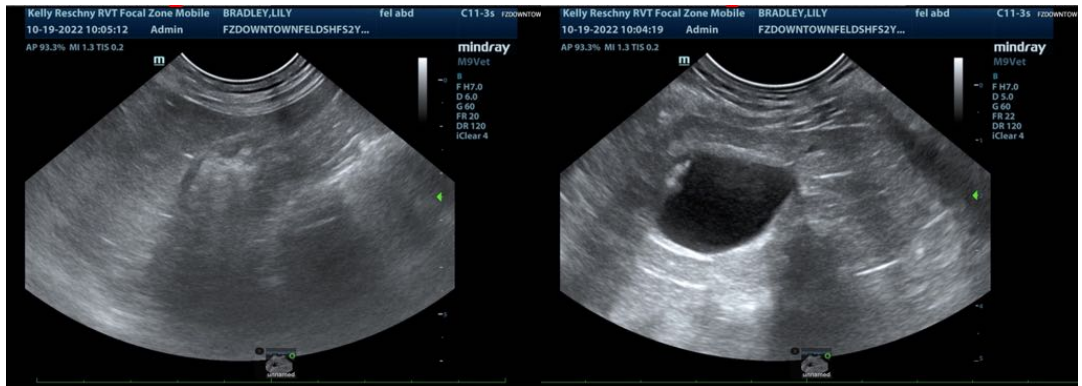
Dr. Ahn

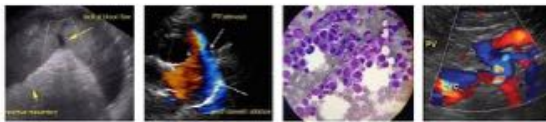
INVOICE

40146

DATE

10/19/22





PATIENT

Lily Bradley

The information and recommendations provided are based on the images presented by the referring veterinarian/sonographer. No evaluation can be communicated regarding pathology that was not visible in the image/video clips provided.

SPECIES

Feline

Thank you for this referral. If the clinical or image interpretation does not parallel your findings or if I can be of any further assistance please contact me.

BREED

Domestic Shorthair

Eric Lindquist, DMV, DABVP, Cert. IVUSS, CEO of SonoPath.com
Eric.Lindquist@SonoPath.com

SEX

Spayed Female

AGE

2 years

WEIGHT

4.6 kg

INTERPRETED BY

Eric Lindquist, DMV
DABVP, Cert. IVUSS

**IMAGING
PERFORMED BY**

Kelly Reshny, RVT

HOSPITAL NAME

Downtown AH

REFERRING VET

Dr. Ahn

INVOICE

40146

DATE

10/19/22