

PATIENT

Luna Saeedi

SPECIES

Feline

BREED

Domestic Shorthair

SEX

Intact female

AGE

9 months

WEIGHT

3.57 kg

PRESENTING CLINICAL SIGNS

History: preg check, found as a stray,

ULTRASONOGRAPHIC EXAMINATION

The left ovary was uniform and measured 0.4 cm. The right ovary was uniform and measured 0.53 cm. The uterus was thickened in this patient measuring up to 1.5 cm with variable swelling consistent with resorbing fetuses. Some echogenic luminal material was noted. This would not be typical of pregnancy given the echogenic fluid filled lumen.

ULTRASONOGRAPHIC FINDINGS

- Pyometra pattern with likely resorbing fetuses.

INTERPRETATION OF THE FINDINGS & FURTHER RECOMMENDATIONS

Ovariohysterectomy is recommended.

INTERPRETED BY

Eric Lindquist, DMV,
 DABVP, Cert. IVUSS,
 CEO of SonoPath.com

IMAGING PERFORMED BY

Kelly Reschny

HOSPITAL NAME

Vet for Life AH

REFERRING VET

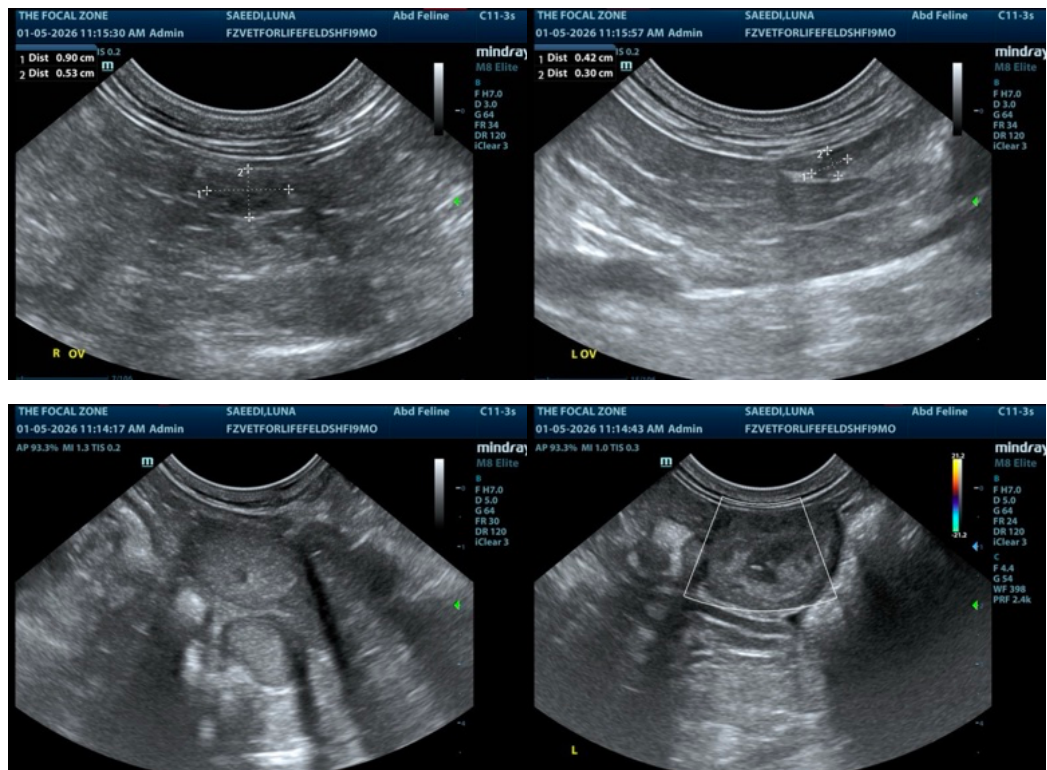
Dr. Bajaj

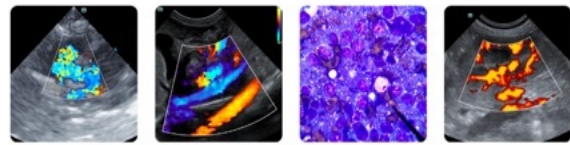
INVOICE

69792

DATE

1/5/26





PATIENT

Luna Saeedi

SPECIES

Feline

BREED

Domestic Shorthair

SEX

Intact female

AGE

9 months

WEIGHT

3.57 kg

INTERPRETED BY

Eric Lindquist, DMV,
DABVP, Cert. IVUSS,
CEO of SonoPath.com

IMAGING PERFORMED BY

Kelly Reschny

HOSPITAL NAME

Vet for Life AH

REFERRING VET

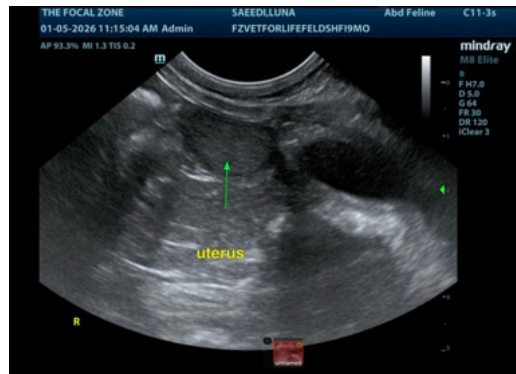
Dr. Bajaj

INVOICE

69792

DATE

1/5/26



The information and recommendations provided are based on the images presented by the referring veterinarian/sonographer. No evaluation can be communicated regarding pathology that was not visible in the image/video clips provided.

Thank you for this referral. If the clinical or image interpretation does not parallel your findings or if I can be of any further assistance please contact me.

Eric Lindquist, DMV, DABVP, Cert. IVUSS, CEO of SonoPath.com

info@SonoPath.com