



PATIENT PRESENTING CLINICAL SIGNS

Blue Duif Davis

Intermittent heart murmur noted during puppy vaccine series (not heard at 8 and 16 weeks, heard at 12 weeks and 5 months). At last visit 1/13/21: grade 2/6 heart murmur, PMI left systolic, soft, focal, possible irregular arrhythmia (vs. sinus arrhythmia). Murmur gets quieter as heart rate increases. No clinical signs associated with murmur. Client plans to compete in agility with patient.
Abnormal PE/Chem/CBC/UA Results: BP 93/36 MAP 54 91/39 MAP 58

SPECIES

Canine

BREED

Cairn Terrier

SEX

Intact male

AGE

6 months

WEIGHT

5.43 kg

ULTRASONOGRAPHIC EXAMINATION OF THE HEART

The echocardiogram in this patient demonstrated normal **left atrial** size based on 3 separate methods of LA evaluation. The **mitral** valve was thickened in this patient with a stiff, hypokinetic free wall leaflet. Concentric left ventricular hypertrophy was noted. The posterior leaflet was tethered and shortened. The **myocardium** presented normal echogenicity without subjective evidence of significant fibrotic or ischemic disease. **Contractility** of the ventricular walls was adequate and in normal range for this patient evidenced by the fractional shortening measurement and subjective evaluation of the different regions of the myocardium. The **left ventricular outflow** tract demonstrated normal laminar flow and subjective structural integrity. The **right atrium** and auricle revealed normal size, structure and content. No evidence of masses was noted. Trivial **tricuspid** insufficiency was noted at 1.3. The **right ventricle** was of normal size (1/3 diameter of LV), chordae structure, myocardial echogenicity and thickness. Trivial **pulmonic** insufficiency was noted. No visible **pericardial** or free pleura fluid was noted. The cranial **mediastinum and pericardial and extra-cardiac regions** were free of masses in the visible window.

INTERPRETED BY

Eric Lindquist, DMV
DABVP, Cert. IVUSS

IMAGING PERFORMED BY

Kelly Reshny, RVT

HOSPITAL NAME

Graham AH

REFERRING VET

Dr. Lukacs

CANINE CARDIAC PARAMETERS	MR VMAX (m/s)	TR VMAX (m/s)	LA/AO (Boon method)	LA/AO (Heart Base; Swe)	FS (%)	EF (%)	EPSS (cm)
NORMAL PARAMETER	4.5-5.5	<2.7	1.3	<1.6	28-40	40-100	<0.6
PATIENT	5.0	1.3	1.1	1.25	50	85	0.1
CANINE CARDIAC PARAMETERS	HR (BPM)	AV VMAX (m/s)	PV MAX (m/s)	BODY WEIGHT (kg)	LA (2D short axis Base view) (cm)	LVIDd (Avg; 2D and m-mode short axis) (cm)	LVIDs (Avg; 2D and m-mode short axis) (cm)
NORMAL PARAMETER	50-100	0.7-1.7	0.7-1.6				
PATIENT	160	2.2	1.47	5.43 kg	2.39 max	1.8	

INVOICE

95651

DATE

1/31/22



PATIENT

Blue Duif Davis

SPECIES

Canine

BREED

Cairn Terrier

SEX

Intact male

AGE

6 months

WEIGHT

5.43 kg

INTERPRETED BY

Eric Lindquist, DMV
DABVP, Cert. IVUSS

**IMAGING
PERFORMED BY**

Kelly Reshny, RVT

HOSPITAL NAME

Graham AH

REFERRING VET

Dr. Lukacs

INVOICE

95651

DATE

1/31/22

ULTRASONOGRAPHIC FINDINGS

Mitral valve dysplasia, minor.

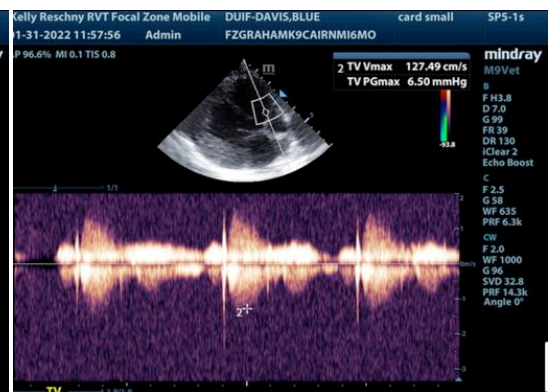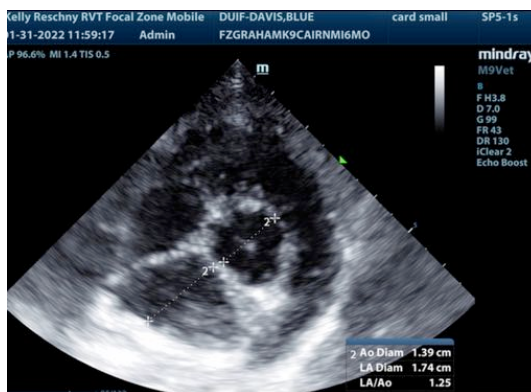
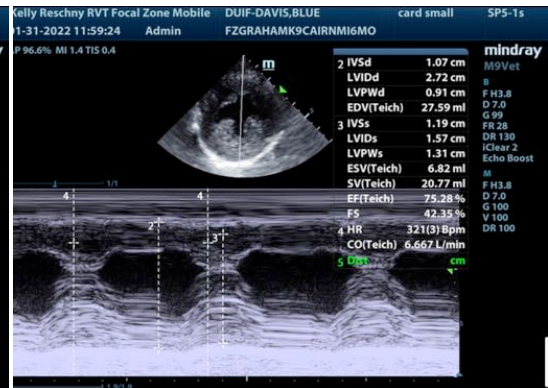
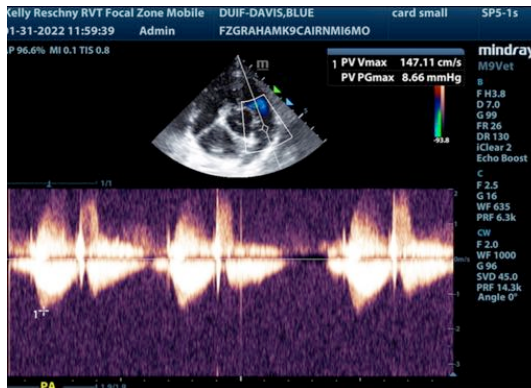
Concentric left ventricular hypertrophy, likely compensatory or possible mild form of hypertrophic cardiomyopathy.

Slightly increased left ventricular outflow velocity, likely compensatory.

No volume overload at this time.

INTERPRETATION OF THE FINDINGS & FURTHER RECOMMENDATIONS

The clinical outcome of this type of presentation is debatable and would be best assessed at a full year of age. No treatment is recommended at this time. There is no overt contraindication to anesthetic procedure if necessary. Stress test is recommended to assess for exercise intolerance should be considered in this patient. At the current time I do not feel that there is any contraindication to agility training; however, this may be an issue going forward as the patient grows into full adulthood. Follow-up echocardiogram is recommended in 3-6 months or earlier if any clinical signs initiate.





PATIENT

Blue Duif Davis

SPECIES

Canine

BREED

Cairn Terrier

SEX

Intact male

AGE

6 months

WEIGHT

5.43 kg

INTERPRETED BY

Eric Lindquist, DMV
DABVP, Cert. IVUS

**IMAGING
PERFORMED BY**

Kelly Reshny, RVT

HOSPITAL NAME

Graham AH

REFERRING VET

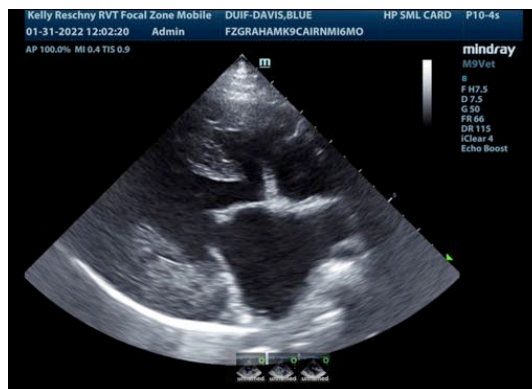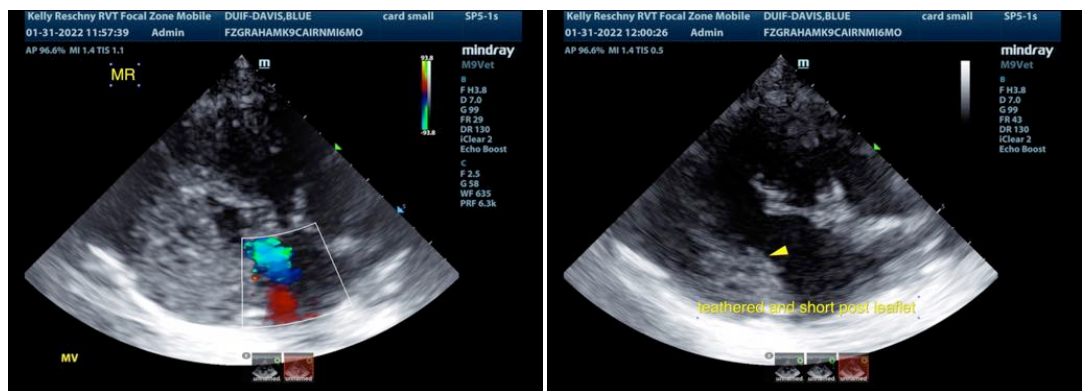
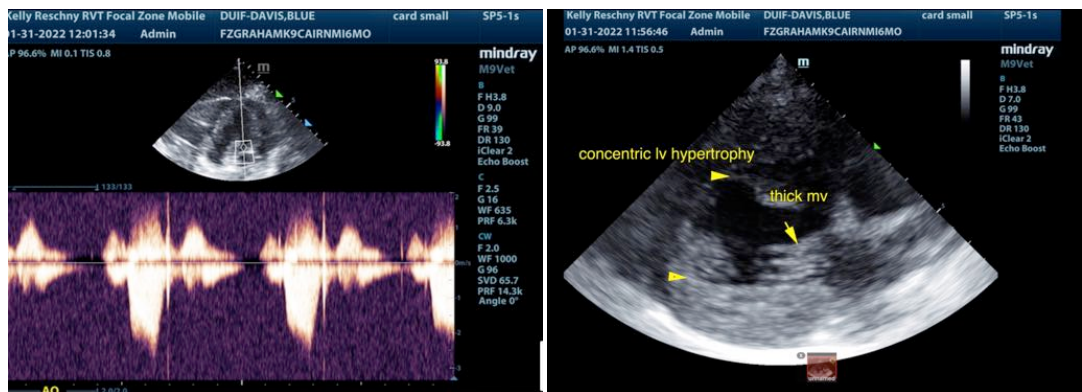
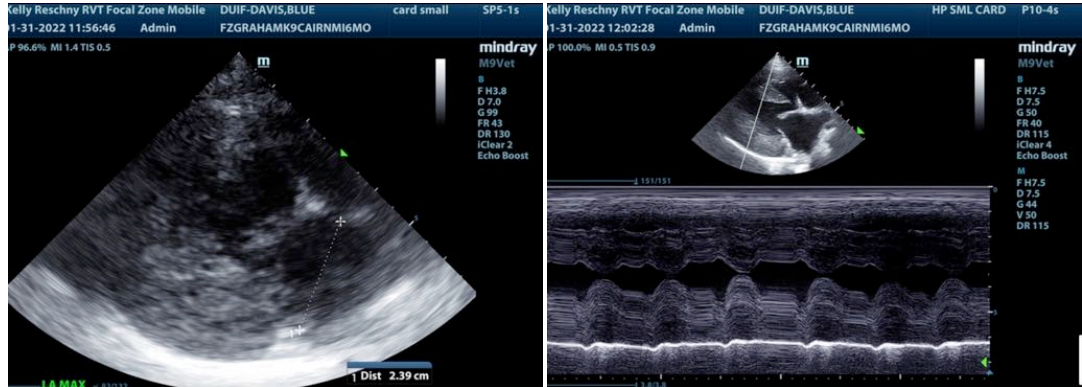
Dr. Lukacs

INVOICE

95651

DATE

1/31/22





PATIENT

Blue Duif Davis

The information and recommendations provided are based on the images presented by the referring veterinarian/sonographer. No evaluation can be communicated regarding pathology that was not visible in the image/video clips provided.

SPECIES

Canine

Thank you for this referral. If the clinical or image interpretation does not parallel your findings or if I can be of any further assistance please contact me.

BREED

Cairn Terrier

Eric Lindquist, DMV, DABVP, Cert. IVUSS, CEO of SonoPath.com
Eric.Lindquist@SonoPath.com

SEX

Intact male

AGE

6 months

WEIGHT

5.43 kg

INTERPRETED BY

Eric Lindquist, DMV
DABVP, Cert. IVUSS

**IMAGING
PERFORMED BY**

Kelly Reshny, RVT

HOSPITAL NAME

Graham AH

REFERRING VET

Dr. Lukacs

INVOICE

95651

DATE

1/31/22