



PATIENT PRESENTING CLINICAL SIGNS

Kitty Ferris Wheezing, loud breathing sound x-rays showed possible pulmonary edema but due to cost concerns, treated with the course of doxycycline and furosemide meds: furosemide 5mg BID
Abnormal PE/Chem/CBC/UA Results: HR 180 RR 42

SPECIES

Feline

BREED

Domestic Longhair

SEX

Spayed Female

AGE

7 years

WEIGHT

8.1 kg

ULTRASONOGRAPHIC EXAMINATION OF THE HEART

The echocardiogram in this patient demonstrated normal **left atrial** size based on 3 separate LA measurements. The cranial and caudal **mitral** valve leaflets presented normal linear structure and kinetics. The **left ventricle** presented normal thicknesses with linear contour and was not dilated nor restricted. The **myocardium** presented normal echogenicity without subjective evidence of significant fibrotic or ischemic disease. **Contractility** of the ventricular walls was adequate and in normal range for this patient evidenced by the fractional shortening measurement and subjective evaluation of the different regions and angles of the myocardium. The **left ventricular outflow** tract demonstrated normal laminar flow and subjective structural integrity. The **right atrium** and auricle revealed normal size, structure and content. No evidence of masses was noted or chamber overload. **Tricuspid** valvular assessment demonstrated adequate linear morphology and kinetics. The **right ventricle** was of normal size (1/3 diameter of LV), chordae structure, myocardial echogenicity and thickness. **Pulmonic** tract assessment revealed normal valve structure, laminar flow, and diameter (approx. 1:1 pa/ao ratio). No visible **pericardial** or free pleura fluid was noted or extra cardiac pathology in the visible planes. The cranial **mediastinum and pericardial regions** were free of masses in the visible window. A large amount of thoracic fat was noted in this patient.

INTERPRETED BY

Eric Lindquist, DMV
DABVP, Cert. IVUSS

IMAGING PERFORMED BY

Kelly Reshny, RVT

HOSPITAL NAME

Downtown AH

REFERRING VET

Dr. Ahn

INVOICE

95602

DATE

1/28/22

FELINE CARDIAC PARAMETERS	BODY WEIGHT (kg)	HR (BPM)	IVSd (cm)	LVIDd (cm)	LVWd (cm)	FS (%)	EF (%)
NORMAL PARAMETER	-----	150-240	0.3-0.6	1.0-2.1	0.25-0.6	35-67	80-100
PATIENT		NM	0.65	0.86	0.58	33	65
FELINE CARDIAC PARAMETERS	LA/AO (Boon)	LA/AO HEART BASE (Sisson)	LA 2D 4-chamber long axis AS to FW (Sisson) (cm)		LVOT VEL. (m/s)	RVOT VEL. (m/s)	IVRT (m/)
NORMAL PARAMETER	<1.5	0.88-1.79	0.7-1.7		<1.6	<1.3	40-60
PATIENT		1.19			1.0	0.83	NM
Adapted from June Boon, Veterinary Echocardiography, 1998 Sisson D et al. JVIM 1991; 5: 232, Jacobs et al. Am J Vet Res 1985; 46:1705							



PATIENT

ULTRASONOGRAPHIC FINDINGS

Kitty Ferris

Essentially normal echocardiogram with a large amount of extracardiac thoracic fat.

No evidence of primary cardiac disease.

SPECIES

Feline

INTERPRETATION OF THE FINDINGS & FURTHER RECOMMENDATIONS

BREED

Domestic Longhair

SEX

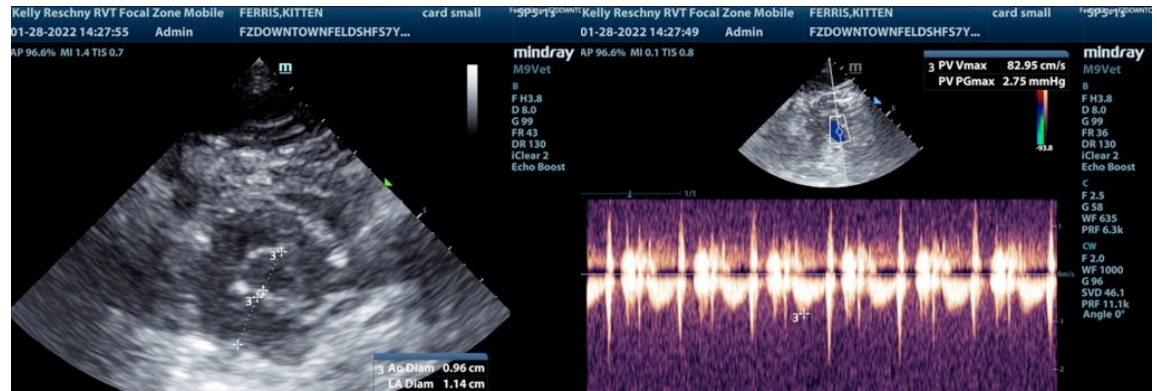
Spayed Female

AGE

7 years

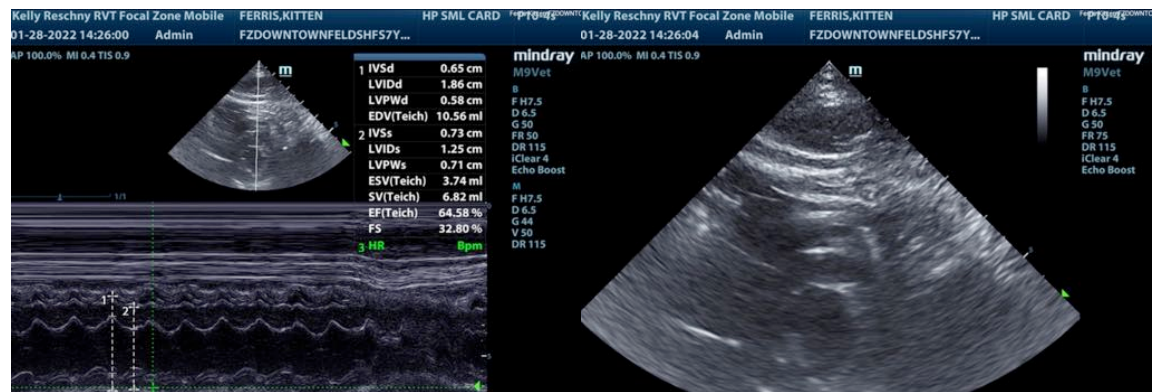WEIGHT

8.1 kg



INTERPRETED BY

Eric Lindquist, DMV
DABVP, Cert. IVUS



IMAGING PERFORMED BY

Kelly Reshny, RVT

HOSPITAL NAME

Downtown AH

REFERRING VET

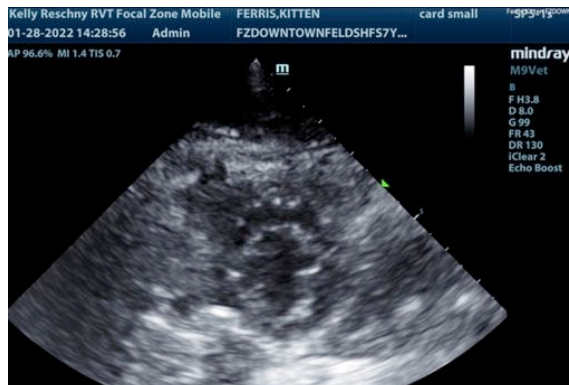Dr. Ahn

INVOICE

95602

DATE

1/28/22





PATIENT

Kitty Ferris

The information and recommendations provided are based on the images presented by the referring veterinarian/sonographer. No evaluation can be communicated regarding pathology that was not visible in the image/video clips provided.

SPECIES

Feline

Thank you for this referral. If the clinical or image interpretation does not parallel your findings or if I can be of any further assistance please contact me.

BREED

Domestic Longhair

Eric Lindquist, DMV, DABVP, Cert. IVUSS, CEO of SonoPath.com
Eric.Lindquist@SonoPath.com

SEX

Spayed Female

AGE

7 years

WEIGHT

8.1 kg

INTERPRETED BY

Eric Lindquist, DMV
DABVP, Cert. IVUSS

**IMAGING
PERFORMED BY**

Kelly Reshny, RVT

HOSPITAL NAME

Downtown AH

REFERRING VET

Dr. Ahn

INVOICE

95602

DATE

1/28/22