

PATIENT

Ebony Thompson

PRESENTING CLINICAL SIGNS

History: preg check, bred Dec 10-13

SPECIES

Canine

ULTRASONOGRAPHIC EXAMINATION

The uterine tract was imaged in this patient. At least 2 fetuses were visualized. However, superimposition of multiple fetuses is likely. From head to tail base they measured 5.5 cm. Amniotic fluid was anechoic. The fetal sacs were unremarkable with normal wall thickness. Normal fetal movement is present. Fetal count is highly variable on ultrasound given the superimposition. Approximately 3-5 fetuses are likely. There is no evidence of free fluid. Gestation is approximately 45 days.

BREED

Labrador

SEX

Intact female

ULTRASONOGRAPHIC FINDINGS

Normal viable pregnancy, approximately 35-40 days.

AGE

3 years

INTERPRETATION OF THE FINDINGS & FURTHER RECOMMENDATIONS

No therapy is recommended.

WEIGHT

28.7 kg

INTERPRETED BY

Eric Lindquist, DMV
DABVP, Cert. IVUSS

IMAGING PERFORMED BY

Kelly Reshny, RVT

HOSPITAL NAME

Simcoe AH

REFERRING VET

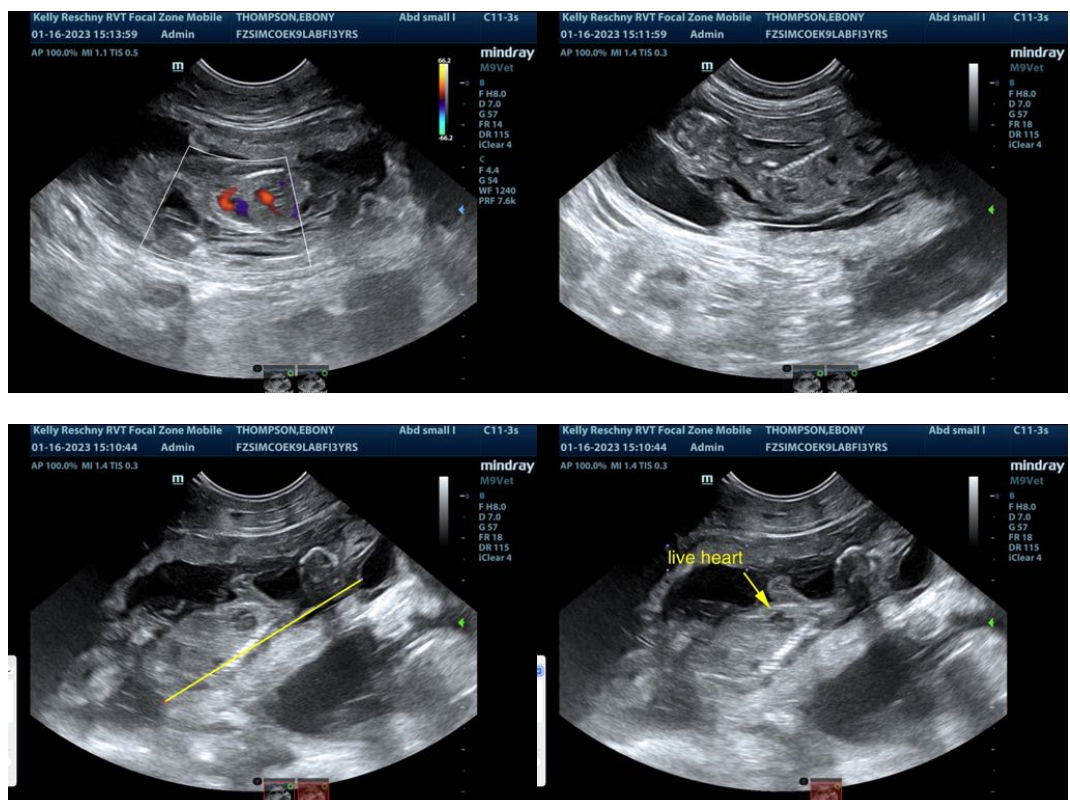
Dr. Lancashire

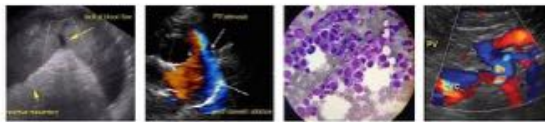
INVOICE

42144

DATE

1/16/23





PATIENT

Ebony Thompson

The information and recommendations provided are based on the images presented by the referring veterinarian/sonographer. No evaluation can be communicated regarding pathology that was not visible in the image/video clips provided.

SPECIES

Canine

Thank you for this referral. If the clinical or image interpretation does not parallel your findings or if I can be of any further assistance please contact me.

BREED

Labrador

Eric Lindquist, DMV, DABVP, Cert. IVUSS, CEO of SonoPath.com
Eric.Lindquist@SonoPath.com

SEX

Intact female

AGE

3 years

WEIGHT

28.7 kg

INTERPRETED BY

Eric Lindquist, DMV
DABVP, Cert. IVUSS

**IMAGING
PERFORMED BY**

Kelly Reshny, RVT

HOSPITAL NAME

Simcoe AH

REFERRING VET

Dr. Lancashire

INVOICE

42144

DATE

1/16/23