


**PATIENT PRESENTING CLINICAL SIGNS**

Paisley McCreary

High grade murmur found in a very young kitten brought in for vaccines, P appears to be clinically healthy otherwise

Abnormal PE/Chem/CBC/UA Results: HR 160, RR 40

**SPECIES**

Feline

**ULTRASONOGRAPHIC EXAMINATION OF THE HEART**
**BREED**

Persian

The echocardiogram in this patient demonstrated normal **left atrial** size based on 3 separate LA measurements. The cranial and caudal **mitral** valve leaflets presented normal linear structure and kinetics. The **ventricular** septum in this patient revealed a defect of approximately 0.23 cm. This is confirmed on color flow Doppler with left to right shunting. The **right atrium** and auricle revealed normal size, structure and content. No evidence of masses was noted or chamber overload. **Tricuspid** valvular assessment demonstrated adequate linear morphology and kinetics. The **right ventricle** was slightly enlarged with minor, right ventricular hypertrophy. **Pulmonary** artery was mildly dilated as well. However, there was no evidence of right-sided failure. No visible **pericardial** or free pleura fluid was noted or extra cardiac pathology in the visible planes. The cranial **mediastinum and pericardial regions** were free of masses in the visible window. VSD left to right was 5 m/sec.

**SEX**

Intact female

**AGE**

5 months

**WEIGHT**

1.44 kg

**INTERPRETED BY**

 Eric Lindquist, DMV  
 DABVP, Cert. IVUSS

**IMAGING PERFORMED BY**

Kelly Reshny, RVT

**HOSPITAL NAME**

Acton VC

**REFERRING VET**

Dr. Gajadhar

**INVOICE**

95218

**DATE**

1/13/22

FELINE CARDIAC PARAMETERS	BODY WEIGHT (kg)	HR (BPM)	IVSd (cm)	LVIDd (cm)	LVWd (cm)	FS (%)	EF (%)
NORMAL PARAMETER	-----	150-240	0.3-0.6	1.0-2.1	0.25-0.6	35-67	80-100
PATIENT		160	0.45	1.66	0.33	32	64
FELINE CARDIAC PARAMETERS	LA/AO (Boon)	LA/AO HEART BASE (Sisson)	LA 2D 4-chamber long axis AS to FW (Sisson) (cm)	LVOT VEL. (m/s)	RVOT VEL. (m/s)	IVRT (m/)	
NORMAL PARAMETER	<1.5	0.88-1.79	0.7-1.7	<1.6	<1.3	40-60	
PATIENT		1.7	1.3		1.6	NM	
Adapted from June Boon, Veterinary Echocardiography, 1998 Sisson D et al. JVIM 1991; 5: 232, Jacobs et al. Am J Vet Res 1985; 46:1705							

**ULTRASONOGRAPHIC FINDINGS**

Left to right ventricular septal defect with mild volume overload of the right heart and slight right ventricular hypertrophy.

**INTERPRETATION OF THE FINDINGS & FURTHER RECOMMENDATIONS**

At this time the patient is not likely having any clinical signs. However, a recheck sonogram is warranted at a year of age. There is no overt contraindication to anesthetic procedure if necessary. However, if the patient is to undergo ovariohysterectomy it should be done fairly soon prior to any progressive volume



**PATIENT**

Paisley McCreary

overload. The long term prognosis is guarded depending upon follow-up echocardiogram parameters at a full year of age. **Monitor and recheck at a year of age or earlier if any clinical signs such as exercise intolerance is recommended.**

**SPECIES**

Feline

**BREED**

Persian

**SEX**

Intact female

**AGE**

5 months

**WEIGHT**

1.44 kg

**INTERPRETED BY**

Eric Lindquist, DMV  
DABVP, Cert. IVUSS

**IMAGING  
PERFORMED BY**

Kelly Reshny, RVT

**HOSPITAL NAME**

Acton VC

**REFERRING VET**

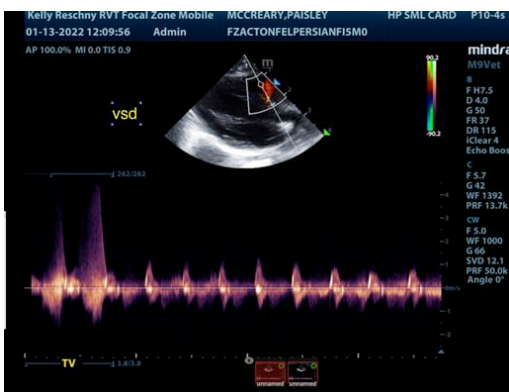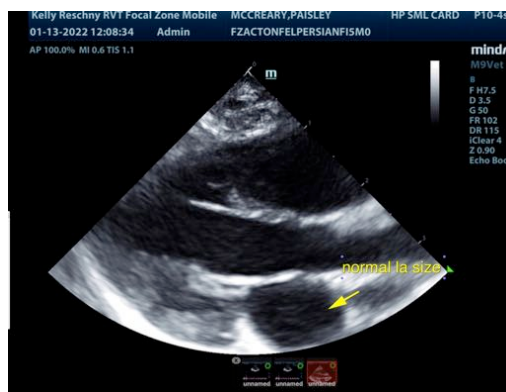
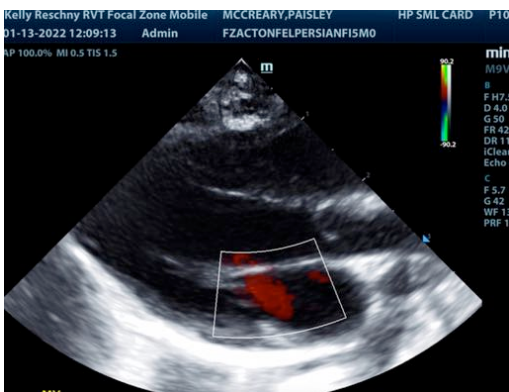
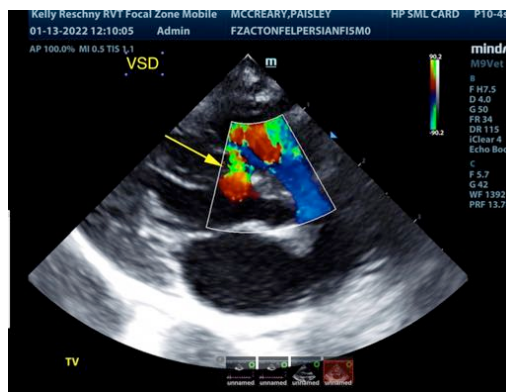
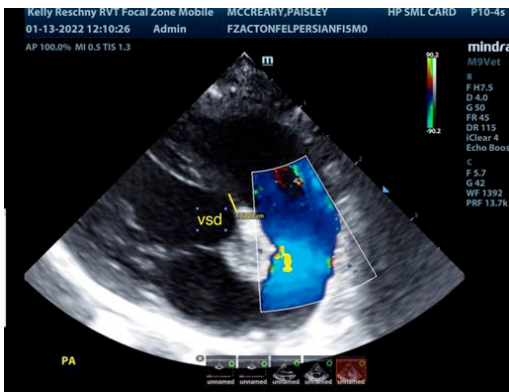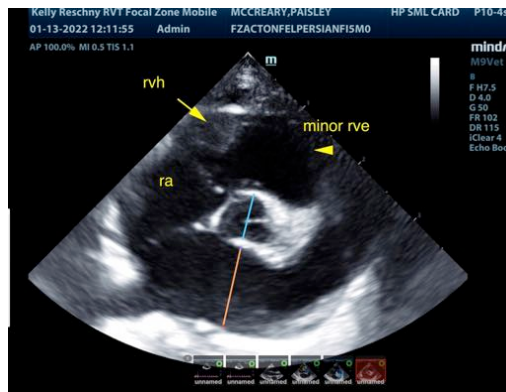
Dr. Gajadhar

**INVOICE**

95218

**DATE**

1/13/22





**PATIENT**

Paisley McCreary

**SPECIES**

Feline

**BREED**

Persian

**SEX**

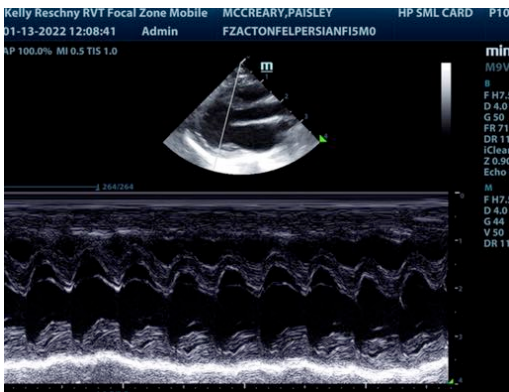
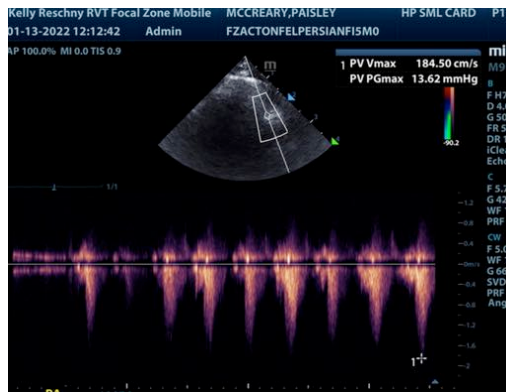
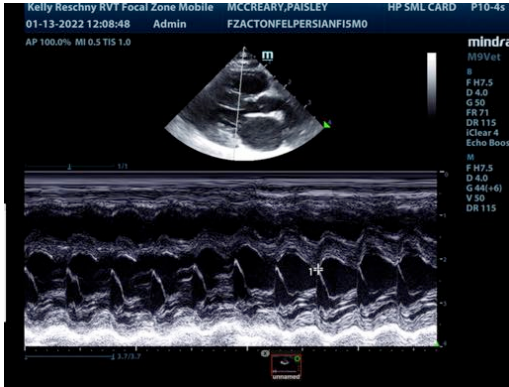
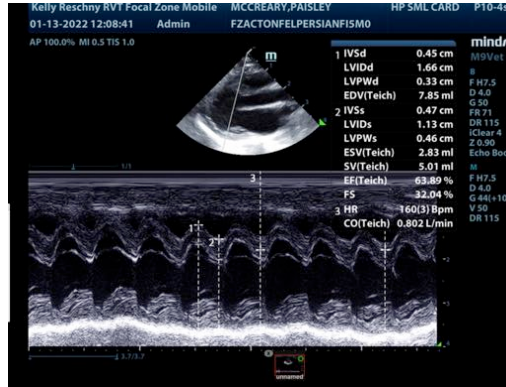
Intact female

**AGE**

5 months

**WEIGHT**

1.44 kg



**INTERPRETED BY**

Eric Lindquist, DMV  
DABVP, Cert. IVUSS

**IMAGING PERFORMED BY**

Kelly Reshny, RVT

**HOSPITAL NAME**

Acton VC

**REFERRING VET**

Dr. Gajadhar

**INVOICE**

95218

**DATE**

1/13/22

The information and recommendations provided are based on the images presented by the referring veterinarian. No evaluation can be communicated regarding pathology that was not visible in the image/video clips provided.

Thank you for this referral. If the clinical or image interpretation does not parallel your findings or if I can be of any further assistance please contact me.

Eric Lindquist, DMV, DABVP, Cert. IVUSS, CEO of SonoPath.com  
Eric.Lindquist@SonoPath.com