

PATIENT

Molly Jarrell

PRESENTING CLINICAL SIGNS

History: 2 cm lung mass R caudodorsal lung mass found on rads, history of cough

SPECIES

Canine

ULTRASONOGRAPHIC EXAMINATION OF THE ABDOMEN

Urinary System

The **urinary bladder**, trigone, and pelvic urethra presented normal thicknesses and normal tone. The ureters were not visible which is normal. No uroliths or sediment were visualized and anechoic urine was present. No evidence of inflammatory or neoplastic changes was noted. Ureteral papillae were normal.

BREED

Pitbull Mix

SEX

Spayed female

The **kidneys** revealed largely normal size and structure, corticomedullary definition and ratio (cortex 1/3 of medulla) were essentially maintained with some age-related loss of curvilinear patterns regarding the capsule and C/M junction. The cortices presented largely uniform texture with some increased echogenicity expected for his age patient. Medullary structure differed distinctly from that of the cortex and no evidence of pelvic dilation was present. The left kidney measured 5.67 cm. The right kidney measured 5.28 cm.

AGE

14 years

WEIGHT

65 lbs

Adrenal Glands

Both **adrenal glands** were visualized and recognized as having normal shape, size, position and echogenicity for this breed. The phrenic vasculature, glandular echogenicity and detail were unremarkable. Capsule, cortex, and medullary definition were normal for this age patient. The right adrenal gland measured 2.55 x 0.83 cm at the cranial pole and 0.72 cm at the caudal pole. The left adrenal gland measured 2.14 x 0.68 cm at the caudal pole and 0.53 cm at the cranial pole.

INTERPRETED BY

Eric Lindquist, DMV
DABVP, Cert. IVUSS

IMAGING PERFORMED BY

Carolina Veterinary
Mobile

Spleen

The **spleen** presented a smooth homogeneous parenchyma hyperechoic to liver and renal cortical parenchyma. The capsule was smooth without noticeable expansion or deviation from within the spleen or adjacent pathology. The splenic vasculature demonstrated normal volume without signs of congestion or thrombosis. No sonographic evidence of acute or chronic inflammatory, neoplastic, or infarctual changes was noted.

HOSPITAL NAME

Armstrong AC

Liver

REFERRING VET

Dr. Gallagher

The **liver** images from right and left intercostal as well as subcostal views revealed subjectively normal liver size, contour, and structure. Some age-related parenchymal remodeling was noted but likely not clinically significant at this time. Vascular and biliary tracts were of normal volume and no evidence of congestion was noted. The gallbladder presented some dependent debris with essentially normal contour. The cystic and common bile ducts were normal. No overt evidence of active inflammatory, infiltrative or regenerative pathology was noted but should be paired with current or past LE elevations regarding any clinical significance to this presentation. The hepatic lymph nodes were unremarkable.

INVOICE

46689

DATE

8/21/23



PATIENT

Molly Jarrell

SPECIES

Canine

BREED

Pitbull Mix

SEX

Spayed female

AGE

14 years

WEIGHT

65 lbs

INTERPRETED BY

Eric Lindquist, DMV
DABVP, Cert. IVUSS

IMAGING PERFORMED BY

Carolina Veterinary
Mobile

HOSPITAL NAME

Armstrong AC

REFERRING VET

Dr. Gallagher

INVOICE

46689

DATE

8/21/23

Gastrointestinal

Examination of the **gastrointestinal tract** revealed a stomach and intestine free of stasis, of normal wall thickness, acceptable curvilinear mural detail, and peristaltic activity. Small and large intestine demonstrated normal luminal chyme and stool consistency respectively. No obstructive or overt infiltrative disease was noted. No associated abnormal lymphatic activity was noted.

Pancreas

The base and limbs of the **pancreas** were observed to be largely isoechoic to surrounding omental fat. Pancreatic duct and capsular contour were acceptably normal and parenchyma respected normal curvilinear patterns. No overt evidence of active inflammatory or neoplastic disease was noted.

Free Abdomen

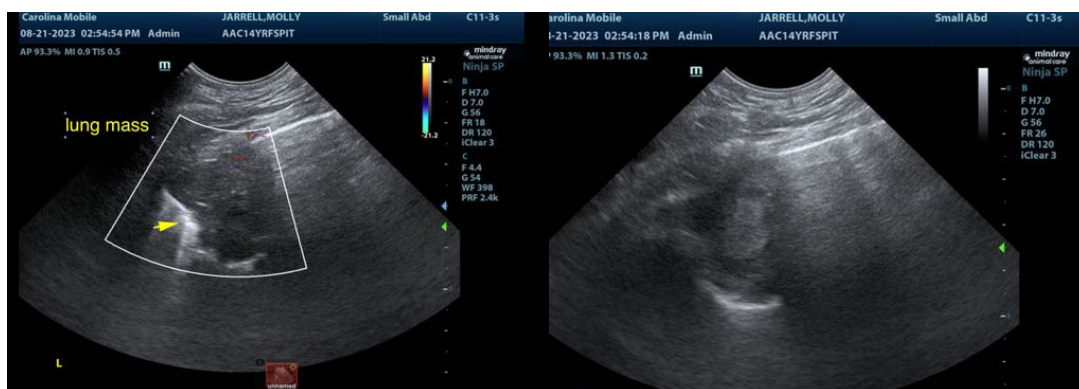
A 3.0 cm, mixed, hypoechoic lung mass was noted in this patient.

ULTRASONOGRAPHIC FINDINGS

Age related abdominal changes, no evidence of primary disease related to the lung mass.

INTERPRETATION OF THE FINDINGS & FURTHER RECOMMENDATIONS

Chest CT would be ideal to assess distribution of the lung mass. Differentials include carcinoma, granulomatous, non-neoplastic disease or less likely sarcoma. The mass is lung in origin given the peripheral air entrapment.





PATIENT

Molly Jarrell

SPECIES

Canine

BREED

Pitbull Mix

SEX

Spayed female

AGE

14 years

WEIGHT

65 lbs

INTERPRETED BY

Eric Lindquist, DMV
DABVP, Cert. IVUSS

IMAGING PERFORMED BY

Carolina Veterinary
Mobile

HOSPITAL NAME

Armstrong AC

REFERRING VET

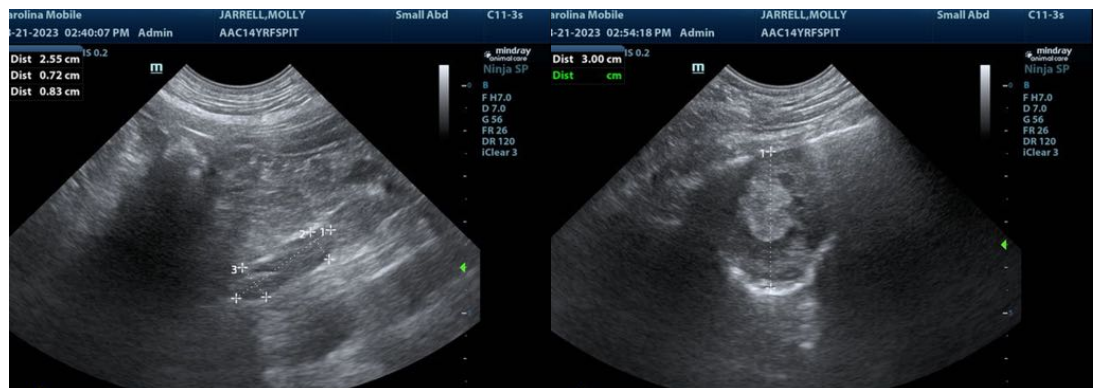
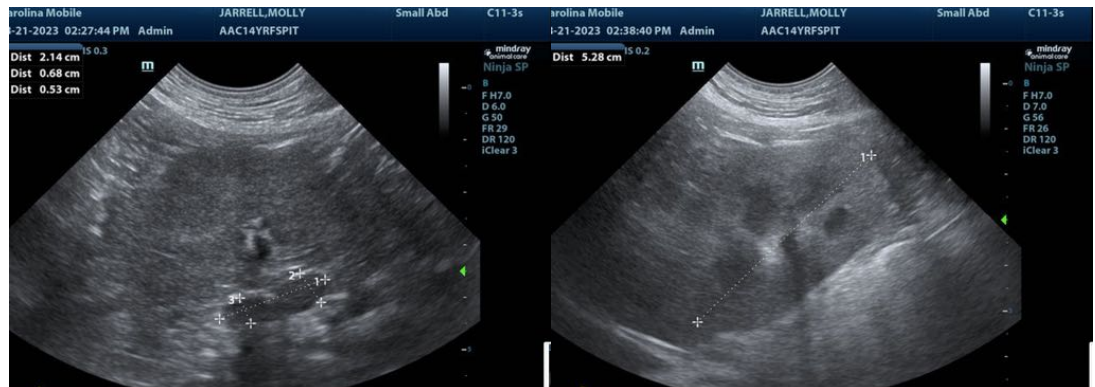
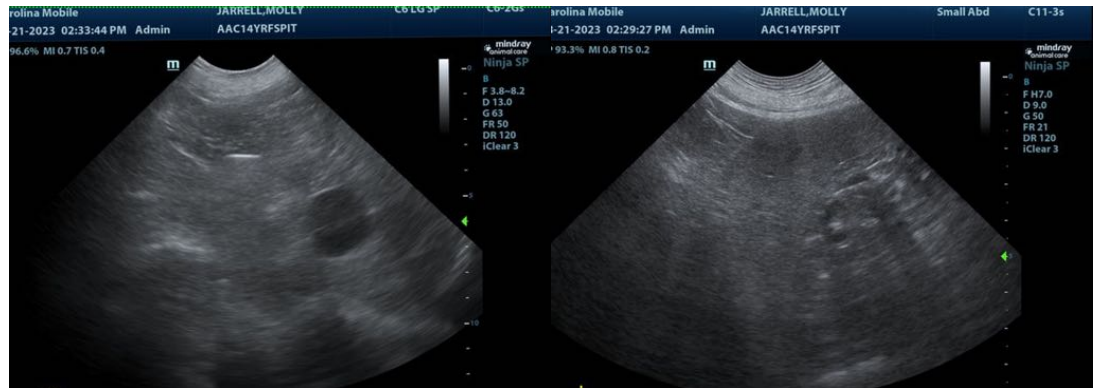Dr. Gallagher

INVOICE

46689

DATE

8/21/23





PATIENT

Molly Jarrell

SPECIES

Canine

BREED

Pitbull Mix

SEX

Spayed female

AGE

14 years

WEIGHT

65 lbs

INTERPRETED BY

Eric Lindquist, DMV
DABVP, Cert. IVUSS

**IMAGING
PERFORMED BY**

Carolina Veterinary
Mobile

HOSPITAL NAME

Armstrong AC

REFERRING VET

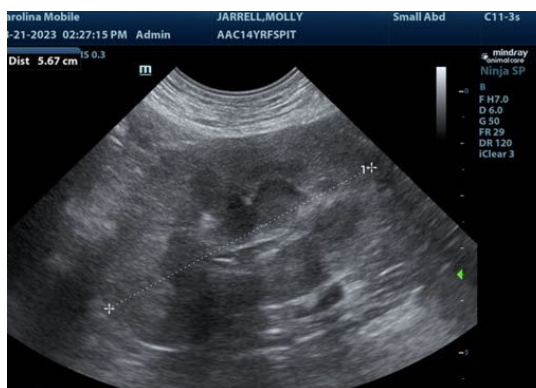Dr. Gallagher

INVOICE

46689

DATE

8/21/23



The information and recommendations provided are based on the images presented by the referring veterinarian/sonographer. No evaluation can be communicated regarding pathology that was not visible in the image/video clips provided.

Thank you for this referral. If the clinical or image interpretation does not parallel your findings or if I can be of any further assistance please contact me.

Eric Lindquist, DMV, DABVP, Cert. IVUSS, CEO of SonoPath.com
info@SonoPath.com