



PATIENT

Tigger Raleigh

SPECIES

Feline

BREED

Domestic Medium Hair

SEX

Neutered male

AGE

12 years

WEIGHT

9.9 lbs

INTERPRETED BY

Eric Lindquist, DMV
DABVP, Cert. IVUSS

IMAGING PERFORMED BY

Ginny Dodd DVM,
DABVP (CFP)

HOSPITAL NAME

Steele Creek AH

REFERRING VET

Dr. Daniels

INVOICE

77976

DATE

5/27/26

PRESENTING CLINICAL SIGNS

History: weight loss

Abnormal PE/Chem/CBC/UA Results: Skinny, weight loss CBC normal CHEM- ALT 201, amyl 1293, amyl 1293, Pwl 40 (N <26 PSI 4

ULTRASONOGRAPHIC EXAMINATION OF THE ABDOMEN

Urinary System

The **urinary bladder**, trigone, and pelvic urethra presented normal thicknesses and normal tone. The ureters were not visible which is normal. No uroliths or sediment were visualized and anechoic urine was present. No evidence of inflammatory or neoplastic changes were noted. Ureteral papillae were normal.

The **kidneys** presented a relatively uniform cortical hyperechogenicity when compared to the renal medulla, spleen and liver. No overt masses were noted. Corticomedullary definition was nebulous and the ratio favored the cortex slightly. The ureters were not visible and assumed to be normal. These changes are most consistent with chronic interstitial nephritis yet infiltrative disease could not be entirely ruled out without biopsy though neoplasia is not suspected. Moderate cortical infarct was noted in the caudal pole of the right kidney. Pinpoint mineralization was noted in both kidneys. The left kidney measured 3.3 cm. The right kidney measured 3.1 cm. Blood flow to the kidneys appeared to be subnormal on Power Doppler assessment.

Adrenal Glands

Both **adrenal glands** were visualized and recognized as having normal shape, size, position and echogenicity for this breed. The phrenic vasculature, glandular echogenicity and detail were unremarkable. Capsule, cortex, and medullary definition were normal for this age patient. The left adrenal gland measured 0.25 cm.

Spleen

The **spleen** in this patient was uniform, yet volume contracted. Hydration status should be assessed.

Liver

The **liver** images from right and left intercostal as well as subcostal views revealed subjectively normal liver size, contour, and structure. Some age-related parenchymal remodeling was noted but likely not clinically significant at this time. Vascular and biliary tracts were of normal volume and no evidence of congestion was noted. The gallbladder presented some dependent debris with essentially normal contour. The cystic and common bile ducts were normal. No overt evidence of active inflammatory, infiltrative or regenerative pathology was noted but should be paired with current or past LE elevations regarding any clinical significance to this presentation. The hepatic lymph nodes were unremarkable.



PATIENT

Tigger Raleigh

SPECIES

Feline

BREED

Domestic Medium Hair

SEX

Neutered male

AGE

12 years

WEIGHT

9.9 lbs

INTERPRETED BY

Eric Lindquist, DMV
DABVP, Cert. IVUSS

IMAGING PERFORMED BY

Ginny Dodd DVM,
DABVP (CFP)

HOSPITAL NAME

Steele Creek AH

REFERRING VET

Dr. Daniels

INVOICE

77976

DATE

5/27/26

Gastrointestinal

The **gastrointestinal tract** revealed minor variable thickening and echogenic submucosal changes most consistent with low grade end result of chronic GI disease such as IBD and may be related to malassimilation of nutrients if any weight loss is present. Intestinal wall thickness measured up to 0.35 cm. No obvious neoplastic patterns were noted and luminal content as unremarkable. The mesenteric lymph nodes were enlarged and measured up to 0.75 cm.

Pancreas

The base and limbs of the **pancreas** were observed to be largely isoechoic to surrounding omental fat. Some parenchymal remodeling, however, with mild deviation from curvilinear normalcy was observed. Pancreatic duct and capsular irregularities were present consistent with age related changes. If pain upon imaging (+ Murphy sign) was present or if the patient is focally painful in subxiphoid palpation then low-grade smoldering chronic pancreatitis should be suspected. The pancreas measured up to 0.78 cm.

ULTRASONOGRAPHIC FINDINGS

- Diffuse intestinal thickening. Chronic inflammatory bowel is likely.
- Chronic pancreatic changes.
- Mild degenerative renal changes with infarcts.

INTERPRETATION OF THE FINDINGS & FURTHER RECOMMENDATIONS

There was no overt neoplastic criteria, yet I cannot rule out pre-neoplastic state. Full thickness GI biopsies could be justified in this patient. Differentials include low-grade inflammatory hepatopathy, chronic triad disease.

Maldigestion panel, three view chest radiographs and full CNS examination is recommended to examine for occult disease that could be responsible for the weight loss. Evaluation for competitive eating environments should also be considered.



PATIENT

Tigger Raleigh

SPECIES

Feline

BREED

Domestic Medium Hair

SEX

Neutered male

AGE

12 years

WEIGHT

9.9 lbs

INTERPRETED BY

Eric Lindquist, DMV
 DABVP, Cert. IVUSS

IMAGING PERFORMED BY

Ginny Dodd DVM,
 DABVP (CFP)

HOSPITAL NAME

Steele Creek AH

REFERRING VET

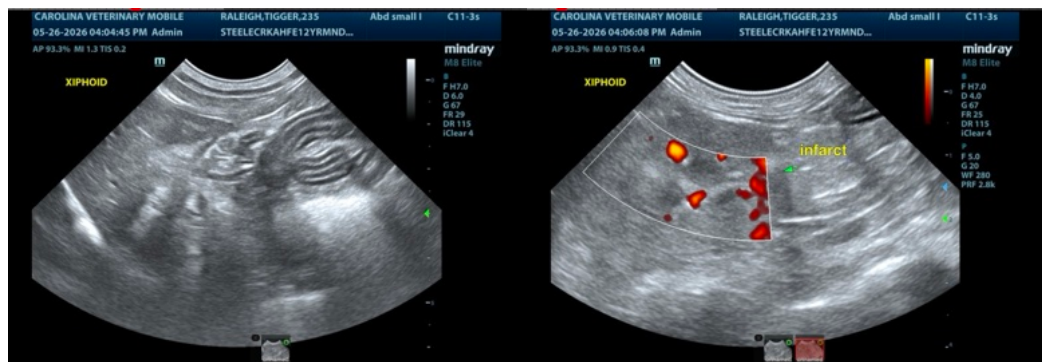
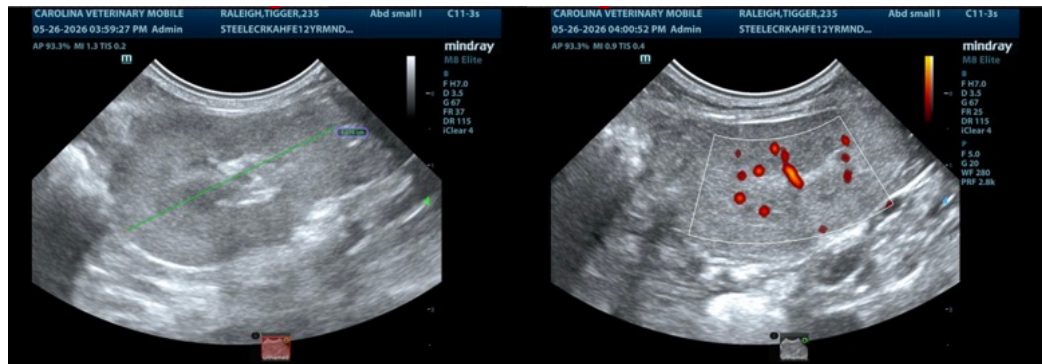
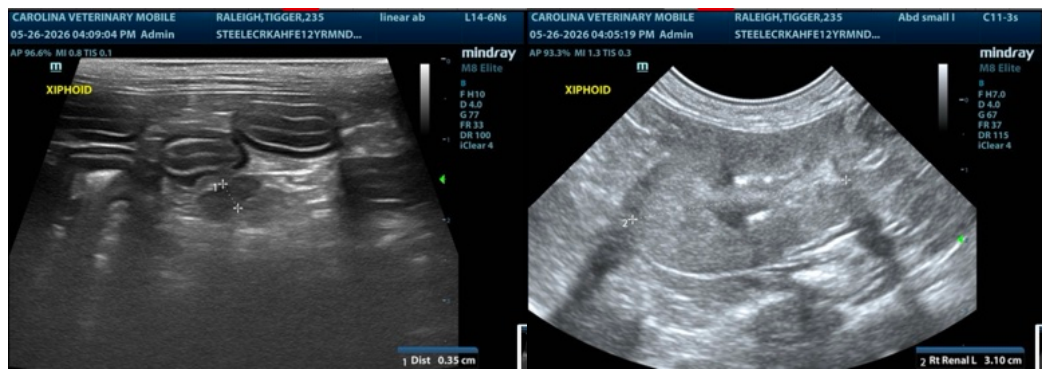
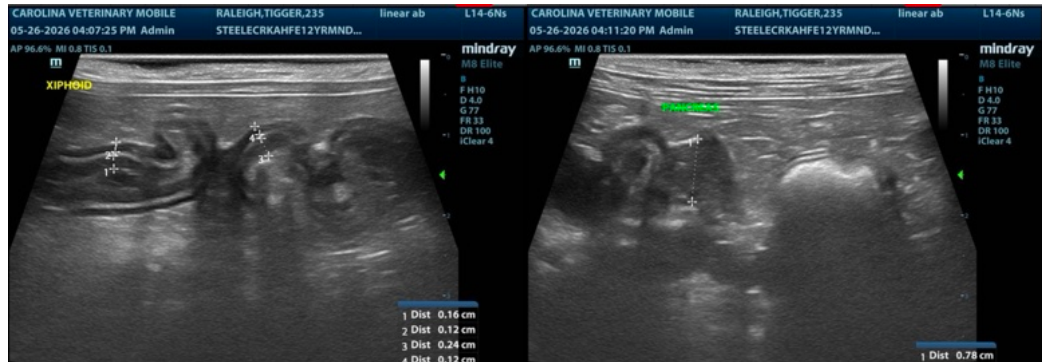Dr. Daniels

INVOICE

77976

DATE

5/27/26





PATIENT

Tigger Raleigh

SPECIES

Feline

BREED

Domestic Medium Hair

SEX

Neutered male

AGE

12 years

WEIGHT

9.9 lbs

INTERPRETED BY

Eric Lindquist, DMV
 DABVP, Cert. IVUSS

IMAGING PERFORMED BY

Ginny Dodd DVM,
 DABVP (CFP)

HOSPITAL NAME

Steele Creek AH

REFERRING VET

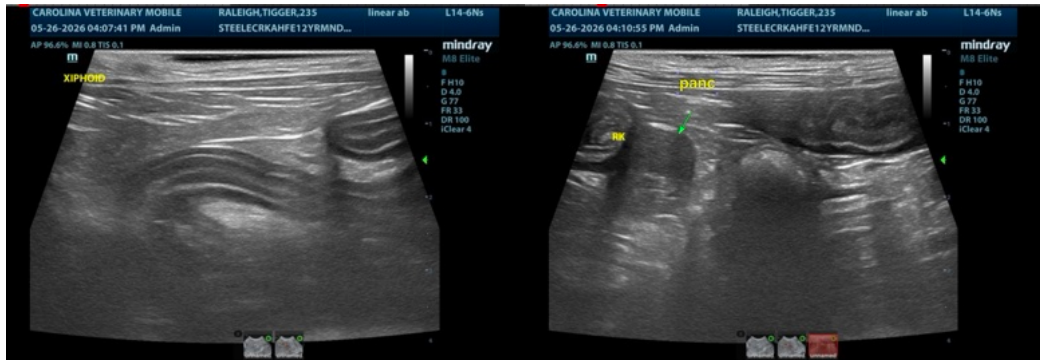
Dr. Daniels

INVOICE

77976

DATE

5/27/26



The information and recommendations provided are based on the images presented by the referring veterinarian/sonographer. No evaluation can be communicated regarding pathology that was not visible in the image/video clips provided.

Thank you for this referral. If the clinical or image interpretation does not parallel your findings or if I can be of any further assistance please contact me.

Eric Lindquist, DMV, DABVP, Cert. IVUSS, CEO of SonoPath.com

info@SonoPath.com