

PATIENT

Parker Gemini

SPECIES

Canine

BREED

Golden Retriever

SEX

Neutered male

AGE

6 years

WEIGHT

73 lbs

INTERPRETED BY

Eric Lindquist, DMV
 DABVP, Cert. IVUSS

IMAGING PERFORMED BY

Kathleen Byrnes

HOSPITAL NAME

Pet Care Clinic of the
 High Country

REFERRING VET

Dr. Sturfill

INVOICE

73403

DATE

3/11/26

PRESENTING CLINICAL SIGNS

- P initially presented on 2/17/26 for a mass on back cervical area in between shoulder blades. rDVM removed 50ml of blood and then another 20ml blood on 2/25/26. Double Cavity done and was unremarkable, Rads showed non specific soft tissue mass hematoma with no bone involvement
- Bloodwork mild thrombocytopenia, mild regenerative anemia, leukocytosis, currently on tapering prednisone and doxycycline
- today 6-8cm firm mass heteroechogenic- did FNA of echogenic areas and then drained 20mls for fluid analysis.

ULTRASONOGRAPHIC EXAMINATION

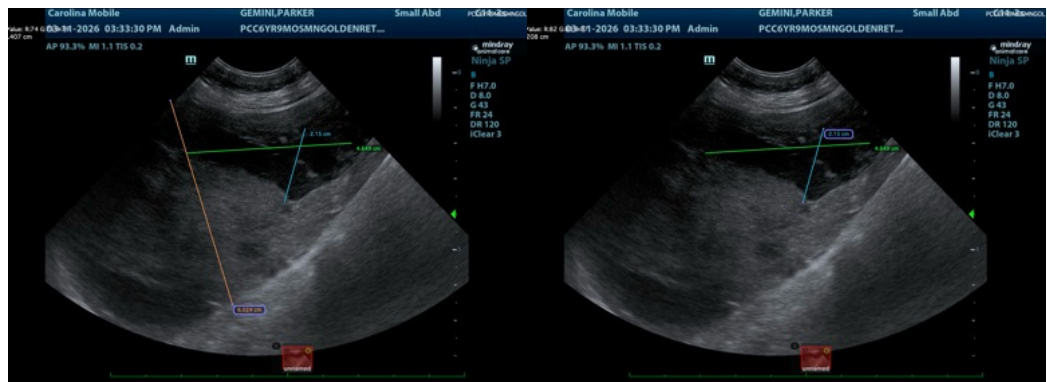
A cervical mass was imaged in this patient and presented a cavitated portion of 2.0 x 4.6 cm. The mass was subcutaneous and extended ventrally measuring 6.0 cm. The mass appeared to be fairly encapsulated, yet some fascial tissue escape was noted in the deep cranial aspect of the mass. This is strongly suggestive for sarcoma, possible hemangiosarcoma given the cavitation.

ULTRASONOGRAPHIC FINDINGS

- Subcutaneous body wall mass.

INTERPRETATION OF THE FINDINGS & FURTHER RECOMMENDATIONS

The architecture of the wall is suggestive for sarcoma. Surgical approach may have to confront irregular margins in the deep cranial aspect of the mass itself as some fascial escape appears to be occurring. The remainder of the mass appears encapsulated. CT evaluation would be optimal for surgical planning. Abdominal and thoracic imaging are indicated. Ultrasound radiographs are recommended to assess for comorbidities. The Prednisone may be suppressing a more significant presentation.





PATIENT

Parker Gemini

SPECIES

Canine

BREED

Golden Retriever

SEX

Neutered male

AGE

6 years

WEIGHT

73 lbs

INTERPRETED BY

Eric Lindquist, DMV
DABVP, Cert. IVUSS

IMAGING PERFORMED BY

Kathleen Byrnes

HOSPITAL NAME

Pet Care Clinic of the
High Country

REFERRING VET

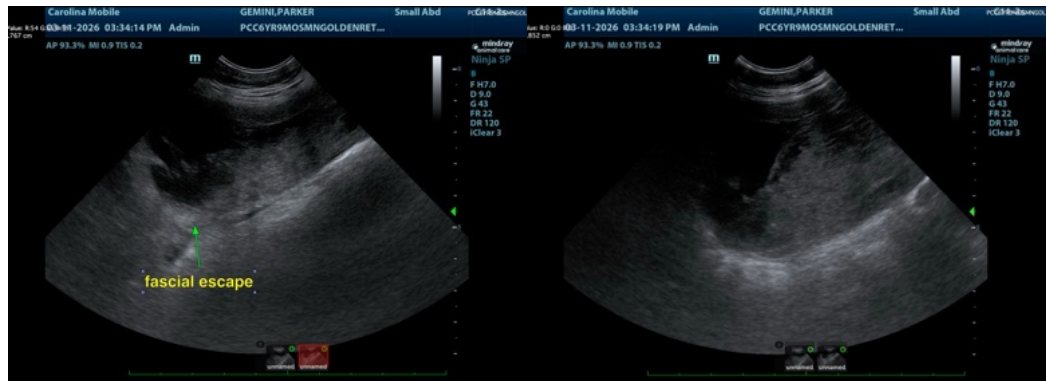Dr. Sturfill

INVOICE

73403

DATE

3/11/26



The information and recommendations provided are based on the images presented by the referring veterinarian/sonographer. No evaluation can be communicated regarding pathology that was not visible in the image/video clips provided.

Thank you for this referral. If the clinical or image interpretation does not parallel your findings or if I can be of any further assistance please contact me.

Eric Lindquist, DMV, DABVP, Cert. IVUSS, CEO of SonoPath.com

info@SonoPath.com