

PATIENT

Henriette Farrell

SPECIES

Canine

BREED

Schnauzer Mix

SEX

Neutered male

AGE

13 years

WEIGHT

26 lbs

INTERPRETED BY

Eric Lindquist, DMV
 DABVP, Cert. IVUSS

IMAGING PERFORMED BY

Ginny Dodd DVM,
 DABVP (CFP)

HOSPITAL NAME

Armstrong AC

REFERRING VET

Dr. Gallagher

INVOICE

71295

DATE

2/5/26

PRESENTING CLINICAL SIGNS

- H/O soft tissue sarcoma excised from R elbow in 2022
- Heart murmur since 2/25- echo by Dr. Byrnes 3/25
- Coughing began 2 months ago, halitosis- suspected GERDS- on Prilosec and Hydrocodone, didn't tolerate Vetmedin
- PE- Grade 4/6 murmur, HR 120, panting, harsh cough, moderate tartar, halitosis CBC, CHEM- wnl Thoracic rads- Suspected LAE, Enlargement of cranial and caudal right pulmonary veins Lungs- irregularly-shaped, well-defined soft tissue opaque mass in the cranial aspect of the right caudal lung lobe Trachea-bronchi- carina slightly displaced and abaxial displacement of the main caudal bronchi and mild dorsal displacement and narrowing of the right caudal bronchus assoc with the pulmonary mass

ULTRASONOGRAPHIC EXAMINATION OF THE ABDOMEN

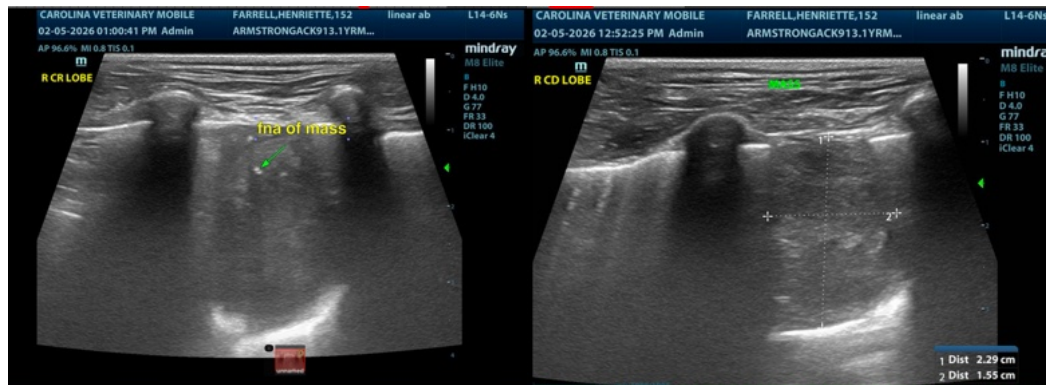
Multiple images demonstrated a 2.75 cm pulmonary mass that was deriving from the right caudal lung with peripheral areas of consolidation. Hepatization of the lung tissue and peripheral air entrapment. Ultrasound-guided FNA of the mass was performed without complication. Other views demonstrated peripheral B lines, which would suggest further alveolar spread.

ULTRASONOGRAPHIC FINDINGS

Pulmonary mass.

INTERPRETATION OF THE FINDINGS & FURTHER RECOMMENDATIONS

The extension of the pathology should be evaluated via CT for potential surgical planning. Assuming this is a neoplastic event, sarcoma or carcinoma is suspected. Pneumonia/lung necrosis is possible, yet less likely. An abdominal sonogram is recommended to assess for comorbidities or possible primary neoplasia. There was no pleural effusion noted in the views provided.





PATIENT

Henriette Farrell

SPECIES

Canine

BREED

Schnauzer Mix

SEX

Neutered male

AGE

13 years

WEIGHT

26 lbs

INTERPRETED BY

Eric Lindquist, DMV
 DABVP, Cert. IVUSS

IMAGING PERFORMED BY

Ginny Dodd DVM,
 DABVP (CFP)

HOSPITAL NAME

Armstrong AC

REFERRING VET

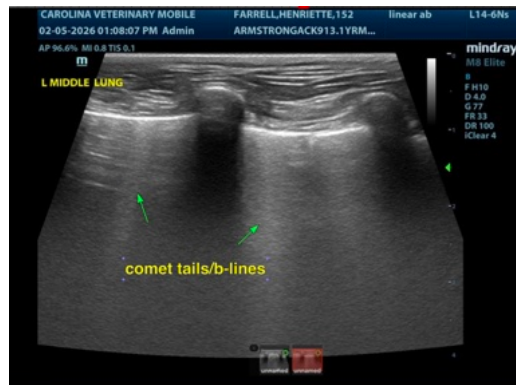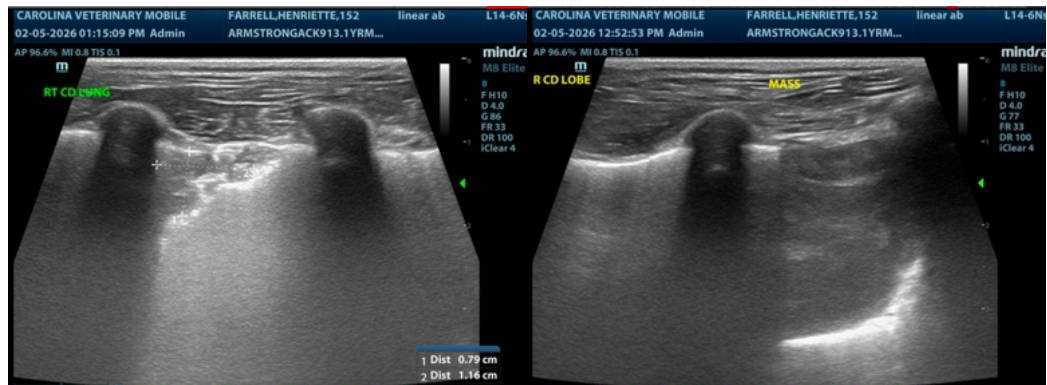
Dr. Gallagher

INVOICE

71295

DATE

2/5/26



The information and recommendations provided are based on the images presented by the referring veterinarian/sonographer. No evaluation can be communicated regarding pathology that was not visible in the image/video clips provided.

Thank you for this referral. If the clinical or image interpretation does not parallel your findings or if I can be of any further assistance please contact me.

Eric Lindquist, DMV, DABVP, Cert. IVUSS, CEO of SonoPath.com

info@SonoPath.com