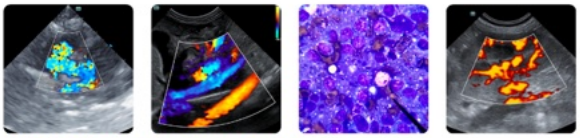

SonoPath www.carolinavetmobile.com
info@carolinavetmobile.com 800.808.5948

PATIENT
Zoey Crummett

SPECIES
Canine

BREED
Chihuahua

SEX
Spayed female

AGE
13 years

WEIGHT
22 lbs

INTERPRETED BY
Eric Lindquist, DMV DABVP, Cert. IVUSS

IMAGING PERFORMED BY
Ginny Dodd DVM, DABVP (CFP

HOSPITAL NAME
CityVet Marvin

REFERRING VET
Dr. Welsh

INVOICE
69611

DATE
12/29/25

PRESENTING CLINICAL SIGNS

History: New client presented for a dental. Prior H/O elevated liver enzymes. Pet has been asymptomatic. PE: BCS 6/9, was more wiggly when ultrasound of right liver/RK was done but not on abdominal palpation CBC- wnl CHEM- ALT 398 (previously 107 5/25) ALP 514 (previously 405 5/25)

ULTRASONOGRAPHIC EXAMINATION OF THE ABDOMEN

Urinary System

The **urinary bladder**, trigone, and pelvic urethra presented normal thicknesses and normal tone. The pelvic urethra was imaged 2.0 cm beyond the cystourethral junction and appeared normal. The ureters were not visible which is normal. No uroliths or sediment were visualized and anechoic urine was present. No evidence of inflammatory or neoplastic changes were noted. Ureteral papillae were normal.

The **kidneys** revealed largely normal size and structure, corticomedullary definition and ratio (cortex 1/3 of medulla) were essentially maintained with some age-related loss of curvilinear patterns regarding the capsule and C/M junction. The cortices presented largely uniform texture with some increased echogenicity expected for this age patient. Medullary structure differed distinctly from that of the cortex and no evidence of pelvic dilation was present. Slight microcystic cortical changes were noted. The right kidney measured 4.4 cm. The left kidney measured 4.09 cm.

Adrenal Glands

Both **adrenal glands** were visualized and recognized as having normal shape, size, position and echogenicity for this breed. The phrenic vasculature, glandular echogenicity and detail were unremarkable. Capsule, cortex, and medullary definition were normal for this age patient. The left adrenal gland measured 1.7 x 0.72 cm at the caudal pole and 0.58 cm at the cranial pole. The right adrenal gland measured 1.26 x 0.5 cm at the caudal pole and 0.43 cm at the cranial pole.

Spleen

The **spleen** was largely smooth with subtle heterogeneous parenchymal changes while maintaining normal echogenic relationship to the liver and kidney. These changes are consistent with normal age-related alteration. Occasional hyperechoic lipid plaque was noted. The capsule was smooth without noticeable impingement from within the spleen or from pathology in the adjacent abdomen. The splenic vasculature demonstrated normal volume without signs of congestion or significant contraction. No evidence of active acute or chronic inflammatory, neoplastic, or infarctual changes was noted.

Liver

The **liver** was uniformly swollen. The liver presented coarse architecture with mildly increased portal markings and subtle, mixed echogenic changes. This is consistent with vacuolar hepatopathy and some level of remodeling and history of inflammatory component. There was no overt suspicion of neoplasia.

PATIENT
Zoey Crummett

SPECIES
Canine

BREED
Chihuahua

SEX
Spayed female

AGE
13 years

WEIGHT
22 lbs

INTERPRETED BY
Eric Lindquist, DMV DABVP, Cert. IVUSS

IMAGING PERFORMED BY
Ginny Dodd DVM, DABVP (CFP

HOSPITAL NAME
CityVet Marvin

REFERRING VET
Dr. Welsh

INVOICE
69611

DATE
12/29/25

Minor polyps were noted in the gallbladder measuring up to 0.45 cm. This is not pathological. No gallbladder over dissension was noted.

Gastrointestinal

The **stomach** revealed a fluid filled lumen. The small intestines and colon were unremarkable with normal curvilinear mural patterns and content.

Pancreas

The base and limbs of the **pancreas** were observed to be largely isoechoic to surrounding omental fat. Pancreatic duct and capsular contour were acceptably normal and parenchyma respected normal curvilinear patterns. No overt evidence of active inflammatory or neoplastic disease was noted.

ULTRASONOGRAPHIC FINDINGS

- Benign hepatopathy. Non-specific inflammatory hepatopathy/vacuolar hepatopathy pattern.
- Benign gallbladder polyps, no evidence of mucocele formation.
- Mild gastric fluid. Otherwise, structurally unremarkable GI tract.

INTERPRETATION OF THE FINDINGS & FURTHER RECOMMENDATIONS

FNA of the liver can be considered for further definition. Hepatic nutraceuticals can be considered. Diet change to address any potential reactive hepatopathy component can also be considered.

The hepatic clinical sonographic presentation is most consistent with Reactive Hepatopathy which is the most common cause of liver enzyme elevation in dogs and cats. The presumption is that gut and other organ antigen stimuli may be causing a low-grade immune response through portal system with which the liver is reacting to causing low-grade enzyme elevations. US-guided FNA could be performed to assess if low grade lymphoplasmacytic inflammation is present that would support this theory. If FNA is performed, please ask the cytologist to emphasize the primary inflammatory cell type. Empirical treatment measures to address this issue can include diet change to hydrolyzed diet, probiotics, deworming, nutraceuticals (SAMe, Actigall…), dental exam and cleaning, and potentially antibiotics such as Clavamox. Metronidazole and Tylosin have traditionally been utilized for this purpose but new studies show that both these antibiotics can disrupt the normal intestinal bacterial flora (intestinal dysbiosis) for weeks and up to 4-6 months. Therefore, Metronidazole and Tylosin should be utilized as a last resort if other efforts have not been effective and sonographic organ appearance remains benign.

Carolina Veterinary Mobile
FUELED BY SONOPATH VETERINARY ULTRASOUND

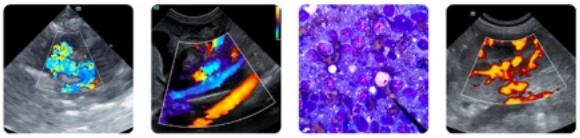

Clinical Sonography & Telecytology
Educational Teleconsultation Services™

SonoPath
www.carolinavetmobile.com
info@carolinavetmobile.com
800.808.5948

PATIENT

Zoey Crummett

SPECIES

Canine

BREED

Chihuahua

SEX

Spayed female

AGE

13 years

WEIGHT

22 lbs

INTERPRETED BY

Eric Lindquist, DMV
DABVP, Cert. IVUSS

IMAGING PERFORMED BY

Ginny Dodd DVM,
DABVP (CFP

HOSPITAL NAME

CityVet Marvin

REFERRING VET

Dr. Welsh

INVOICE

69611

DATE

12/29/25

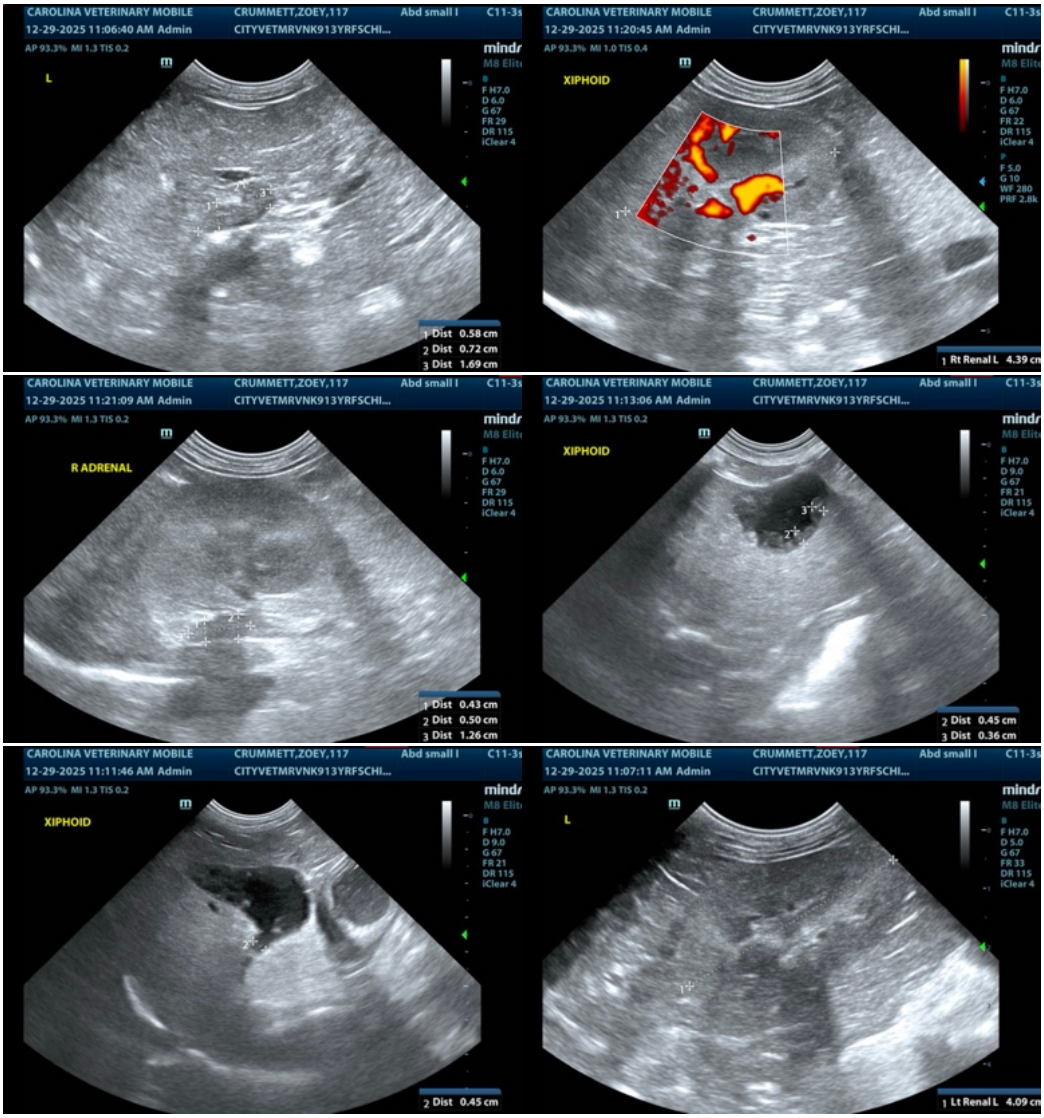

Carolina Veterinary Mobile
FUELED BY SONOPATH VETERINARY ULTRASOUND

SonoPath
www.carolinavetmobile.com
info@carolinavetmobile.com
800.808.5948

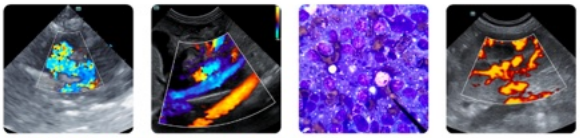

Clinical Sonography & Telecytology
Educational Teleconsultation Services™

PATIENT

Zoey Crummett

SPECIES

Canine

BREED

Chihuahua

SEX

Spayed female

AGE

13 years

WEIGHT

22 lbs

INTERPRETED BY

Eric Lindquist, DMV
DABVP, Cert. IVUSS

IMAGING PERFORMED BY

Ginny Dodd DVM,
DABVP (CFP

HOSPITAL NAME

CityVet Marvin

REFERRING VET

Dr. Welsh

INVOICE

69611

DATE

12/29/25

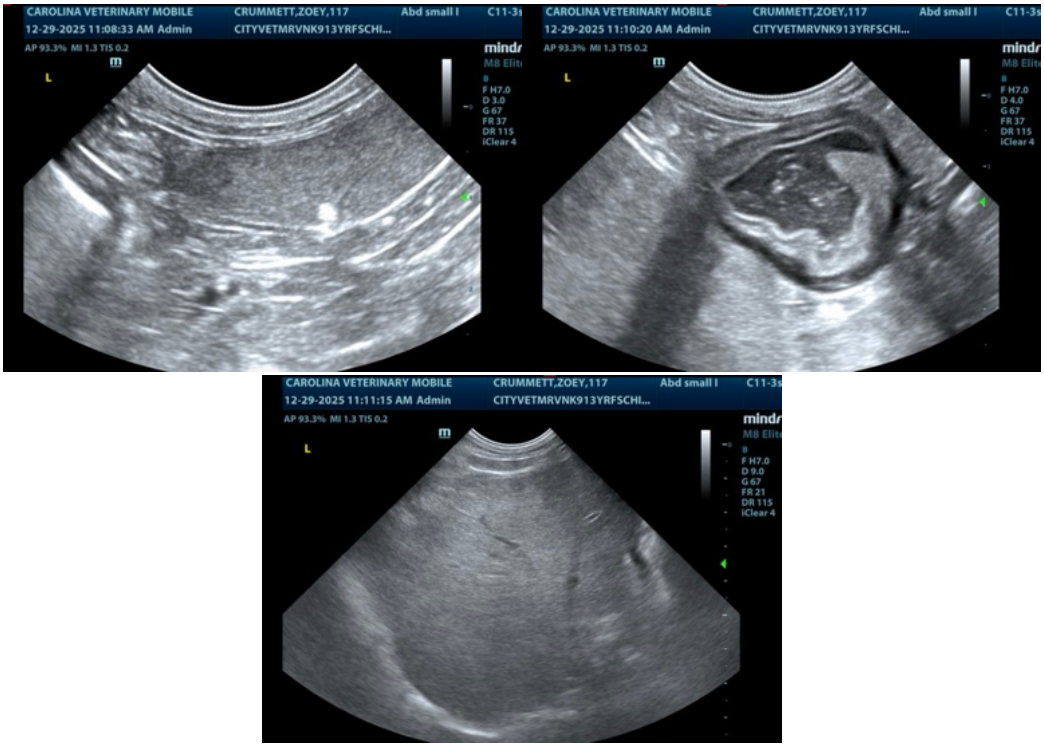

The information and recommendations provided are based on the images presented by the referring veterinarian/sonographer. No evaluation can be communicated regarding pathology that was not visible in the image/video clips provided.

Thank you for this referral. If the clinical or image interpretation does not parallel your findings or if I can be of any further assistance please contact me.

Eric Lindquist, DMV, DABVP, Cert. IVUSS, CEO of SonoPath.com

info@SonoPath.com