



**PATIENT**

Nutmeg DuPut

**SPECIES**

Canine

**BREED**

Canine

**SEX**

Spayed female

**AGE**

9.3 years

**WEIGHT**

61 lbs

**INTERPRETED BY**

Eric Lindquist, DMV  
DABVP, Cert. IVUSS

**IMAGING PERFORMED BY**

Ginny Dodd DVM,  
DABVP (CFP)

**HOSPITAL NAME**

City Vet Marvin

**REFERRING VET**

Dr. Welsh

**INVOICE**

70868

**DATE**

1/22/26

**PRESENTING CLINICAL SIGNS**

- H/O a small splenic nodule seen on 2 previous AUS; persistent mild ALT elevation (274)
- PE: Nervous and panting when restrained, no heart murmur, BCS 3/5 CHEM ALT 274

**ULTRASONOGRAPHIC EXAMINATION OF THE ABDOMEN**  
*Urinary System*

The **urinary bladder**, trigone, and pelvic urethra presented normal thicknesses and normal tone. The pelvic urethra was imaged 2.0 cm beyond the cystourethral junction and appeared normal. The ureters were not visible which is normal. No uroliths or sediment were visualized and anechoic urine was present. No evidence of inflammatory or neoplastic changes were noted. Ureteral papillae were normal.

The **kidneys** revealed normal size and structure, corticomedullary definition and ratio for this age. The cortices presented largely uniform texture with normal echogenic relationship to liver and spleen. Medullary structure differed distinctly from the cortex and no evidence of pelvic dilation was present. The capsules were acceptably uniform without significant irregularities. The left kidney measured 5.13 cm. The right kidney measured 5.62 cm.

*Adrenal Glands*

Both **adrenal glands** were visualized and recognized as having normal shape, size, position and echogenicity for this breed. The phrenic vasculature, glandular echogenicity and detail were unremarkable. Capsule, cortex, and medullary definition were normal for this age patient. The left adrenal gland measured 0.5 cm. The right adrenal gland measured 0.57 cm.

*Spleen*

Minor, heterogenous parenchymal changes were noted in the **spleen** without distinct nodular changes. There was no disruption of architecture present.

*Liver*

The **liver** images from right and left intercostal as well as subcostal views revealed subjectively normal liver size, contour, and structure. Some age-related parenchymal remodeling was noted but likely not clinically significant at this time. Vascular and biliary tracts were of normal volume and no evidence of congestion was noted. The gallbladder presented some dependent debris with essentially normal contour. The cystic and common bile ducts were normal. No overt evidence of active inflammatory, infiltrative or regenerative pathology was noted but should be paired with current or past LE elevations regarding any clinical significance to this presentation. The hepatic lymph nodes were unremarkable.

*Gastrointestinal*

Examination of the **gastrointestinal tract** revealed a stomach and intestine free of stasis, of normal wall thickness, acceptable curvilinear mural detail, and peristaltic activity. Small and large intestine



**PATIENT**

Nutmeg DuPut

demonstrated normal luminal chyme and stool consistency respectively. No obstructive or overt infiltrative disease was noted. No associated abnormal lymphatic activity was noted.

**SPECIES**

Canine

**Pancreas**

The base and limbs of the **pancreas** were observed to be largely isoechoic to surrounding omental fat. Pancreatic duct and capsular contour were acceptably normal and parenchyma respected normal curvilinear patterns. No overt evidence of active inflammatory or neoplastic disease was noted.

**BREED**

Canine

**SEX**

Spayed female

**ULTRASONOGRAPHIC FINDINGS**

- Structurally unremarkable abdomen.
- Given the liver enzyme elevations, likely reactive hepatopathy.
- Minor heterogenous splenic changes without overt nodules, hyperplastic pattern.

**AGE**

9.3 years

**INTERPRETATION OF THE FINDINGS & FURTHER RECOMMENDATIONS**

There was no evidence of significant disease.

The hepatic clinical sonographic presentation is most consistent with Reactive Hepatopathy which is the most common cause of liver enzyme elevation in dogs and cats. The presumption is that gut and other organ antigen stimuli may be causing a low-grade immune response through portal system with which the liver is reacting to causing low-grade enzyme elevations. US-guided FNA could be performed to assess if low grade lymphoplasmacytic inflammation is present that would support this theory. If FNA is performed, please ask the cytologist to emphasize the primary inflammatory cell type. Empirical treatment measures to address this issue can include diet change to hydrolyzed diet, probiotics, deworming, nutraceuticals (SAME, Actigall...), dental exam and cleaning, and potentially antibiotics such as Clavamox. Metronidazole and Tylosin have traditionally been utilized for this purpose but new studies show that both these antibiotics can disrupt the normal intestinal bacterial flora (intestinal dysbiosis) for weeks and up to 4-6 months. Therefore, Metronidazole and Tylosin should be utilized as a last resort if other efforts have not been effective and sonographic organ appearance remains benign.

**WEIGHT**

61 lbs

**INTERPRETED BY**

Eric Lindquist, DMV  
 DABVP, Cert. IVUSS

**IMAGING PERFORMED BY**

Ginny Dodd DVM,  
 DABVP (CFP)

**HOSPITAL NAME**

City Vet Marvin

**REFERRING VET**

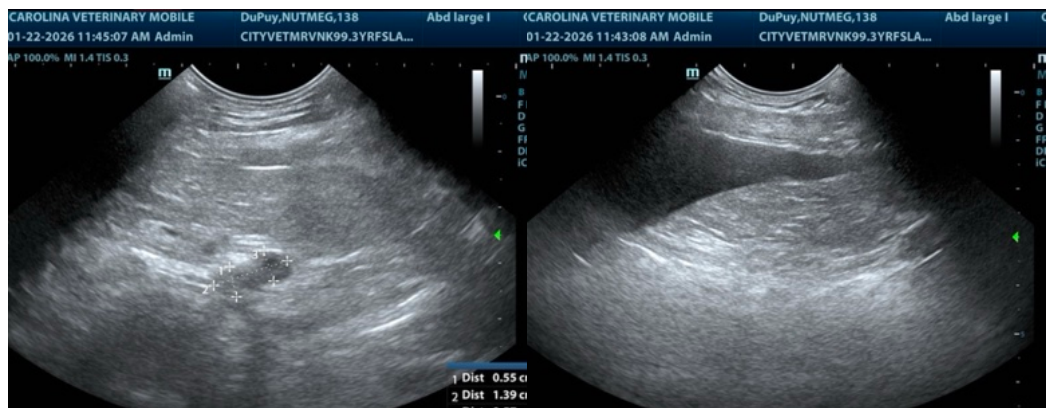
Dr. Welsh

**INVOICE**

70868

**DATE**

1/22/26





**PATIENT**

Nutmeg DuPut

**SPECIES**

Canine

**BREED**

Canine

**SEX**

Spayed female

**AGE**

9.3 years

**WEIGHT**

61 lbs

**INTERPRETED BY**

Eric Lindquist, DMV  
 DABVP, Cert. IVUSS

**IMAGING PERFORMED BY**

Ginny Dodd DVM,  
 DABVP (CFP)

**HOSPITAL NAME**

City Vet Marvin

**REFERRING VET**

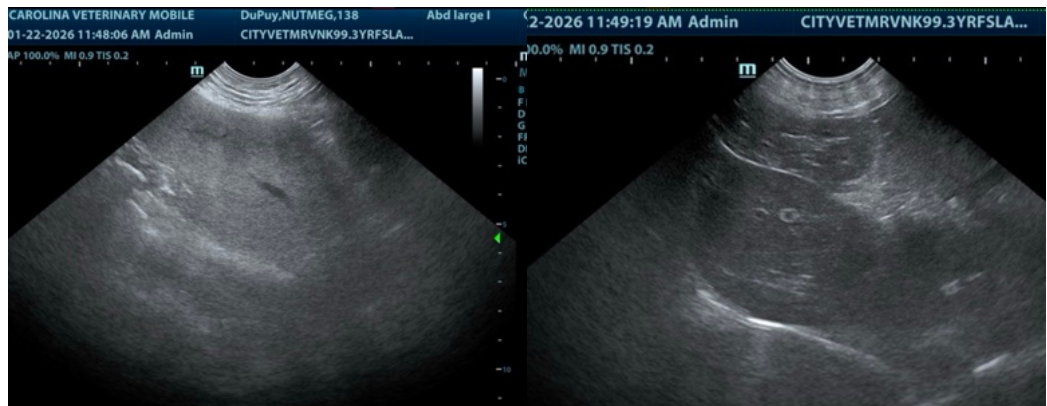
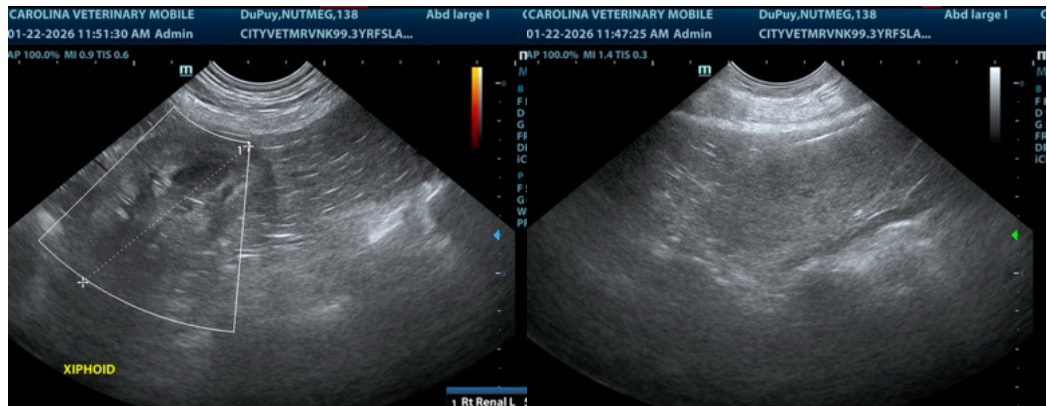
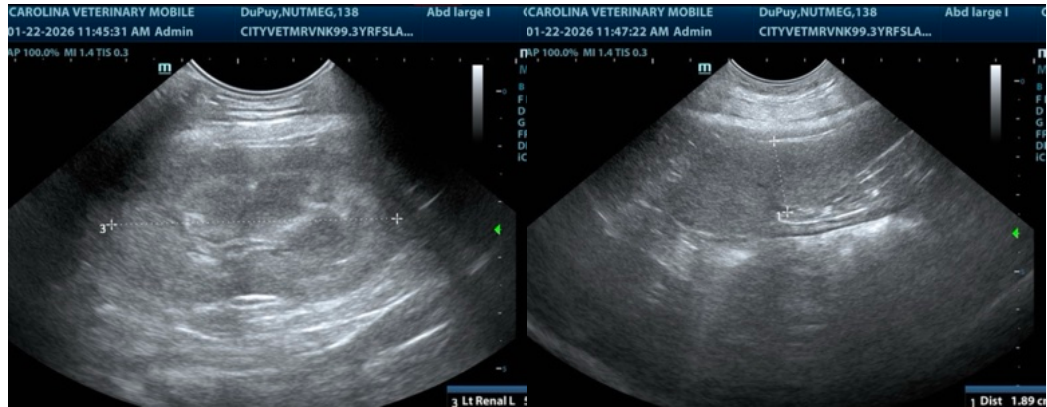
Dr. Welsh

**INVOICE**

70868

**DATE**

1/22/26





**PATIENT**

Nutmeg DuPut

**SPECIES**

Canine

**BREED**

Canine

**SEX**

Spayed female

**AGE**

9.3 years

**WEIGHT**

61 lbs

**INTERPRETED BY**

Eric Lindquist, DMV  
 DABVP, Cert. IVUSS

**IMAGING PERFORMED BY**

Ginny Dodd DVM,  
 DABVP (CFP)

**HOSPITAL NAME**

City Vet Marvin

**REFERRING VET**

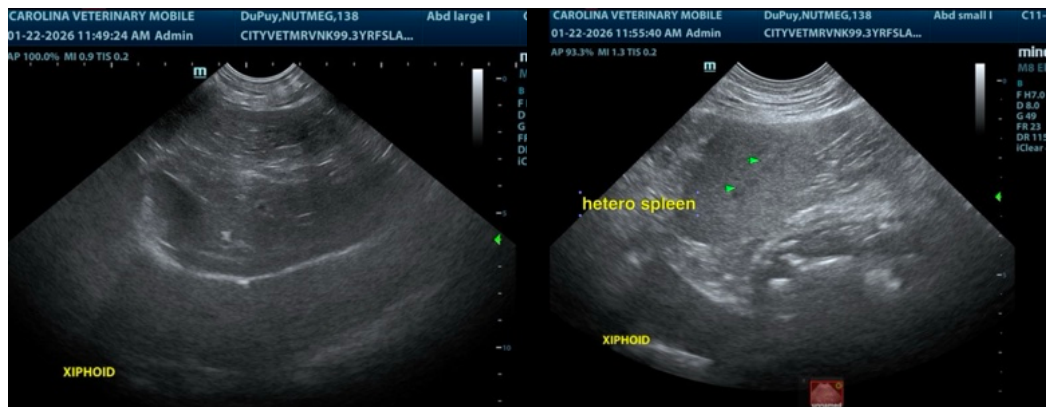
Dr. Welsh

**INVOICE**

70868

**DATE**

1/22/26



The information and recommendations provided are based on the images presented by the referring veterinarian/sonographer. No evaluation can be communicated regarding pathology that was not visible in the image/video clips provided.

Thank you for this referral. If the clinical or image interpretation does not parallel your findings or if I can be of any further assistance please contact me.

**Eric Lindquist, DMV, DABVP, Cert. IVUSS, CEO of SonoPath.com**

[info@SonoPath.com](mailto:info@SonoPath.com)