

PATIENT PRESENTING CLINICAL SIGNS

Desi Schrier History: Presenting for intermittent poor appetite, no weight loss Heart murmur IV/VI left side (progressive) periodontal dz gr 4 Abd palpates wnl

SPECIES Abnormal PE/Chem/CBC/UA Results: CBC and Chemistry WNI mildly elevated platelets NR/RR/BP - 130 HR, RR pant/115mmHg systolic

Canine

BREED ULTRASONOGRAPHIC EXAMINATION OF THE HEART

Small Mix The echocardiogram in this patient demonstrated normal **left atrial** size based on 3 different LA measurement methods. Chamber volumes and echogenicity were normal. The cranial and caudal **mitral** valve leaflets presented vegetative thickening consistent with endocardiosis. Doppler indicated measurable insufficiency. The **left ventricle** presented normal thicknesses with linear contour and was not dilated nor restricted. The **myocardium** presented normal echogenicity without subjective evidence of significant fibrotic or ischemic disease. **Contractility** of the ventricular walls was adequate and in normal range for this patient evidenced by the fractional shortening measurement and subjective evaluation of the different regions of the myocardium. The **left ventricular outflow** tract demonstrated normal laminar flow and subjective structural integrity. The **right atrium** and auricle revealed normal size, structure and content. No evidence of masses was noted or chamber overload. **Tricuspid** valvular assessment demonstrated adequate linear morphology. The **right ventricle** was of normal size (1/3 diameter of LV), chordae structure, myocardial echogenicity and thickness. **Pulmonic** tract assessment revealed normal valve structure, laminar flow, and diameter (approx. 1:1 pa/ao ratio) measuring 1.0 m/sec. No visible **pericardial** or free pleura fluid was noted. No echographically detectable evidence of infiltrative disease was visible. The cranial **mediastinum and pericardial regions** were free of masses in the visible window.

INTERPRETED BY

Eric Lindquist, DMV, DABVP, Cert. IVUSS, CEO of SonoPath.com

IMAGING PERFORMED BY

Andrea Nicastro, DVM, Diplomate ACVIM (Small Animal Internal Medicine)

HOSPITAL NAME

Sun Dog Cat Moon

REFERRING VET

Dr. Wilson

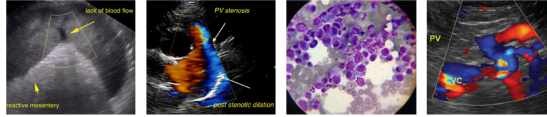
INVOICE

32921

DATE

9/15/22

CANINE CARDIAC PARAMETERS	MR VMAX (m/s)	TR VMAX (m/s)	LA/AO (Boon method)	LA/AO (Heart Base; Swe)	FS (%)	EF (%)	EPSS (cm)
NORMAL PARAMETER	4.5-5.5	<2.7	1.3	<1.6	28-40	40-100	<0.6
PATIENT	5.0		1.1		45	80	0.1
CANINE CARDIAC PARAMETERS	HR (BPM)	AV VMAX (m/s)	PV MAX (m/s)	BODY WEIGHT	LA (2D short axis Base view) (cm)	LVIDd (Avg; 2D and m-mode short axis) (cm)	LVIDs (Avg; 2D and m-mode short axis) (cm)
NORMAL PARAMETER	50-100	0.7-1.7	0.7-1.6	BELOW	BELOW	BELOW	BELOW
PATIENT	90	1.2	0.9	16 lbs	2.4 max	2.0	



PATIENT ULTRASONOGRAPHIC FINDINGS

Desi Schrier Stage B1 valvular disease.

SPECIES

Canine

BREED

Small Mix

SEX

Neutered male

AGE

11 yrs

WEIGHT

16 lbs

INTERPRETED BY

Eric Lindquist, DMV,
DABVP, Cert. IVUSS,
CEO of SonoPath.com

IMAGING PERFORMED BY

Andrea Nicastro, DVM,
Diplomate ACVIM
(Small Animal Internal
Medicine)

HOSPITAL NAME

Sun Dog Cat Moon

REFERRING VET

Dr. Wilson

INVOICE

32921

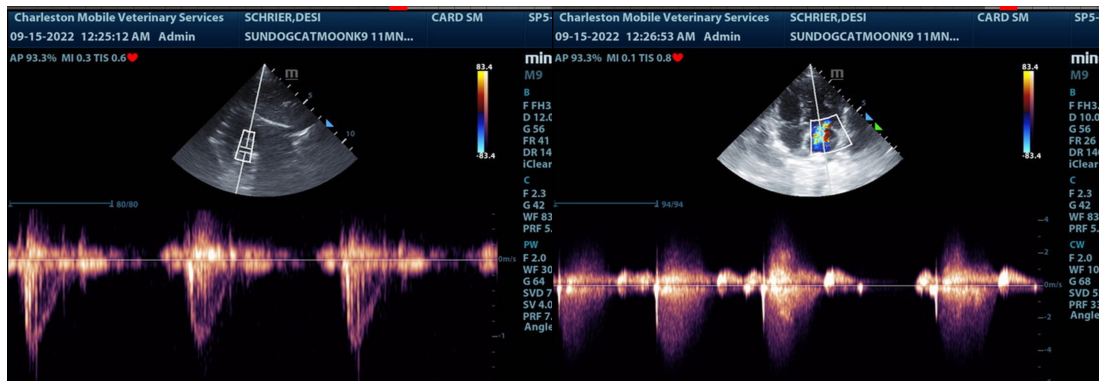
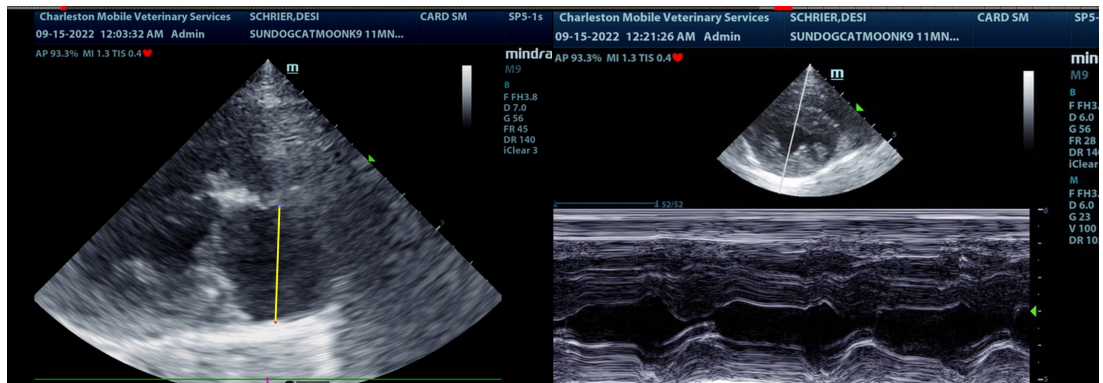
DATE

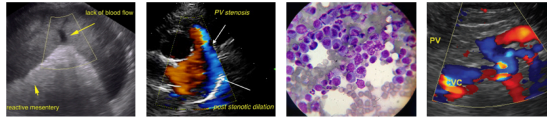
9/15/22

INTERPRETATION OF THE FINDINGS & FURTHER RECOMMENDATIONS

There is no evidence of clinical pathology.

The heart is stable without clinical disease. No overt contraindication for anesthesia of brief to moderate duration. I suggest Torbutrol premed, Propofol induction, Isoflo maintenance or similar protocol if anesthesia is desired. Blood pressure recommended if not already performed and target white coat negative systolic pressure of < 160 mmHg. If higher than this ACE-inhibitor is suggested to reach this level. Recheck echocardiogram is recommended in 6 months, earlier if murmur grade increases or clinical signs initiate.





PATIENT

Desi Schrier

SPECIES

Canine

BREED

Small Mix

SEX

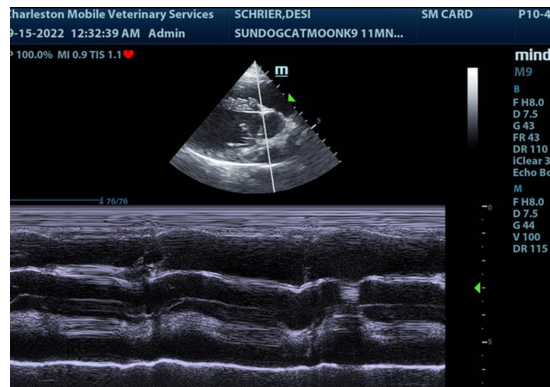
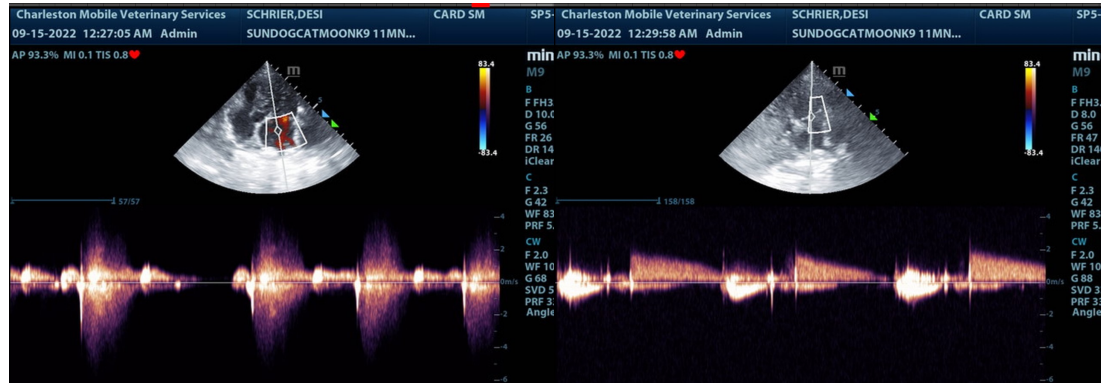
Neutered male

AGE

11 yrs

WEIGHT

16 lbs



INTERPRETED BY

Eric Lindquist, DMV,
DABVP, Cert. IVUSS,
CEO of SonoPath.com

IMAGING PERFORMED BY

Andrea Nicastro, DVM,
Diplomate ACVIM
(Small Animal Internal
Medicine)

HOSPITAL NAME

Sun Dog Cat Moon

REFERRING VET

Dr. Wilson

INVOICE

32921

DATE

9/15/22

The information and recommendations provided are based on the images presented by the referring veterinarian. No evaluation can be communicated regarding pathology that was not visible in the image/video clips provided.

Thank you for this referral. If the clinical or image interpretation does not parallel your findings or if I can be of any further assistance please contact me.

Eric Lindquist, DMV, DABVP, Cert. IVUSS, CEO of SonoPath.com

Info@SonoPath.com