
**PATIENT PRESENTING CLINICAL SIGNS**

Caroline Stephens

**SPECIES**

Canine

**BREED**

Labrador

**SEX**

Spayed Female

**AGE**

6/25/14

**WEIGHT**

37.5 kg

**INTERPRETED BY**

 Eric Lindquist, DMV,  
 DABVP, Cert. IVUSS,  
 CEO of SonoPath.com

**IMAGING PERFORMED BY**

 Andrea Nicastro, DVM,  
 Diplomate ACVIM  
 (Small Animal Internal  
 Medicine)

**HOSPITAL NAME**

 Veterinary Specialty  
 Care Blue Pearl

**REFERRING VET**

Dr. Graham

**INVOICE**

30874

**DATE**

6/7/22

Hx on/off V/D/inappetence since May. Managed by rDVM until now. rDVM noticed abdominal fluid on Afast today. Transferred here for suspected pancreatitis. Peritoneal effusion (pcv/ts <1%/3.6 g/dL) at presentation. Radiology Report: The cardiac silhouette appears enlarged and there is evidence of increased perihilar density. There is also evidence of abdominal effusion. Systemic disease is likely. ABD u/s official report pending; marked peritoneal effusion, thickened irregular bladder wall, small liver nodule, prominent pancreas.

Abnormal PE/Chem/CBC/UA Results: BP-132mmHg, systolic (Doppler) No. 4 cuff, LF Leg At admit: HR 140, RR pant; After several hours: HR 72, RR 48 BUN 42, CREA 2.9, PHOS 7.4, ALT 165, GGT 23, TP 4.7, GLOB 2.3 RETIC 133.1, WBC 17.66, NEU 14.38, PLT 94 (Estimated Manual Platelet Count: 108,000)

Radiographs revealed generalized cardiomegaly and hilar density on radiographs.

**ULTRASONOGRAPHIC EXAMINATION OF THE HEART**

The echocardiogram in this patient presented moderate to severe volume overload in all four chambers with mitral and tricuspid insufficiency and hypocontractility. The left ventricular free wall presented minimal contractility where the ventricular septum presented moderate hypokinesis. This is most consistent with dilated cardiomyopathy with myocardial insufficiency. This is consistent with left and right-sided failure.

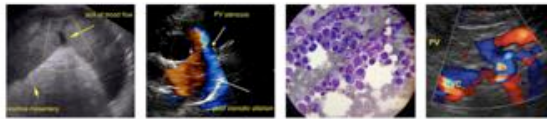
CANINE	MR	TR	LA/AO	LA/AO	FS	EF	EPSS
<b>CARDIAC PARAMETERS</b>	<b>VMAX</b> (m/s)	<b>VMAX</b> (m/s)	(Boon method)	(Heart Base; Swe)	(%)	(%)	(cm)
<b>NORMAL PARAMETER</b>	4.5-5.5	<2.7	1.3	<1.3	28-40	40-100	<0.6
<b>PATIENT</b>	-	-	NM	2.1	20	40	0.93
CANINE	HR	AV	PV	BODY WEIGHT	LA	LVIDd	LVIDs
<b>CARDIAC PARAMETERS</b>	(BPM)	<b>VMAX</b> (m/s)	<b>MAX</b> (m/s)	(kg)	2D short axis Base view (cm)	Avg; 2D and m-mode short axis (cm)	Avg; 2D and m-mode short axis (cm)
<b>NORMAL PARAMETER</b>	50-100	0.7-1.7	0.7-1.6				
<b>PATIENT</b>		1.0	0.6	37.5	5.22	5.0	

**ULTRASONOGRAPHIC FINDINGS**

DCM, nutritional cardiomyopathy and myocarditis are all possible in this patient.

**INTERPRETATION OF THE FINDINGS & FURTHER RECOMMENDATIONS**

If infectious agents that cause myocarditis are present in your region appropriate titers would be indicated. I recommend Lasix at 2-4 mg/kg b.i.d., Spironolactone at 1-2 mg/kg b.i.d., ace inhibitor at 0.5 mg/kg s.i.d. progressing to b.i.d. and Pimobendan at 0.3 mg/kg b.i.d. Taurine supplementation is



**PATIENT**

warranted. Blood pressure measurements are indicated. Prognosis is guarded. Recheck echocardiogram in a week.

Caroline Stephens

**SPECIES**

Canine

**BREED**

Labrador

**SEX**

Spayed Female

**AGE**

6/25/14

**WEIGHT**

37.5 kg

**INTERPRETED BY**

Eric Lindquist, DMV,  
DABVP, Cert. IVUSS,  
CEO of SonoPath.com

**IMAGING PERFORMED BY**

Andrea Nicastro, DVM,  
Diplomate ACVIM  
(Small Animal Internal  
Medicine)

**HOSPITAL NAME**

Veterinary Specialty  
Care Blue Pearl

**REFERRING VET**

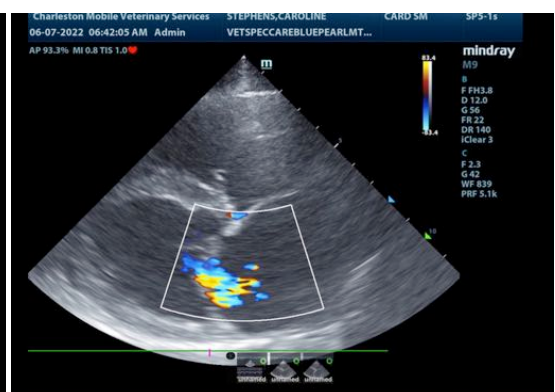
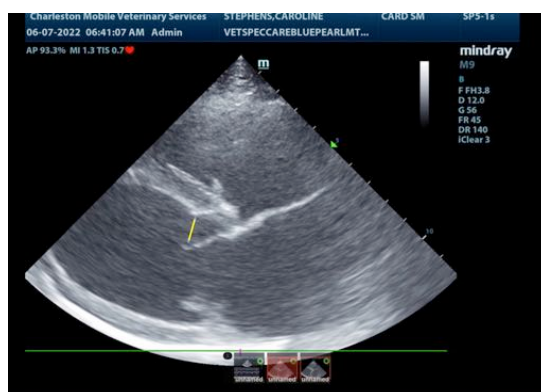
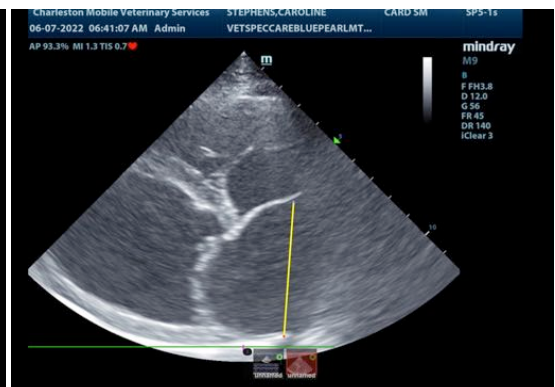
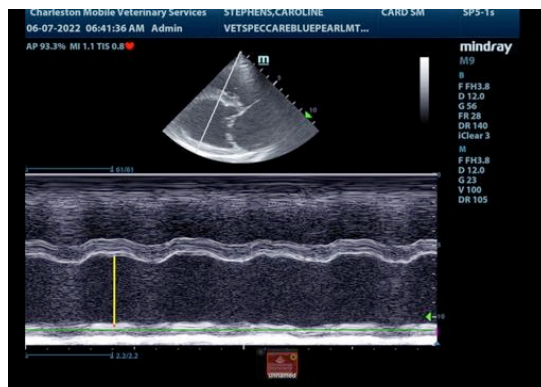
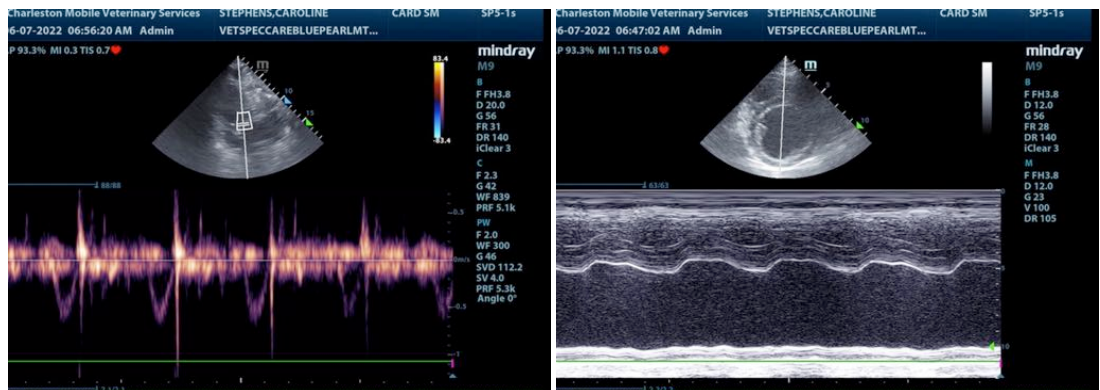
Dr. Graham

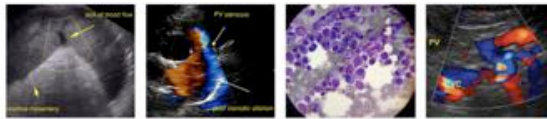
**INVOICE**

30874

**DATE**

6/7/22





**PATIENT**

Caroline Stephens

**SPECIES**

Canine

**BREED**

Labrador

**SEX**

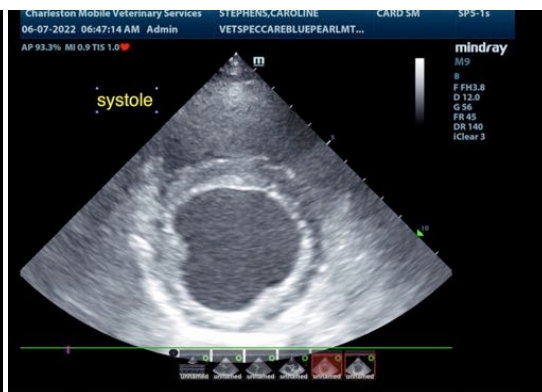
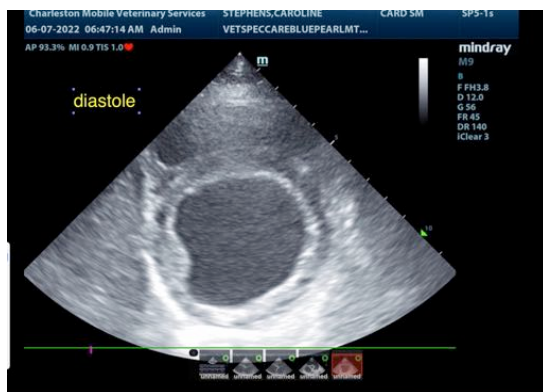
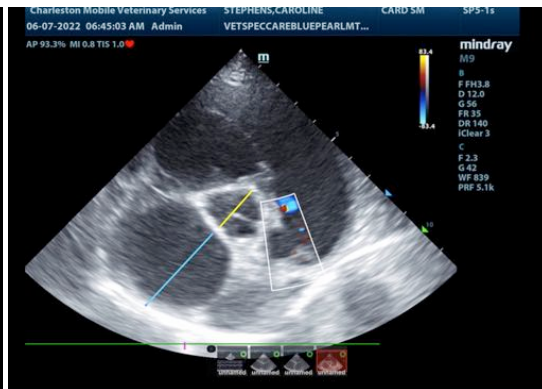
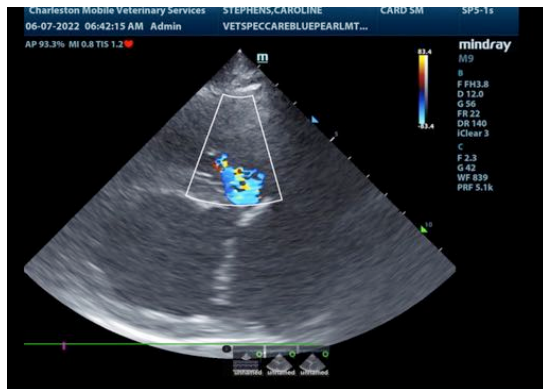
Spayed Female

**AGE**

6/25/14

**WEIGHT**

37.5 kg



**INTERPRETED BY**

Eric Lindquist, DMV,  
DABVP, Cert. IVUSS,  
CEO of SonoPath.com

**IMAGING PERFORMED BY**

Andrea Nicastro, DVM,  
Diplomate ACVIM  
(Small Animal Internal  
Medicine)

**HOSPITAL NAME**

Veterinary Specialty  
Care Blue Pearl

**REFERRING VET**

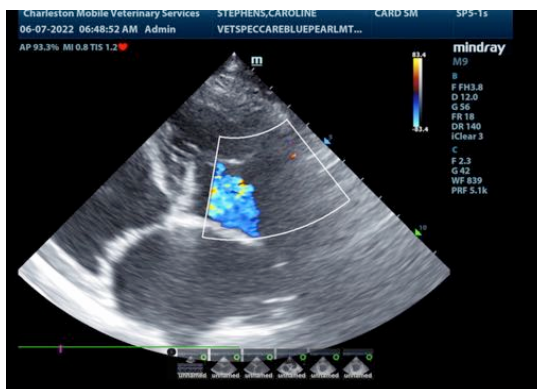Dr. Graham

**INVOICE**

30874

**DATE**

6/7/22

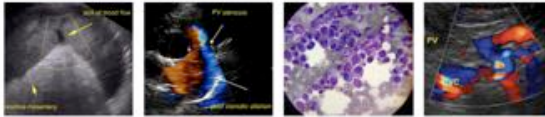


The information and recommendations provided are based on the images presented by the referring veterinarian. No evaluation can be communicated regarding pathology that was not visible in the image/video clips provided.

Thank you for this referral. If the clinical or image interpretation does not parallel your findings or if I can be of any further assistance please contact me.

Eric Lindquist, DMV, DABVP, Cert. IVUSS, CEO of SonoPath.com

Info@SonoPath.com



#### PATIENT

Caroline Stephens

#### SPECIES

Canine

#### BREED

Labrador

#### SEX

Spayed Female

#### AGE

6/25/14

#### WEIGHT

37.5 kg

#### INTERPRETED BY

Eric Lindquist, DMV,  
DABVP, Cert. IVUSS,  
CEO of SonoPath.com

#### IMAGING PERFORMED BY

Andrea Nicastro, DVM,  
Diplomate ACVIM  
(Small Animal Internal  
Medicine)

#### HOSPITAL NAME

Veterinary Specialty  
Care Blue Pearl

#### REFERRING VET

Dr. Graham

#### INVOICE

30874

#### DATE

6/7/22

## Canine Dilated Cardiomyopathy

<http://www.sonopath.com/DilatedCMY>

**Description:** Dilated cardiomyopathy (DCM) is the most significant acquired cardiac disease of large to giant breed dogs; it especially affects Doberman Pinschers, Great Danes, and Labrador Retrievers. DCM is primarily a systolic dysfunction caused by a progressive decrease in myocardial contractility. As contractility worsens, all chambers of the heart progressively dilate and the walls become increasingly stiff as intracardiac pressure rises. The net result is reduced cardiac output, which causes a decrease in muscle perfusion. As the disease progresses, the left ventricle continues to dilate, causing the mitral valve annulus to widen; cardiac output is further reduced as a result of mitral regurgitation. The reduced cardiac output stimulates the sympathetic nervous system to increase preload (diastolic volume), heart rate, and peripheral vascular resistance. Consequently, there is an increase in volume and pressure, and clinically, it is at this stage of the disease that most animals develop pulmonary edema.

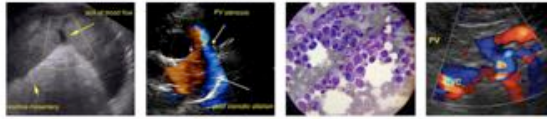
Although the most common etiology is idiopathic, it can also be the result of hypothyroidism, taurine deficiency, L-carnitine deficiency, parvovirus, Lyme disease, and possibly myocarditis. In Doberman Pinschers there is some evidence that there may be a causative genetic mutation. Doxorubicin chemotherapy may induce a DCM-type presentation due to its myocardial toxicity. In Boxers, it is possible for primary myocarditis to precipitate DCM in the later stages of the condition. Hypothyroidism may also be a complicating factor in DCM as it has the potential to further aggravate the systolic dysfunction.

**Clinical signs:** Clinical signs include weakness, lethargy, exercise intolerance, coughing, anorexia, ascites, syncope, tachypnea, and dyspnea. Pulses are weak and rapid, and often there are pulse deficits. Pulmonary crackles may be auscultated. Jugular distention and muffled heart sounds may also be present.

**Diagnostics:** It is possible that NT-proBNP testing will be utilized in the future to detect occult DCM. One recent study showed that NT-proBNP levels were higher in dogs with DCM as well as apparently healthy patients that went on to develop DCM within 1.5 years of the samples being obtained.

The echocardiographic parameters for diagnosing DCM include an increased left ventricular (LV) diameter, depressed fractional shortening, and increased EPSS (> 0.8 cm); there is the possibility of an enlarged left atrium. A recent study showed that the best discriminating value for differentiating healthy Doberman Pinschers from those with DCM was the LV diastolic diameter (> 48mm for male dogs and > 46 mm for female dogs).

Ideally, an ECG should be performed with a Holter monitor over a 24-hour period. Fifty to 100 VPCs are considered diagnostic for DCM in Doberman Pinschers when other systemic causes for arrhythmias have



**PATIENT**

Caroline Stephens

been excluded. The absence of detectable VPCs in the 5-minute ECG, however, should not lead to the assumption that the dog is healthy. Even one VPC in a 5-minute ECG strongly warrants further examination.

**SPECIES**

Canine

When congestive heart failure (CHF) develops, patients will exhibit an increased respiratory rate and there will be evidence of pulmonary edema on survey radiographs. One might also note elevated NT-proBNP levels.

**BREED**

Labrador

**Treatment:** Pimobendan (0.25-0.3 mg/kg PO BID) is a phosphodiesterase inhibitor and positive inotropic medication. (Note: The latter is a more powerful positive inotrope than digoxin.) Studies have shown that pimobendan significantly prolongs survivability in Dobermans with DCM and CHF; their mean survival time was 329 days compared to 50 days for those in the placebo group. There was also clinical improvement in dogs that had CHF.

**SEX**

Spayed Female

**AGE**

6/25/14

**Diuretics:** Lasix should be administered at 2-4 mg/kg PO BID-TID as needed and subsequently reduced to the lowest tolerated dose to maintain respiratory comfort, which is approximately 2 mg/kg PO BID (higher doses will be required as the disease progresses). Spironolactone (0.5 mg/kg PO BID) is used primarily for its anti-aldosterone effect and to decrease remodeling of the heart. In human trials, the addition of spironolactone to standard therapy has been shown to increase life span in cases of CHF.

**WEIGHT**

37.5 kg

**Angiotensin-converting enzyme (ACE) inhibitors:** Enalapril (0.5 mg/kg BID) or benazepril (0.5 mg/kg PO Q12-24hr) therapy decreases systemic afterload, which diminishes the chamber stretching effects on the myocardium and thereby improves oxygen carrying capacity. A recent retrospective study showed that the early use of benazepril prolonged the onset of overt DCM in Dobermans with occult DCM.

**INTERPRETED BY**

Eric Lindquist, DMV,  
DABVP, Cert. IVUSS,  
CEO of SonoPath.com

**Anti-arrhythmics:** These should be used as needed. In cases of ventricular tachycardia where severe systolic dysfunction is a possibility, amiodarone (10 mg/kg PO Q24hr until stabilized and then 8 mg/kg PO Q24hr) and mexilitine (5-8 mg/kg PO TID) can be used. Although beta blockers, such as sotalol, can be used, they must be prescribed with extreme caution in dogs with severe systolic dysfunction as they have a decreased inotropic effect. Therapy for atrial fibrillation would include diltiazem (start at 0.5 mg/kg PO TID and increase to a target dose of 2 mg/kg PO TID) and/or digoxin, or amiodarone.

**IMAGING PERFORMED BY**

Andrea Nicastro, DVM,  
Diplomate ACVIM  
(Small Animal Internal  
Medicine)

**HOSPITAL NAME**

Veterinary Specialty  
Care Blue Pearl

**REFERRING VET**

Dr. Graham

**Carvedilol:** Carvedilol is a calcium channel blocker, acts as a positive inotrope and free radical scavenger, and has ACE inhibiting effects. The target dose is approximately 1 mg/kg BID; it should be titrated up gradually from 0.25 mg/kg with dose adjustments made every 2 weeks until the ideal dose is reached.

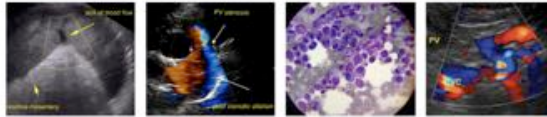
**INVOICE**

30874

**Morphine:** Morphine (0.025-0.05 mg/kg IV) decreases anxiety and improves respiratory efficiency and oxygen consumption. Morphine also dilates splanchnic vasculature and increases venous capacitance thereby reducing pulmonary edema.

**DATE**

6/7/22



**PATIENT**

Caroline Stephens

**SPECIES**

Canine

**BREED**

Labrador

**SEX**

Spayed Female

**AGE**

6/25/14

**WEIGHT**

37.5 kg

**INTERPRETED BY**

Eric Lindquist, DMV,  
DABVP, Cert. IVUSS,  
CEO of SonoPath.com

**IMAGING  
PERFORMED BY**

Andrea Nicastro, DVM,  
Diplomate ACVIM  
(Small Animal Internal  
Medicine)

**HOSPITAL NAME**

Veterinary Specialty  
Care Blue Pearl

**REFERRING VET**

Dr. Graham

**INVOICE**

30874

**DATE**

6/7/22

**Supplements:** These may aid in some cases of DCM. In taurine-deficient patients (based on plasma or whole blood taurine levels), one should supplement taurine at 500 mg PO BID and L-carnitine at 175 mg/kg PO BID. Coenzyme Q10 is also used as a means of myocardial ischemic prevention (30-90mg BID). Omega-3 fatty acid supplements can help with cell membrane stabilization and be used as inflammatory mediators (EPA 40mg/kg, DHA 25mg/kg PO Q24hr).

**Salt restriction:** An optimized high-quality protein diet (4gm/100kcal) that is mildly restricted in salt should be considered to minimize the onset of sodium-induced volume overloads.

**Monitoring:** Serum chemistry (i.e., BUN/creatinine, electrolytes), blood pressure, and thoracic radiographs should be performed as needed 5-7 days after therapy has been initiated. One should conduct a follow-up echocardiogram in 1-6 months to assess myocardial function and the possible progression of the systolic dysfunction; medication should be changed or modified as needed. An electrocardiogram should be repeated as needed to monitor arrhythmias and the patient's response to therapy. The best means of monitoring progress at home is to observe the resting respiratory rate. A study showed that the resting respiratory rate obtained at home was the strongest predictor of improving or worsening of CHF and/or pulmonary edema.

**Prognosis:** The prognosis is variable and largely dependent on the individual animal and its response to therapy.

**References:**

Fuentes VL, Corcoran B, French A, Schober KE, Kleemann R, Justus C. A double-blind, randomized, placebo-controlled study of pimobendan in dogs with dilated cardiomyopathy. *J Vet Intern Med.* 2002;16:255-261.

O'Grady MR, Minors SL, O'Sullivan ML, et al. Effect of pimobendan on case fatality rate in Doberman Pinschers with congestive heart failure caused by dilated cardiomyopathy. *J Vet Intern Med* 2008;22:897-904.

O'Grady MR, O'Sullivan ML, Minors SL, et al. Efficacy of benazepril hydrochloride to delay the progression of occult dilated cardiomyopathy in Doberman Pinschers. *J Vet Intern Med* 2009;23:977-83.

O'Grady MR, O'Sullivan ML, Pyle WG, et al. Evaluation of 10 genes encoding cardiac proteins in Doberman Pinschers with dilated cardiomyopathy. *Am J Vet Res* 2011;72:932-39.

Wess G, Butz V, Mahling M, et al. Evaluation of N-terminal pro-B-type natriuretic peptide as a diagnostic marker of various stages of cardiomyopathy in Doberman Pinschers. *Am J Vet Res* 2011;72:642-49.