

**PATIENT PRESENTING CLINICAL SIGNS**

Gizmo Webster Pt presented for consult - CHF & poss mass cranial abd. No mass noted, rec u/s. Meds: vetmedin 2.5mg BID, furoseimide 25mg BID, enalapril 5mg BID  
**SPECIES** Abnormal PE/Chem/CBC/UA Results: 4/6 murmur No BP

Canine

**ULTRASONOGRAPHIC EXAMINATION OF THE HEART**

**BREED**

Chihuahua

**SEX**

Neutered male

**AGE**

7 yrs

**WEIGHT**

25.1 lbs

The echocardiogram in this patient demonstrated normal **left atrial** size based on 3 different LA measurement methods. Chamber volumes and echogenicity were normal. The cranial and caudal **mitral** valve leaflets presented vegetative thickening consistent with endocardiosis. Doppler indicated measurable insufficiency. The **left ventricle** presented thicknesses with linear contour and was not dilated nor restricted. The **myocardium** presented normal echogenicity without subjective evidence of significant fibrotic or ischemic disease. **Contractility** of the ventricular walls was adequate and in normal range for this patient evidenced by the fractional shortening measurement and subjective evaluation of the different regions of the myocardium. The **left ventricular outflow** tract demonstrated normal laminar flow and subjective structural integrity. The **right atrium** and auricle revealed normal size, structure and content. No evidence of masses was noted or chamber overload. **Tricuspid** valvular assessment demonstrated adequate linear morphology. The **right ventricle** was of normal size (1/3 diameter of LV), chordae structure, myocardial echogenicity and thickness. **Pulmonic** tract assessment revealed normal valve structure, laminar flow, and diameter (approx.1:1 pa/ao ratio). No visible **pericardial** or free pleura fluid was noted. No echographically detectable evidence of infiltrative disease was visible. The cranial **mediastinum and pericardial regions** were free of masses in the visible window.

**INTERPRETED BY**

Eric Lindquist, DMV,  
DABVP, Cert. IVUSS,  
CEO of SonoPath.com

**IMAGING PERFORMED BY**

Andrea Nicastro, DVM,  
Diplomate ACVIM  
(Small Animal Internal  
Medicine)

**HOSPITAL NAME**

Southside AH-

**REFERRING VET**

Dr. Sauls

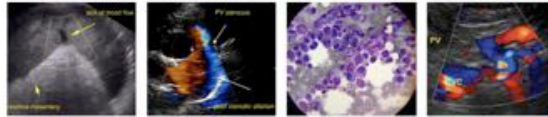
**INVOICE**

30196

**DATE**

5/9/22

CANINE CARDIAC PARAMETERS	MR VMAX (m/s)	TR VMAX (m/s)	LA/AO (Boon method)	LA/AO (Heart Base; Swe)	FS (%)	EF (%)	EPSS (cm)
NORMAL PARAMETER	4.5-5.5	<2.7	1.3	<1.3	28-40	40-100	<0.6
PATIENT	6.0		1.15	1.1	50	90	0.1
CANINE CARDIAC PARAMETERS	HR (BPM)	AV VMAX (m/s)	PV MAX (m/s)	BODY WEIGHT	LA 2D short axis Base view (cm)	LVIDd Avg; 2D and m- mode short axis (cm)	LVIDs Avg; 2D and m- mode short axis (cm)
NORMAL PARAMETER	50-100	0.7-1.7	0.7-1.6				
PATIENT		1.3	1.1	25.1 lbs	2.8	3.1	



**PATIENT      ULTRASONOGRAPHIC FINDINGS**

Gizmo Webster      Mitral valve disease.

**SPECIES**

Canine

**BREED**

Chihuahua

**SEX**

Neutered male

**AGE**

7 yrs

**WEIGHT**

25.1 lbs

**INTERPRETED BY**

Eric Lindquist, DMV,  
DABVP, Cert. IVUSS,  
CEO of SonoPath.com

**IMAGING PERFORMED BY**

Andrea Nicastro, DVM,  
Diplomate ACVIM  
(Small Animal Internal  
Medicine)

**HOSPITAL NAME**

Southside AH-

**REFERRING VET**

Dr. Sauls

**INVOICE**

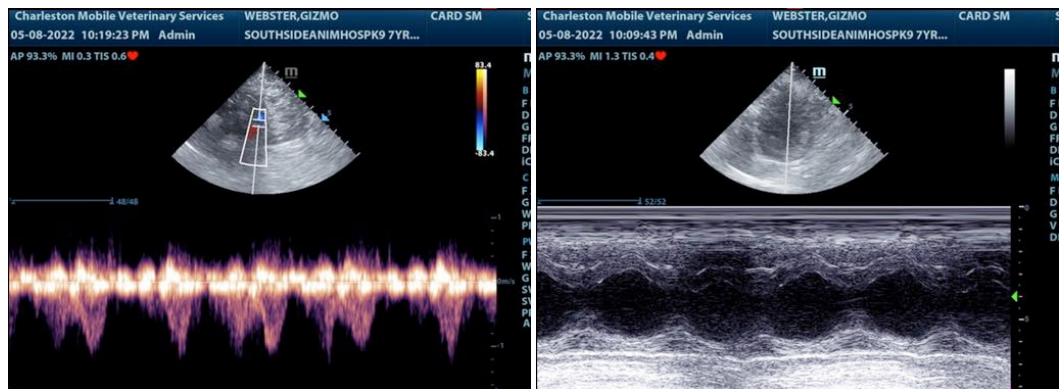
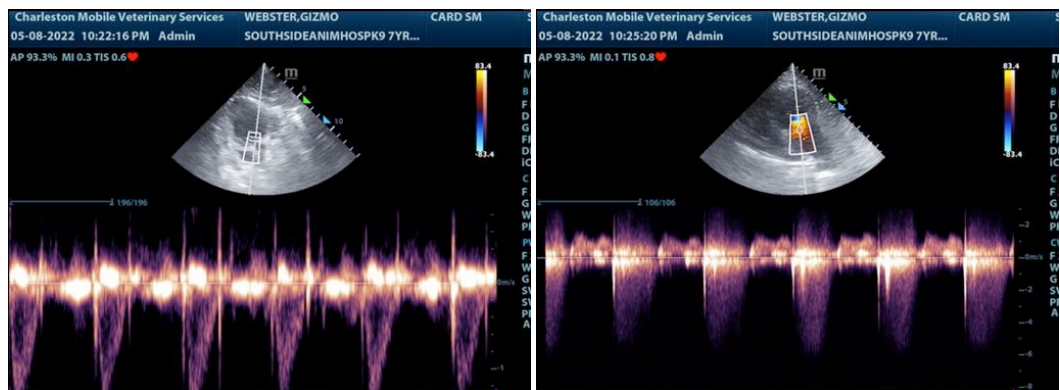
30196

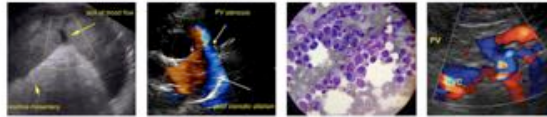
**DATE**

5/9/22

**INTERPRETATION OF THE FINDINGS & FURTHER RECOMMENDATIONS**

B1: The heart is stable without clinical disease. No overt contraindication for anesthesia of brief to moderate duration. I suggest Torbutrol premed, Propofol induction, Isoflurane maintenance or similar protocol if anesthesia is desired. Blood pressure recommended if not already performed and target white coat negative systolic pressure of < 160 mmHg. If higher than this ACE-inhibitor is suggested to reach this level. Recheck echocardiogram is recommended in 6 months, earlier if murmur grade increases or clinical signs initiate.





**PATIENT**

Gizmo Webster

**SPECIES**

Canine

**BREED**

Chihuahua

**SEX**

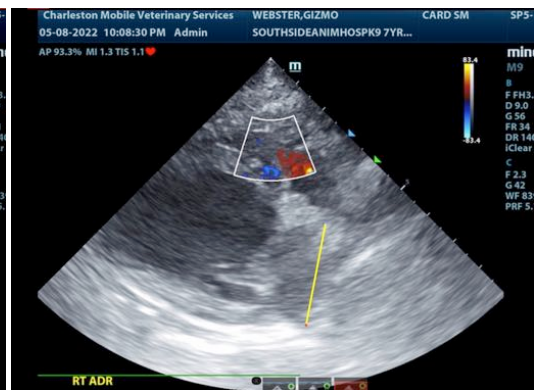
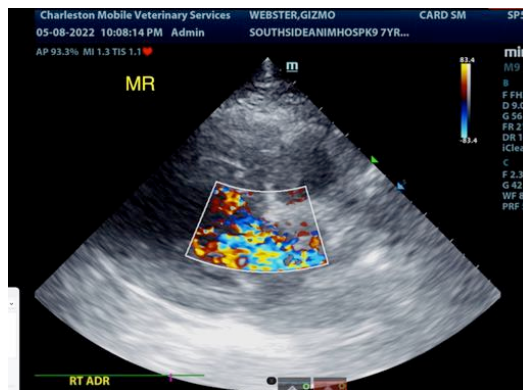
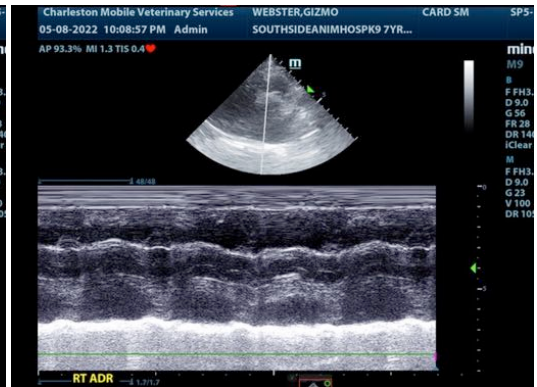
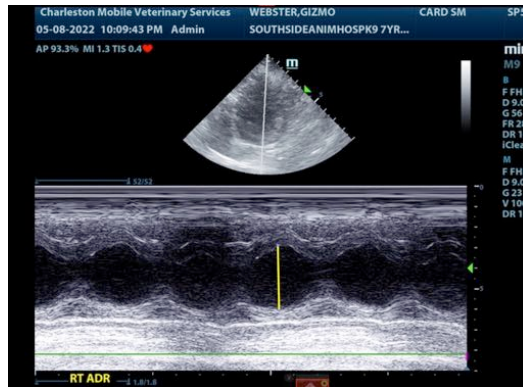
Neutered male

**AGE**

7 yrs

**WEIGHT**

25.1 lbs



**INTERPRETED BY**

Eric Lindquist, DMV,  
DABVP, Cert. IVUSS,  
CEO of SonoPath.com

The information and recommendations provided are based on the images presented by the referring veterinarian. No evaluation can be communicated regarding pathology that was not visible in the image/video clips provided.

Thank you for this referral. If the clinical or image interpretation does not parallel your findings or if I can be of any further assistance please contact me.

**IMAGING PERFORMED BY**

Andrea Nicastro, DVM,  
Diplomate ACVIM  
(Small Animal Internal  
Medicine)

Eric Lindquist, DMV, DABVP, Cert. IVUSS, CEO of SonoPath.com

Info@SonoPath.com

**HOSPITAL NAME**

Southside AH-

**REFERRING VET**

Dr. Sauls

**INVOICE**

30196

**DATE**

5/9/22