

PATIENT

Mittens 59914538

SPECIES

Feline

BREED

Domestic Shorthair

SEX

Spayed female

AGE

2 years

WEIGHT

7.1 lbs

INTERPRETED BY

Eric Lindquist, DMV
DABVP, Cert. IVUSS

**IMAGING
PERFORMED BY**

Greg Shaffer

HOSPITAL NAME

Saint Frances AC

REFERRING VET

Dr. O'Sullivan

INVOICE

70164

DATE

1/14/26

PRESENTING CLINICAL SIGNS

History: Post op OHE

ULTRASONOGRAPHIC EXAMINATION OF THE ABDOMEN

Urinary System

The **urinary bladder**, trigone, and pelvic urethra presented normal thicknesses and normal tone. The pelvic urethra was imaged 1.0 cm beyond the cystourethral junction and appeared normal. The ureters were not visible which is normal. No uroliths or sediment were visualized and anechoic urine was present. No evidence of inflammatory or neoplastic changes was noted. Ureteral papillae were normal.

The **kidneys** revealed normal size and structure, corticomedullary definition and ratio for this age. The cortices presented largely uniform texture with normal echogenic relationship to liver and spleen. Medullary structure differed distinctly from the cortex and no evidence of pelvic dilation was present. The capsules were acceptably uniform without significant irregularities. The right kidney measured 3.67 cm. The left kidney measured 3.53 cm.

Adrenal Glands

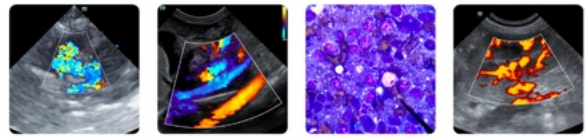
Both **adrenal glands** were visualized and recognized as having normal shape, size, position and echogenicity for this breed. The phrenic vasculature, glandular echogenicity and detail were unremarkable. Capsule, cortex, and medullary definition were normal for this age patient. The right adrenal gland measured 0.28 cm. The left adrenal gland measured 0.29 cm.

Spleen

The **spleen** presented a smooth homogeneous parenchyma hyperechoic to liver and renal cortical parenchyma. The capsule was smooth without noticeable expansion or deviation from within the spleen or adjacent pathology. The splenic vasculature demonstrated normal volume without signs of congestion or thrombosis. No sonographic evidence of acute or chronic inflammatory, neoplastic, or infarctual changes was noted.

Liver

The **liver** images submitted revealed subjectively normal liver size, contour, and structure. Parenchymal echogenicity was naturally coarse and hypoechoic to the spleen. Vascular and biliary tracts were of normal volume with no evidence of congestion. The gallbladder presented acceptably thin walls with primarily anechoic content. The cystic and common bile ducts were normal. No pathological hepatic lymphadenopathy was evident. No overt structural evidence of inflammatory, infiltrative or regenerative pathology was evident.



PATIENT

Mittens 59914538

SPECIES

Feline

BREED

Domestic Shorthair

SEX

Spayed female

AGE

2 years

WEIGHT

7.1 lbs

INTERPRETED BY

Eric Lindquist, DMV
 DABVP, Cert. IVUSS

IMAGING PERFORMED BY

Greg Shaffer

HOSPITAL NAME

Saint Frances AC

REFERRING VET

Dr. O'Sullivan

INVOICE

70164

DATE

1/14/26

Gastrointestinal

A minor amount of non-shadowing, non-obstructive hairball density was noted in the stomach. Transit of chyme into the small intestine was normal. Curvilinear patterns were maintained throughout the GI tract. No evidence of pathology. Small and large intestine demonstrated normal luminal chyme and stool consistency respectively. No obstructive or overt infiltrative disease was noted. The mesenteric lymph nodes were reactive and measured up to 1.0 x 0.5 cm.

Pancreas

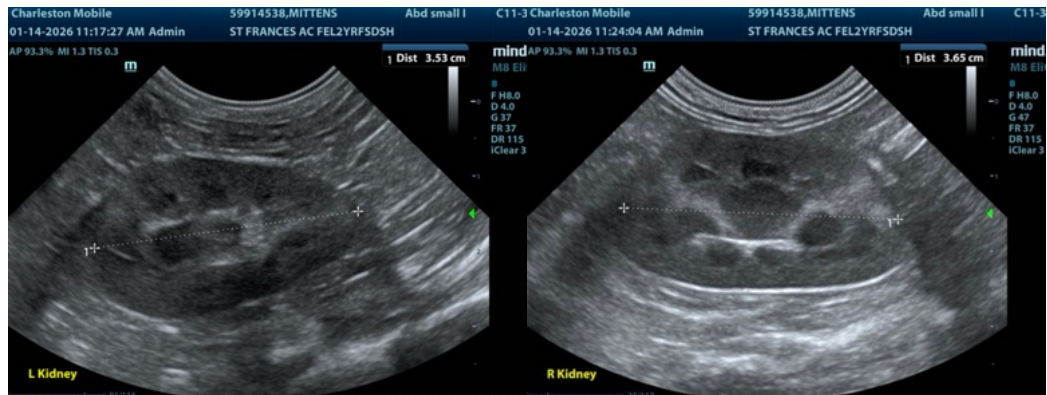
The base and limbs of the **pancreas** were observed to be largely isoechoic to surrounding omental fat. Pancreatic duct and capsular contour were acceptably normal and parenchyma respected normal curvilinear patterns. No overt evidence of active inflammatory or neoplastic disease was noted.

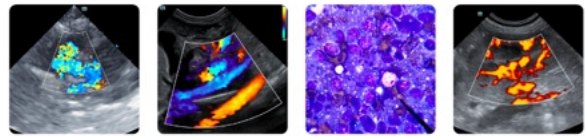
ULTRASONOGRAPHIC FINDINGS

Structurally unremarkable abdomen with hairball density in the stomach.

INTERPRETATION OF THE FINDINGS & FURTHER RECOMMENDATIONS

Medical management for Trichobezoar is recommended.





PATIENT

Mittens 59914538

SPECIES

Feline

BREED

Domestic Shorthair

SEX

Spayed female

AGE

2 years

WEIGHT

7.1 lbs

INTERPRETED BY

Eric Lindquist, DMV
 DABVP, Cert. IVUSS

IMAGING PERFORMED BY

Greg Shaffer

HOSPITAL NAME

Saint Frances AC

REFERRING VET

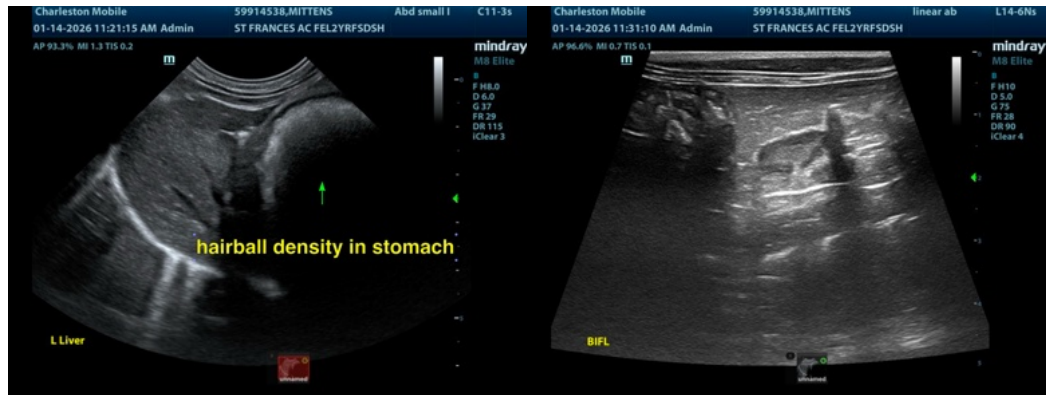
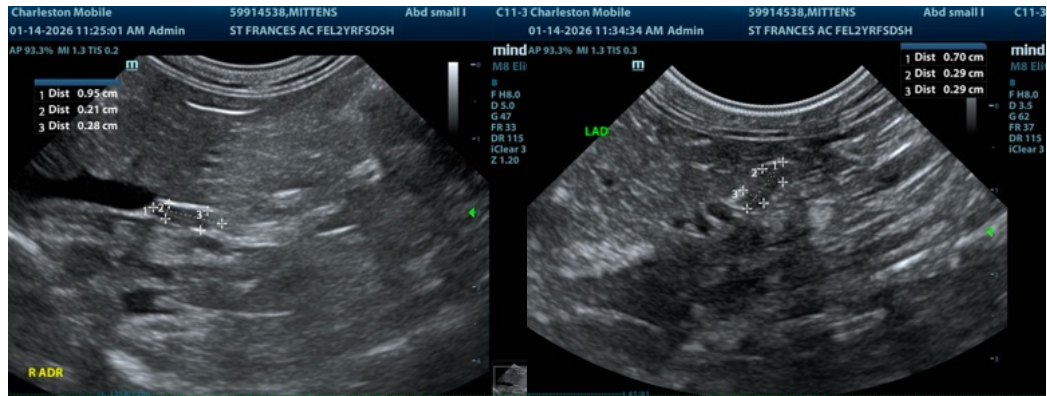
Dr. O'Sullivan

INVOICE

70164

DATE

1/14/26



The information and recommendations provided are based on the images presented by the referring veterinarian/sonographer. No evaluation can be communicated regarding pathology that was not visible in the image/video clips provided.

Thank you for this referral. If the clinical or image interpretation does not parallel your findings or if I can be of any further assistance please contact me.

Eric Lindquist, DMV, DABVP, Cert. IVUSS, CEO of SonoPath.com

info@SonoPath.com