



PATIENT

Mister Bean Bartels

SPECIES

Feline

BREED

Persian

SEX

Intact male

AGE

8 months

WEIGHT

7 lbs

INTERPRETED BY

Eric Lindquist, DMV,
DABVP, Cert. IVUSS

IMAGING PERFORMED BY

Jenna Walsh, CVT

HOSPITAL NAME

VCA Delta Oaks AH

REFERRING VET

Dr. Schulke

DATE

9/9/22

Invoice

32826

PRESENTING CLINICAL SIGNS

History: - no Left testes in scrotum and not palpable in inguinal area Primary Question/Differential to Be Answered in This Exam Want to neuter, and would like to determine the location of the undescended Left testicle (abdomen or inguinal)

ULTRASONOGRAPHIC EXAMINATION OF THE ABDOMEN

Urinary System

The **urinary bladder**, trigone, and pelvic urethra presented normal thicknesses and normal tone. The ureters were not visible which is normal. No uroliths or sediment were visualized and anechoic urine was present. No evidence of inflammatory or neoplastic changes was noted. Ureteral papillae were normal.

The **kidneys** revealed normal size and structure, corticomedullary definition and ratio for this age. The cortices presented largely uniform texture with normal echogenic relationship to liver and spleen. Medullary structure differed distinctly from the cortex and no evidence of pelvic dilation was present. The capsules were acceptably uniform without significant irregularities.

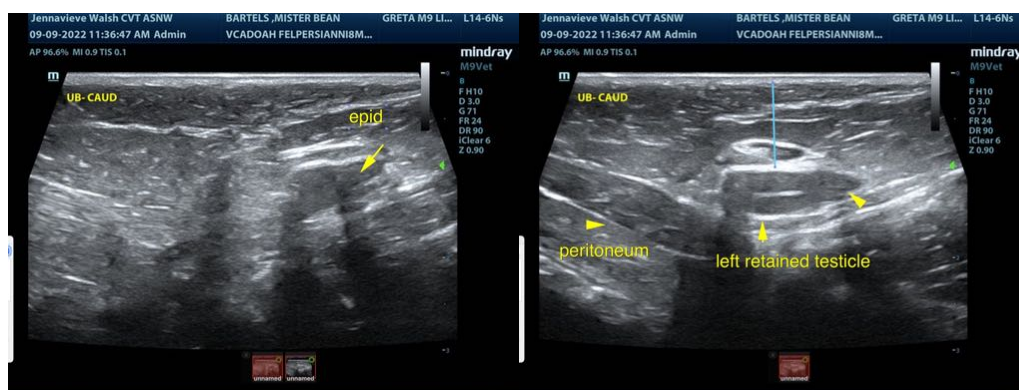
The iliac lymph nodes were unremarkable. The left inguinal area just caudal to the abdominal wall and inguinal ring revealed the left retained testicle. The testicle was approximately 1.0 cm deep from the dermis. Both median raffe and epididymis were identified.

ULTRASONOGRAPHIC FINDINGS

Extra abdominal left inguinal retained testicle.

INTERPRETATION OF THE FINDINGS & FURTHER RECOMMENDATIONS

Inguinal dermal incision is recommended.





PATIENT

Mister Bean Bartels

SPECIES

Feline

BREED

Persian

SEX

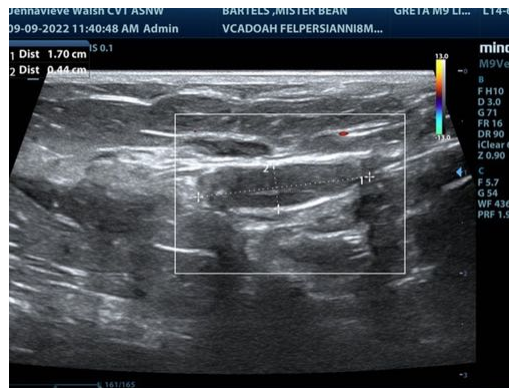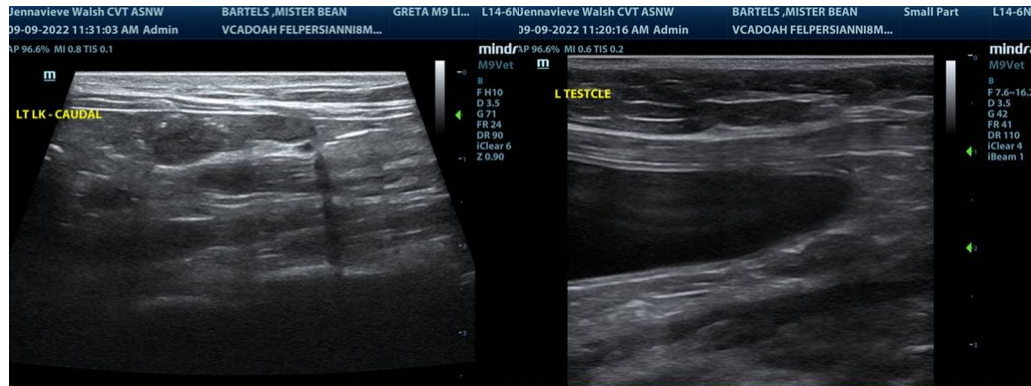
Intact male

AGE

8 months

WEIGHT

7 lbs



INTERPRETED BY

Eric Lindquist, DMV,
DABVP, Cert. IVUSS

The information and recommendations provided are based on the images presented by the referring veterinarian/sonographer. No evaluation can be communicated regarding pathology that was not visible in the image/video clips provided.

IMAGING PERFORMED BY

Jenna Walsh, CVT

Thank you for this referral. If the clinical or image interpretation does not parallel your findings or if I can be of any further assistance please contact me.

HOSPITAL NAME

VCA Delta Oaks AH

Eric Lindquist, DMV, DABVP, Cert. IVUSS

CEO of Sonopath.com

Eric.Lindquist@SonoPath.com

REFERRING VET

Dr. Schulke

DATE

9/9/22

Invoice

32826