



PATIENT

Mister Wags Murray

SPECIES

Canine

BREED

Lhasa Apso

SEX

Neutered male

AGE

12 years

WEIGHT

28 lbs

PRESENTING CLINICAL SIGNS

History: Labored breathing after walk, not wanting to go on longer walks. Grade 3/4 murmur heard both sides, stronger on left

ULTRASONOGRAPHIC EXAMINATION OF THE HEART

The echocardiogram in this patient demonstrated normal **left atrial** size based on 3 different LA measurement methods. Chamber volumes and echogenicity were normal. The cranial and caudal **mitral** valve leaflets presented vegetative thickening consistent with endocardiosis. The mitral insufficiency jet was eccentrically directed. Doppler indicated measurable insufficiency. The **left ventricle** presented thicknesses with linear contour and was not dilated nor restricted. The **myocardium** presented normal echogenicity without subjective evidence of significant fibrotic or ischemic disease. **Contractility** of the ventricular walls was adequate and in normal range for this patient evidenced by the fractional shortening measurement and subjective evaluation of the different regions of the myocardium. The **left ventricular outflow** tract demonstrated normal laminar flow and subjective structural integrity. The **right atrium** and auricle revealed normal size, structure and content. No evidence of masses was noted or chamber overload. **Tricuspid** valvular assessment demonstrated adequate linear morphology. The **right ventricle** was of normal size (1/3 diameter of LV), chordae structure, myocardial echogenicity and thickness. **Pulmonic** tract assessment revealed normal valve structure, laminar flow, and diameter (approx.1:1 pa/ao ratio). No visible **pericardial** or free pleura fluid was noted. No echographically detectable evidence of infiltrative disease was visible. The cranial **mediastinum and pericardial regions** were free of masses in the visible window.

INTERPRETED BY

Eric Lindquist, DMV,
DABVP, Cert. IVUSS

IMAGING PERFORMED BY

Jenna Walsh, CVT

HOSPITAL NAME

Pawsite Wellness VC

REFERRING VET

Dr. Hardy

DATE

9/29/21

Invoice
92072

CANINE CARDIAC PARAMETERS	MR VMAX (m/s)	TR VMAX (m/s)	LA/AO (Boon method)	LA/AO (Heart Base; Swe)	FS (%)	EF (%)	EPSS (cm)
NORMAL PARAMETER	4.5-5.5	<2.7	1.3	<1.6	28-40	40-100	<0.6
PATIENT	6.0	1.77	1.2	1.11	51	85	0.26
CANINE CARDIAC PARAMETERS	HR (BPM)	AV VMAX (m/s)	PV MAX (m/s)	BODY WEIGHT	LA 2D short axis Base view (cm)	LVIDd Avg; 2D and m- mode short axis (cm)	LVIDs Avg; 2D and m- mode short axis (cm)
NORMAL PARAMETER	50-100	0.7-1.7	0.7-1.6				
PATIENT	143	1.35	0.79	28 lbs	3.07 max	2.31	



PATIENT

Mister Wags Murray

SPECIES

Canine

BREED

Lhasa Apso

SEX

Neutered male

AGE

12 years

WEIGHT

28 lbs

INTERPRETED BY

Eric Lindquist, DMV,
DABVP, Cert. IVUSS

IMAGING PERFORMED BY

Jenna Walsh, CVT

HOSPITAL NAME

Pawsite Wellness VC

REFERRING VET

Dr. Hardy

DATE

9/29/21

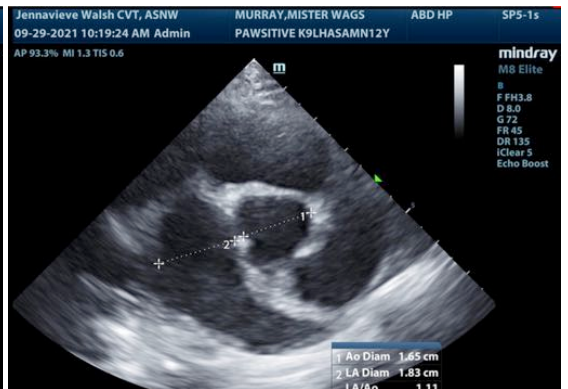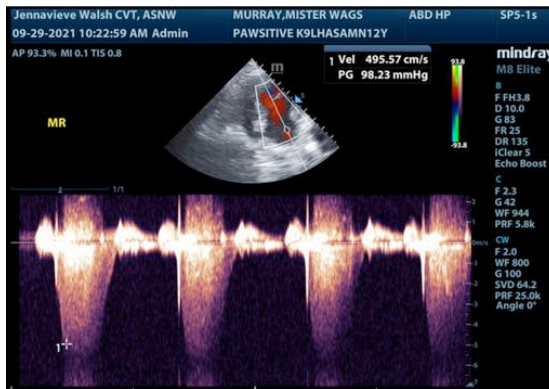
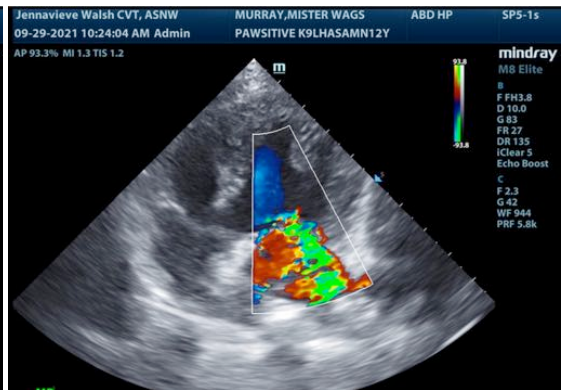
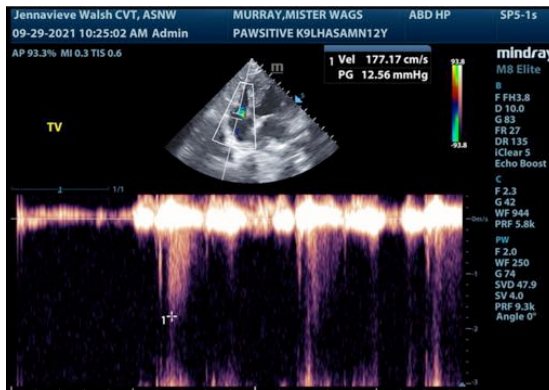
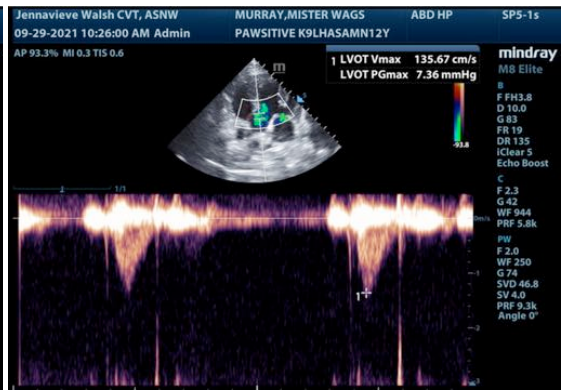
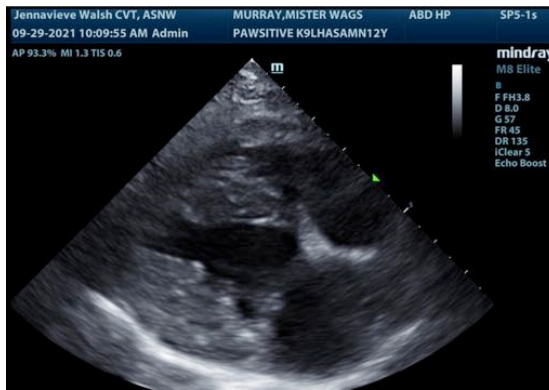
Invoice
92072

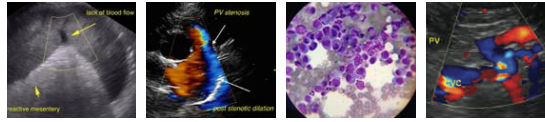
ULTRASONOGRAPHIC FINDINGS

Stage B1 valvular disease. No volume overload.

INTERPRETATION OF THE FINDINGS & FURTHER RECOMMENDATIONS

There is no overt contraindication to short anesthetic procedure if necessary. Blood pressure measurements are warranted. A recheck echocardiogram is recommended in 6 months or earlier if murmur grade increases or clinical signs initiate.





PATIENT
Mister Wags Murray

SPECIES
Canine

BREED
Lhasa Apso

SEX
Neutered male

AGE
12 years

WEIGHT
28 lbs

INTERPRETED BY
Eric Lindquist, DMV,
DABVP, Cert. IVUSS

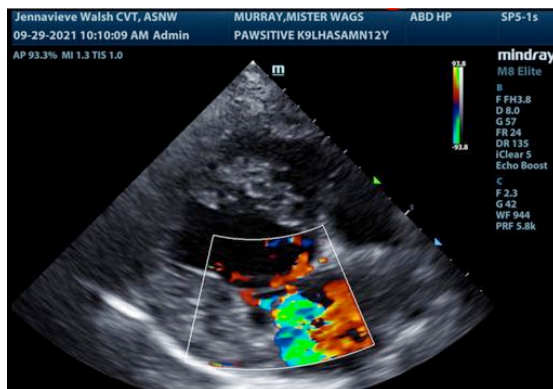
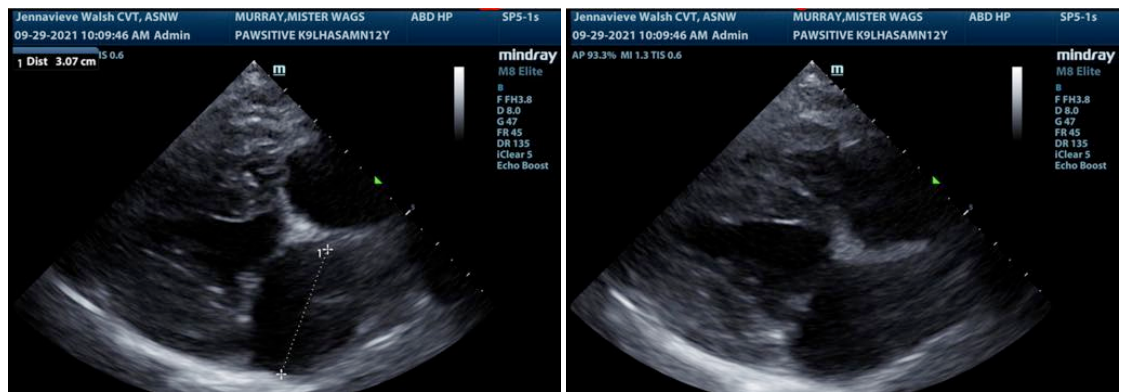
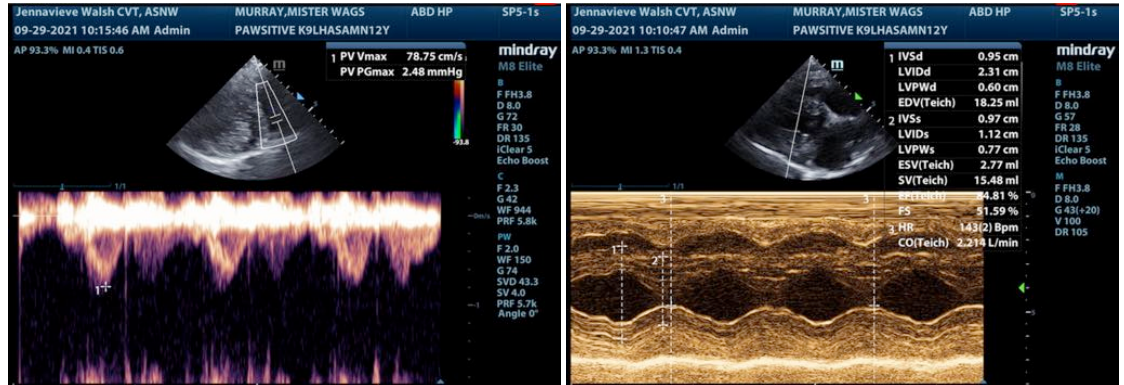
IMAGING PERFORMED BY
Jenna Walsh, CVT

HOSPITAL NAME
Pawsite Wellness VC

REFERRING VET
Dr. Hardy

DATE
9/29/21

Invoice
92072



The information and recommendations provided are based on the images presented by the referring veterinarian. No evaluation can be communicated regarding pathology that was not visible in the image/video clips provided.

Thank you for this referral. If the clinical or image interpretation does not parallel your findings or if I can be of any further assistance please contact me.

Eric Lindquist, DMV, DABVP, Cert. IVUSS
CEO of Sonopath.com



PATIENT

Eric.Lindquist@SonoPath.com

Mister Wags Murray

SPECIES

Canine

BREED

Lhasa Apso

SEX

Neutered male

AGE

12 years

WEIGHT

28 lbs

INTERPRETED BY

Eric Lindquist, DMV,
DABVP, Cert. IVUSS

**IMAGING
PERFORMED BY**

Jenna Walsh, CVT

HOSPITAL NAME

Pawsite Wellness VC

REFERRING VET

Dr. Hardy

DATE

9/29/21

Invoice
92072