



PATIENT

Silas Cat Rescue
Adoption Network

SPECIES

Feline

BREED

Domestic Shorthair

SEX

Neutered male

AGE

12 years

WEIGHT

14.9 lbs

INTERPRETED BY

Eric Lindquist, DMV,
DABVP, Cert. IVUSS

IMAGING PERFORMED BY

Jenna Walsh, CVT

HOSPITAL NAME

Four Corners VC

REFERRING VET

Dr. Williams

PRESENTING CLINICAL SIGNS

History: P was noted to have a grade 4/6 murmur last spring. This pet has had 2 anesthetic procedures successfully in the last 6 months but the rescue group would like to know the cause of the cardiac murmur and if he needs to be on medication for the rest of his life.

ULTRASONOGRAPHIC EXAMINATION OF THE ABDOMEN

The echocardiogram in this patient demonstrated normal **left atrial** size and structure with no evidence of “smoke” or thrombi. **Mitral** valve insufficiency was noted. The mitral valve was thickened and vegetative. Minor systolic anterior motion was present. The ventricular septum in this patient appeared to have dropout. I am concerned for underlying ventricular septal defect. Furtehr imaging would be necessary to confirm. Sectorial hypertrophy was noted in this patient. Depending on where measurements are taken variability of the septal and free wall thicknesses will occur. The **left ventricular outflow** tract demonstrated turbulent laminar flow. Subjective assessment of the **right atrium** and auricle revealed normal size, structure and content. No evidence of masses was noted. **Tricuspid** valvular assessment demonstrated linear morphology. The **right ventricle** was of normal size with normal chordae structure, myocardial echogenicity and thickness. **Pulmonic** tract assessment revealed normal valve structure, laminar flow, and diameter. No visible **pericardial** or free pleura fluid was noted. No echographically detectable evidence of infiltrative disease was visible. The **mediastinum** was free of masses in the visible window.

FELINE CARDIAC PARAMETERS	BODY WEIGHT (kg)	HR (BPM)	IVSd (cm)	LVIDd (cm)	LVWd (cm)	FS (%)	EF (%)
NORMAL PARAMETER	-----	150-240	0.3-0.6	1.0-2.1	0.25-0.6	35-67	80-100
PATIENT		187	0.65	1.52	0.76	49	83
FELINE CARDIAC PARAMETERS	LA/AO (Boon)	LA/AO HEART BASE (Sisson)	LA 2D 4-chamber long axis AS to FW (Sisson) (cm)	LVOT VEL. (m/s)	RVOT VEL. (m/s)	IVRT (m/)	
NORMAL PARAMETER	<1.5	0.88-1.79	0.7-1.7	<1.6	<1.3	40-60	
PATIENT	1.73	1.74		2.2	1.0	NM	
Adapted from June Boon, Veterinary Echocardiography, 1998 Sisson D et al. JVIM 1991; 5: 232, Jacobs et al. Am J Vet Res 1985; 46:1705							

DATE

9/27/21

Invoice

92019

ULTRASONOGRAPHIC FINDINGS

Hypertrophic cardiomyopathy, compensated at this time. Potential concurrent ventricular septal defect.



PATIENT

Silas Cat Rescue
Adoption Network

SPECIES

Feline

BREED

Domestic Shorthair

SEX

Neutered male

AGE

12 years

WEIGHT

14.9 lbs

INTERPRETED BY

Eric Lindquist, DMV,
DABVP, Cert. IVUSS

IMAGING PERFORMED BY

Jenna Walsh, CVT

HOSPITAL NAME

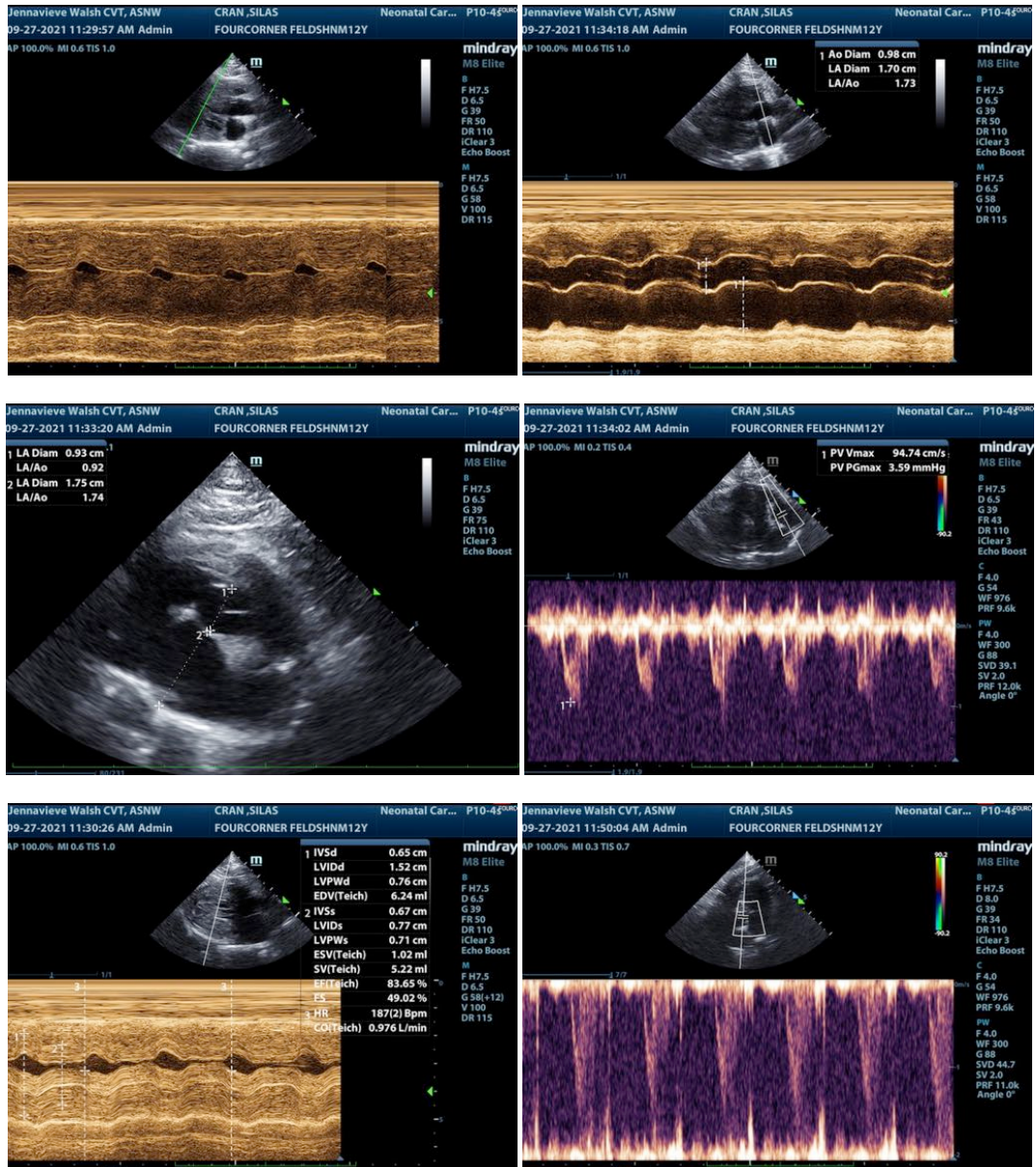
Four Corners VC

REFERRING VET

Dr. Williams

INTERPRETATION OF THE FINDINGS & FURTHER RECOMMENDATIONS

No medications are warranted at this time. A recheck echocardiogram is recommended in 6 months. If any exercise intolerance is present then Atenolol therapy can be considered.

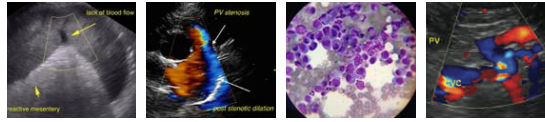


DATE

9/27/21

Invoice

92019



PATIENT

Silas Cat Rescue
Adoption Network

SPECIES

Feline

BREED

Domestic Shorthair

SEX

Neutered male

AGE

12 years

WEIGHT

14.9 lbs

INTERPRETED BY

Eric Lindquist, DMV,
DABVP, Cert. IVUSS

IMAGING PERFORMED BY

Jenna Walsh, CVT

HOSPITAL NAME

Four Corners VC

REFERRING VET

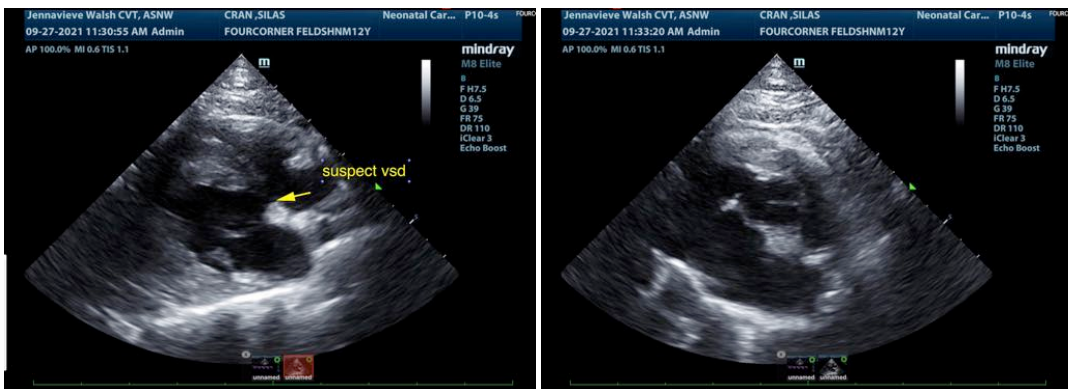
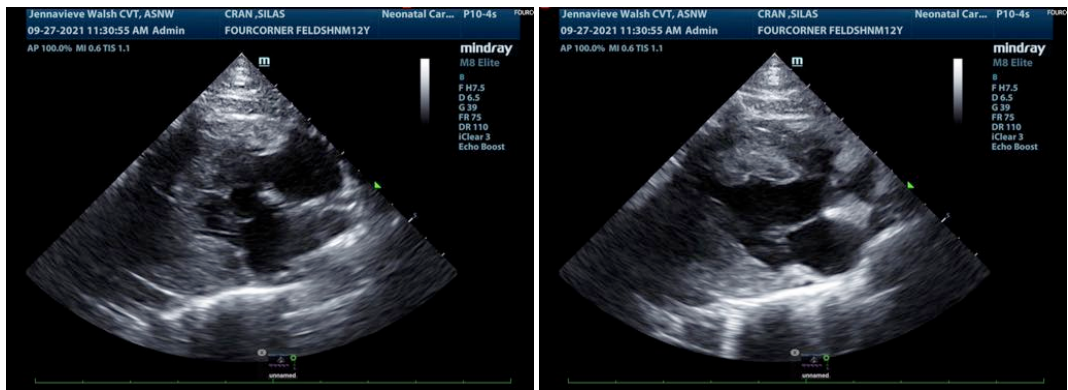
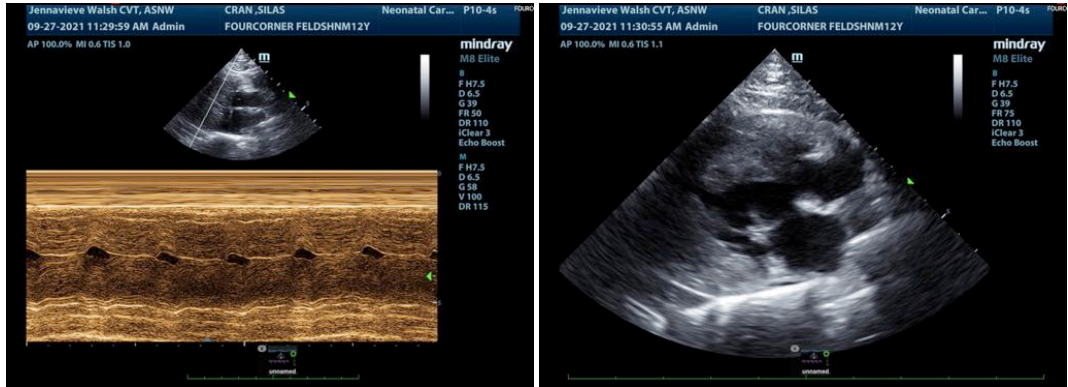
Dr. Williams

DATE

9/27/21

Invoice

92019



The information and recommendations provided are based on the images presented by the referring veterinarian. No evaluation can be communicated regarding pathology that was not visible in the image/video clips provided.

Thank you for this referral. If the clinical or image interpretation does not parallel your findings or if I can be of any further assistance please contact me.

Eric Lindquist, DMV, DABVP, Cert. IVUSS

CEO of SonoPath.com



PATIENT

Eric.Lindquist@SonoPath.com

Silas Cat Rescue
Adoption Network

SPECIES

Feline

BREED

Domestic Shorthair

SEX

Neutered male

AGE

12 years

WEIGHT

14.9 lbs

INTERPRETED BY

Eric Lindquist, DMV,
DABVP, Cert. IVUSS

**IMAGING
PERFORMED BY**

Jenna Walsh, CVT

HOSPITAL NAME

Four Corners VC

REFERRING VET

Dr. Williams

DATE

9/27/21

Invoice

92019