



## PATIENT

Bear Brabham

## SPECIES

Feline

## BREED

Domestic Shorthair

## SEX

Neutered male

## AGE

7 years

## WEIGHT

18 lbs

## INTERPRETED BY

Eric Lindquist, DMV,  
DABVP, Cert. IVUSS

## IMAGING PERFORMED BY

Jenna Walsh, CVT

## HOSPITAL NAME

Albany AH

## REFERRING VET

Dr. Glaze

## DATE

9/10/21

## Invoice

91768

## PRESENTING CLINICAL SIGNS

History: Grade three murmur discovered on routine wellness exam. Systolic heard on left side. Patient is asymptomatic. Patient is also very obese. No other significant physical findings. BP-120 Chem/CBC was WNL. Cardiopet proBNP 149 (0-100)

## ULTRASONOGRAPHIC EXAMINATION OF THE HEART

The echocardiogram in this patient demonstrated normal **left atrial** size based on 3 separate LA measurements. Trivial **mitral** valve insufficiency was noted on spectral Doppler. The **left ventricle** presented normal thicknesses with linear contour and was not dilated nor restricted. The **myocardium** presented normal echogenicity without subjective evidence of significant fibrotic or ischemic disease. **Contractility** of the ventricular walls was adequate and in normal range for this patient evidenced by the fractional shortening measurement and subjective evaluation of the different regions and angles of the myocardium. The **left ventricular outflow** tract demonstrated normal laminar flow and subjective structural integrity. The **right atrium** and auricle revealed normal size, structure and content. No evidence of masses was noted or chamber overload. **Tricuspid** valvular assessment demonstrated adequate linear morphology and kinetics. The **right ventricle** was of normal size (1/3 diameter of LV), chordae structure, myocardial echogenicity and thickness. **Pulmonic** tract assessment revealed normal valve structure, laminar flow, and diameter (approx. 1:1 pa/ao ratio). No visible **pericardial** or free pleura fluid was noted or extra cardiac pathology in the visible planes. The cranial **mediastinum** and **pericardial regions** were free of masses in the visible window.

FELINE CARDIAC PARAMETERS	BODY WEIGHT (kg)	HR (BPM)	IVSd (cm)	LVIDd (cm)	LVWd (cm)	FS (%)	EF (%)
NORMAL PARAMETER	-----	150-240	0.3-0.6	1.0-2.1	0.25-0.6	35-67	80-100
PATIENT		NM	0.5	1.2	0.45	50	
FELINE CARDIAC PARAMETERS	LA/AO (Boon)	LA/AO HEART BASE (Sisson)	LA 2D 4-chamber long axis AS to FW (Sisson) (cm)	LVOT VEL. (m/s)	RVOT VEL. (m/s)	IVRT (m/)	
NORMAL PARAMETER	<1.5	0.88-1.79	0.7-1.7	<1.6	<1.3	40-60	
PATIENT	1.3	1.3		1.0	0.85	NM	
Adapted from June Boon, Veterinary Echocardiography, 1998 Sisson D et al. JVIM 1991; 5: 232, Jacobs et al. Am J Vet Res 1985; 46:1705							



**PATIENT**

Bear Brabham

**ULTRASONOGRAPHIC FINDINGS**

Normal echocardiogram with trivial mitral insufficiency, not clinically significant.

**SPECIES**

Feline

**INTERPRETATION OF THE FINDINGS & FURTHER RECOMMENDATIONS**

There is no contraindication to anesthetic procedure if necessary.

**BREED**

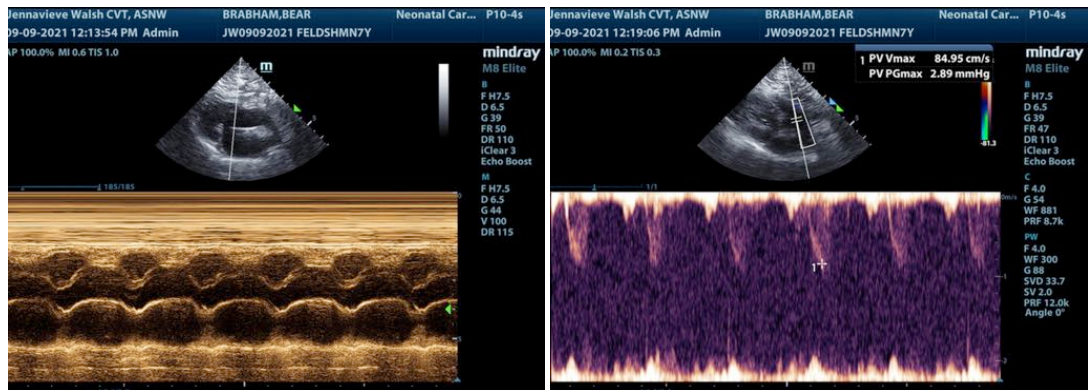
Domestic Shorthair

**SEX**

Neutered male

**AGE**

7 years



**WEIGHT**

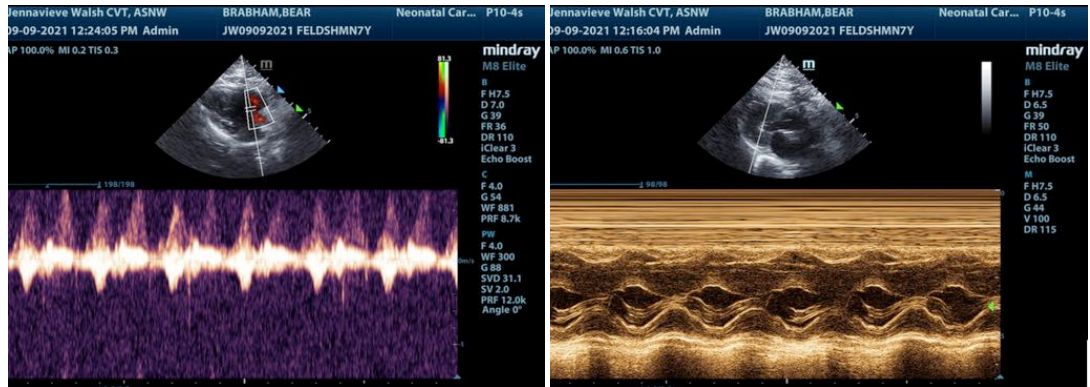
18 lbs

**INTERPRETED BY**

Eric Lindquist, DMV,  
DABVP, Cert. IVUSS

**IMAGING PERFORMED BY**

Jenna Walsh, CVT

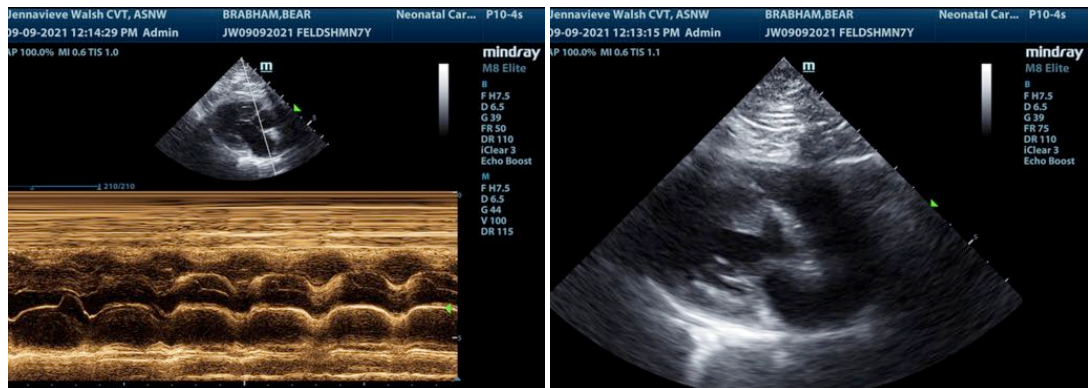


**HOSPITAL NAME**

Albany AH

**REFERRING VET**

Dr. Glaze



**DATE**

9/10/21

**Invoice**

91768



**PATIENT**

Bear Brabham

**SPECIES**

Feline

**BREED**

Domestic Shorthair

**SEX**

Neutered male

**AGE**

7 years

**WEIGHT**

18 lbs

**INTERPRETED BY**

Eric Lindquist, DMV,  
DABVP, Cert. IVUSS

**IMAGING PERFORMED BY**

Jenna Walsh, CVT

**HOSPITAL NAME**

Albany AH

**REFERRING VET**

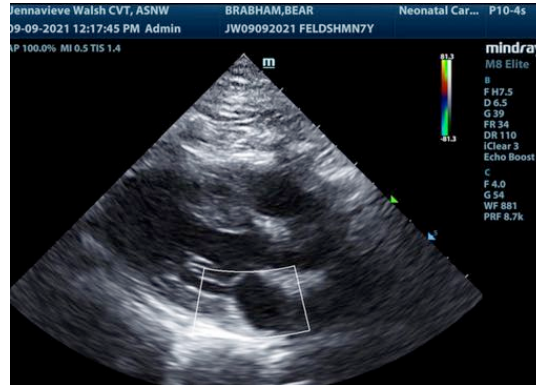
Dr. Glaze

**DATE**

9/10/21

**Invoice**

91768



The information and recommendations provided are based on the images presented by the referring veterinarian. No evaluation can be communicated regarding pathology that was not visible in the image/video clips provided.

Thank you for this referral. If the clinical or image interpretation does not parallel your findings or if I can be of any further assistance please contact me.

Eric Lindquist, DMV, DABVP, Cert. IVUSS

CEO of Sonopath.com

Eric.Lindquist@SonoPath.com