



PATIENT

Henry Seleen

SPECIES

Feline

BREED

Domestic Medium Hair

SEX

Neutered male

AGE

9 years

WEIGHT

10.15 lbs

INTERPRETED BY

Eric Lindquist, DMV,
DABVP, Cert. IVUSS

**IMAGING
PERFORMED BY**

Jenna Walsh, CVT

HOSPITAL NAME

VCA Vitality AH

REFERRING VET

Dr. Clawson

DATE

9/1/21

Invoice
91612

PRESENTING CLINICAL SIGNS

History: 2/6 heart murmur significant dental disease making him be a finicky eater Heart Rate and Respiratory Rates HR=132, RR=60 Current Medications gabapentin 25 mg po at night and Denamarin--small cat size once daily

Attached liver enzymes have increased since October 2020, I think most likely due to finicky appetite due to oral pain but wanted to make sure heart is doing okay and that abdomen appears WNL. T.P. and globulin were slightly increased since October and have also increased since then, so I wanted chest/abdomen looked at for any abnormalities--FIP??

ULTRASONOGRAPHIC EXAMINATION OF THE ABDOMEN

Urinary System

The **urinary bladder**, trigone, and pelvic urethra presented normal thicknesses and normal tone. The pelvic urethra was imaged 2.0 cm beyond the cystourethral junction. The ureters were not visible which is normal. No uroliths or sediment were visualized and anechoic urine was present. No evidence of inflammatory or neoplastic changes was noted. Ureteral papillae were normal.

The **kidneys** presented a relatively uniform cortical hyperechogenicity when compared to the renal medulla, spleen and liver. No overt masses were noted. Corticomedullary definition was nebulous and the ratio favored the cortex slightly. The ureters were not visible and assumed to be normal. These changes are most consistent with chronic interstitial nephritis yet infiltrative disease could not be entirely ruled out without biopsy though neoplasia is not suspected. The right kidney measured 3.8 cm.

Adrenal Glands

Both **adrenal glands** were visualized and recognized as having normal shape, size, position and echogenicity for this breed. The phrenic vasculature, glandular echogenicity and detail were unremarkable. Capsule, cortex, and medullary definition were normal for this age patient. The left adrenal gland measured 0.36 cm. The right adrenal gland measured 0.48 cm.

Spleen

The **spleen** in this patient was mildly enlarged with uniform parenchyma and was folded upon itself caudally. This is a positional variant and is not pathological. There was no evidence of significant disease.

Liver

The **liver** images submitted revealed subjectively normal liver size, contour, and structure. Parenchymal echogenicity was naturally coarse and hypoechoic to the spleen. Vascular and biliary tracts were of normal volume with no evidence of congestion. The gallbladder presented acceptably thin walls with primarily anechoic content. The cystic and common bile ducts were normal. No pathological hepatic lymphadenopathy was evident. No overt structural evidence of inflammatory, infiltrative or regenerative pathology was evident.



PATIENT

Gastrointestinal

Henry Seleen

Examination of the **gastrointestinal tract** revealed a stomach and intestine free of stasis, of normal wall thickness, acceptable curvilinear mural detail, and peristaltic activity. Small and large intestine demonstrated normal luminal chyme and stool consistency respectively. No obstructive or overt infiltrative disease was noted. No associated abnormal lymphatic activity was noted.

SPECIES

Feline

BREED

Domestic Medium Hair

Pancreas

The base and limbs of the **pancreas** were observed to be largely isoechoic to surrounding omental fat. Pancreatic duct and capsular contour were acceptably normal and parenchyma respected normal curvilinear patterns. No overt evidence of active inflammatory or neoplastic disease was noted.

SEX

Neutered male

ULTRASONOGRAPHIC EXAMINATION OF THE HEART

AGE

9 years

The echocardiogram in this patient demonstrated normal **left atrial** size based on 3 separate LA measurements. The cranial and caudal **mitral** valve leaflets presented normal linear structure and kinetics. The **left ventricle** presented normal thicknesses with linear contour and was not dilated nor restricted. The **myocardium** presented normal echogenicity without subjective evidence of significant fibrotic or ischemic disease. **Contractility** of the ventricular walls was adequate and in normal range for this patient evidenced by the fractional shortening measurement and subjective evaluation of the different regions and angles of the myocardium. The **left ventricular outflow** tract demonstrated normal laminar flow and subjective structural integrity. The **right atrium** and auricle revealed normal size, structure and content. No evidence of masses was noted or chamber overload. **Tricuspid** valvular assessment demonstrated adequate linear morphology and kinetics. The **right ventricle** was of normal size (1/3 diameter of LV), chordae structure, myocardial echogenicity and thickness. **Pulmonic** tract assessment revealed normal valve structure, laminar flow, and diameter (approx. 1:1 pa/ao ratio). No visible **pericardial** or free pleura fluid was noted or extra cardiac pathology in the visible planes. The cranial **mediastinum** and **pericardial regions** were free of masses in the visible window.

WEIGHT

10.15 lbs

INTERPRETED BY

Eric Lindquist, DMV,
DABVP, Cert. IVUSS

IMAGING PERFORMED BY

Jenna Walsh, CVT

HOSPITAL NAME

VCA Vitality AH

REFERRING VET

Dr. Clawson

DATE

9/1/21

Invoice
91612



PATIENT
Henry Seleen

SPECIES
Feline

BREED
Domestic Medium Hair

SEX
Neutered male

AGE
9 years

FELINE CARDIAC PARAMETERS	BODY WEIGHT (kg)	HR (BPM)	IVSd (cm)	LVIDd (cm)	LVWd (cm)	FS (%)	EF (%)
NORMAL PARAMETER	-----	150-240	0.3-0.6	1.0-2.1	0.25-0.6	35-67	80-100
PATIENT		NM	0.5	1.2	0.5	50	80
FELINE CARDIAC PARAMETERS	LA/AO (Boon)	LA/AO HEART BASE (Sisson)	LA 2D 4-chamber long axis AS to FW (Sisson) (cm)		LVOT VEL. (m/s)	RVOT VEL. (m/s)	IVRT (m/)
NORMAL PARAMETER	<1.5	0.88-1.79	0.7-1.7		<1.6	<1.3	40-60
PATIENT	1.4	1.17	1.16 max			1.0	NM
Adapted from June Boon, Veterinary Echocardiography, 1998 Sisson D et al. JVIM 1991; 5: 232, Jacobs et al. Am J Vet Res 1985; 46:1705							

WEIGHT
10.15 lbs

ULTRASONOGRAPHIC FINDINGS

Mild interstitial nephrosis pattern.

Reactive hepatopathy is likely.

Normal echocardiogram, flow murmur.

INTERPRETED BY

Eric Lindquist, DMV,
DABVP, Cert. IVUSS

INTERPRETATION OF THE FINDINGS & FURTHER RECOMMENDATIONS

There is no evidence of cardiac pathology. Likely volume shifts playing a role or simple benign flow murmur. There is no evidence of abdominal or cardiac disease that would be responsible for anorexia in this patient. Oral pain owing to dental disease or gingival disease, spinal or other orthopedic pain, CNS or non-cardiac thoracic cardiac disease should all be considered.

IMAGING PERFORMED BY

Jenna Walsh, CVT

HOSPITAL NAME

VCA Vitality AH

REFERRING VET

Dr. Clawson

DATE

9/1/21

Invoice
91612



PATIENT

Henry Seleen

SPECIES

Feline

BREED

Domestic Medium Hair

SEX

Neutered male

AGE

9 years

WEIGHT

10.15 lbs

INTERPRETED BY

Eric Lindquist, DMV,
DABVP, Cert. IVUSS

IMAGING PERFORMED BY

Jenna Walsh, CVT

HOSPITAL NAME

VCA Vitality AH

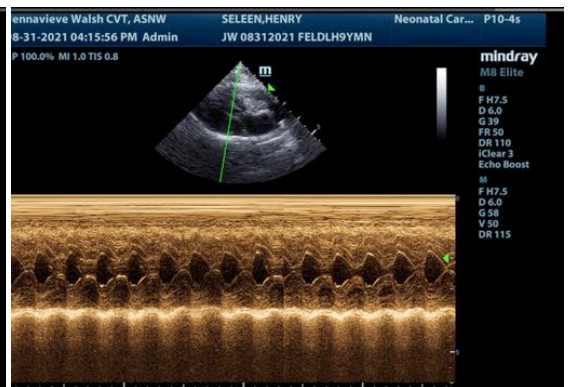
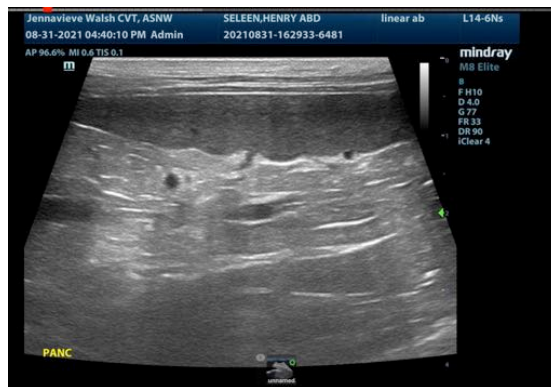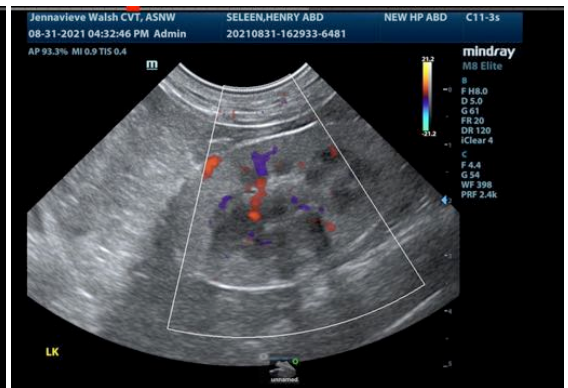
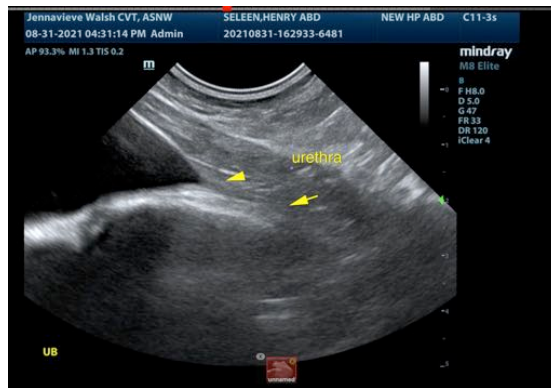
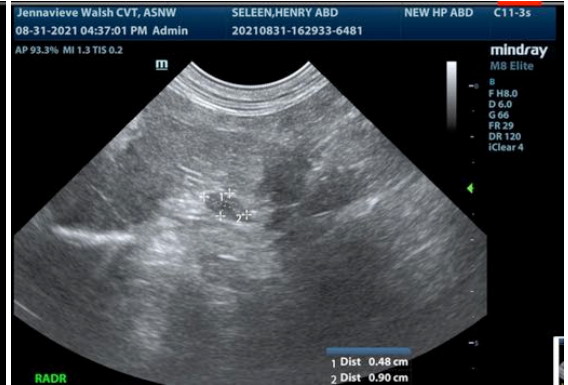
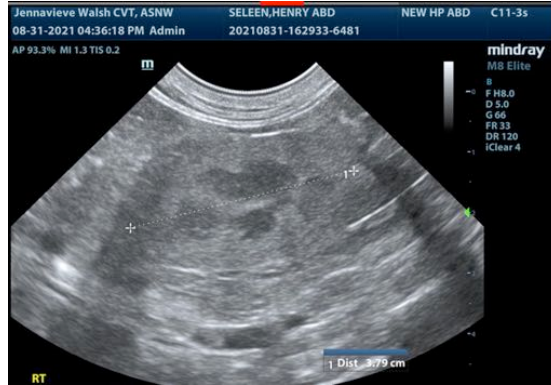REFERRING VET

Dr. Clawson

DATE

9/1/21

Invoice
91612





PATIENT

Henry Seleen

SPECIES

Feline

BREED

Domestic Medium Hair

SEX

Neutered male

AGE

9 years

WEIGHT

10.15 lbs

INTERPRETED BY

Eric Lindquist, DMV,
DABVP, Cert. IVUSS

IMAGING PERFORMED BY

Jenna Walsh, CVT

HOSPITAL NAME

VCA Vitality AH

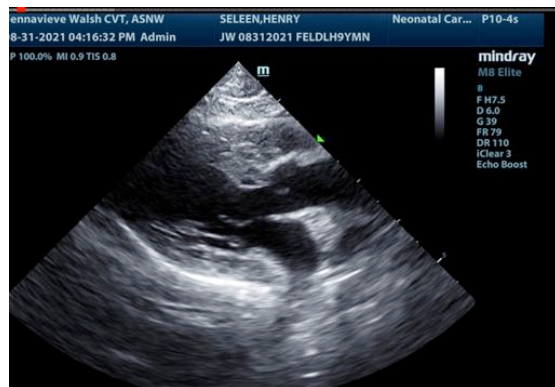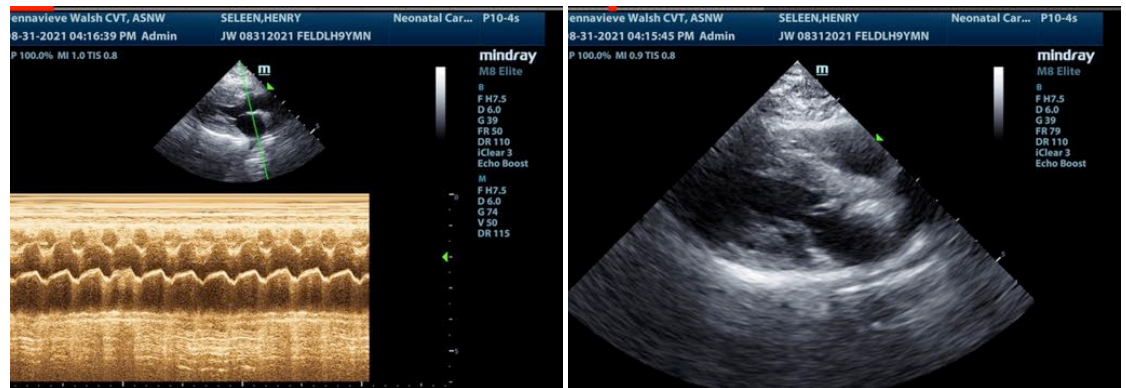
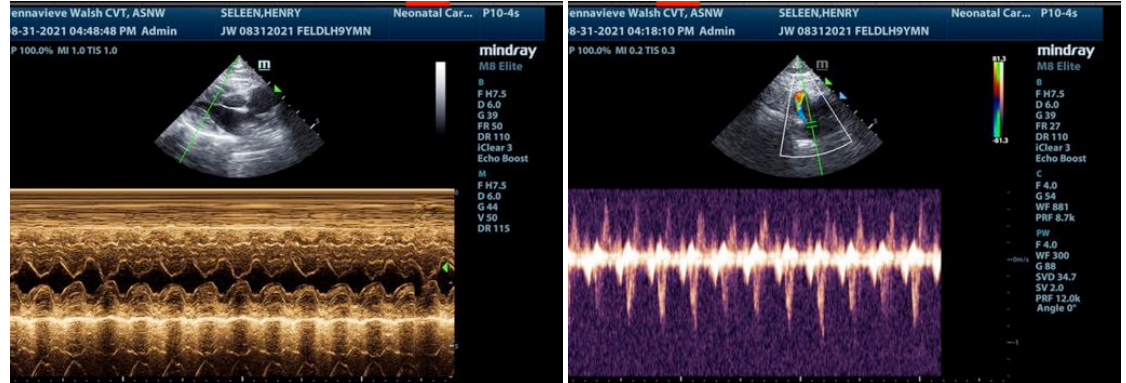
REFERRING VET

Dr. Clawson

DATE

9/1/21

Invoice
91612

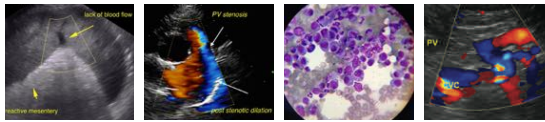


The information and recommendations provided are based on the images presented by the referring veterinarian. No evaluation can be communicated regarding pathology that was not visible in the image/video clips provided.

Thank you for this referral. If the clinical or image interpretation does not parallel your findings or if I can be of any further assistance please contact me.

Eric Lindquist, DMV, DABVP, Cert. IVUSS

CEO of Sonopath.com



PATIENT

Eric.Lindquist@SonoPath.com

Henry Seleen

SPECIES

Feline

BREED

Domestic Medium Hair

SEX

Neutered male

AGE

9 years

WEIGHT

10.15 lbs

INTERPRETED BY

Eric Lindquist, DMV,
DABVP, Cert. IVUSS

**IMAGING
PERFORMED BY**

Jenna Walsh, CVT

HOSPITAL NAME

VCA Vitality AH

REFERRING VET

Dr. Clawson

DATE

9/1/21

Invoice
91612