



PATIENT PRESENTING CLINICAL SIGNS

Nieko Newman

History: Qar, dehydrated, vomited multiple times throughout day
Abnormal PE/Chem/CBC/UA Results: wnl Current Medications Gave cerenia Radiographic Findings
Not taken, O restricted on funds

SPECIES

Canine

BREED

Shih Tzu

SEX

Neutered male

AGE

14 years

WEIGHT

14.2 lbs

INTERPRETED BY

Eric Lindquist, DMV,
DABVP, Cert. IVUSS

IMAGING PERFORMED BY

Sara Hansen

HOSPITAL NAME

Pawsitive Wellness VC

REFERRING VET

Dr. Hardy

DATE

8/4/22

Invoice

32192

ULTRASONOGRAPHIC EXAMINATION OF THE ABDOMEN

Urinary System

The **urinary bladder**, trigone, and pelvic urethra presented normal thicknesses and normal tone. The ureters were not visible which is normal. No uroliths or sediment were visualized and anechoic urine was present. No evidence of inflammatory or neoplastic changes was noted. Ureteral papillae were normal.

The **kidneys** revealed largely normal size and structure, corticomedullary definition and ratio (cortex 1/3 of medulla) were essentially maintained with some age-related loss of curvilinear patterns regarding the capsule and C/M junction. The cortices presented largely uniform texture with some increased echogenicity expected for his age patient. Medullary structure differed distinctly from that of the cortex and no evidence of pelvic dilation was present. The left kidney measured 4.19 cm. The right kidney measured 4.71 cm.

Adrenal Glands

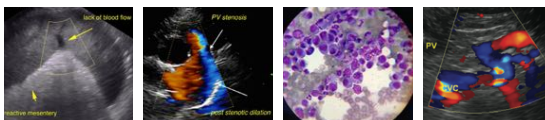
Both **adrenal glands** were visualized and recognized as having normal shape, size, position and echogenicity for this breed. The phrenic vasculature, glandular echogenicity and detail were unremarkable. Capsule, cortex, and medullary definition were normal for this age patient. The right adrenal gland measured 2.1 x 0.59 cm at the caudal pole and 1.24 cm at the cranial pole. The left adrenal gland measured 1.61 x 0.53 cm at the caudal pole and 0.5 cm at the cranial pole.

Spleen

The **spleen** presented a smooth homogeneous parenchyma hyperechoic to liver and renal cortical parenchyma. The capsule was smooth without noticeable expansion or deviation from within the spleen or adjacent pathology. The splenic vasculature demonstrated normal volume without signs of congestion or thrombosis. No sonographic evidence of acute or chronic inflammatory, neoplastic, or infarctual changes was noted.

Liver

The **liver** images from right and left intercostal as well as subcostal views revealed subjectively normal liver size, contour, and structure. Some age-related parenchymal remodeling was noted but likely not clinically significant at this time. Vascular and biliary tracts were of normal volume and no evidence of congestion was noted. The gallbladder presented some dependent debris with essentially normal



PATIENT

Nieko Newman

contour. The cystic and common bile ducts were normal. No overt evidence of active inflammatory, infiltrative or regenerative pathology was noted but should be paired with current or past LE elevations regarding any clinical significance to this presentation. The hepatic lymph nodes were unremarkable.

SPECIES

Canine

Gastrointestinal

The **gastric** wall was mildly thickened with an empty lumen. The small intestines and colon were unremarkable.

BREED

Shih Tzu

Pancreas

SEX

Neutered male

The base and limbs of the **pancreas** were observed to be largely isoechoic to surrounding omental fat. Pancreatic duct and capsular contour were acceptably normal and parenchyma respected normal curvilinear patterns. No overt evidence of active inflammatory or neoplastic disease was noted.

AGE

14 years

ULTRASONOGRAPHIC FINDINGS

Structurally unremarkable abdomen.

WEIGHT

14.2 lbs

Mild gastritis pattern.

INTERPRETATION OF THE FINDINGS & FURTHER RECOMMENDATIONS

There was no evidence of pathology. A clinical trial of the following can be considered. There is no evidence of foreign body or neoplasia. The patient should respond well to therapy. I recommend canned b.i.d. feedings as gastric irritation from kibble may be an issue with the gastric hypertrophy.

INTERPRETED BY

Eric Lindquist, DMV,
DABVP, Cert. IVUSS

Helicobacter/Gastritis protocol

A clinical trial of **Zithromax** (**Dogs:** 5-10 mg/kg p.o. q24h. May increase dosing interval to q48h after 3-5 days of treatment), **Metronidazole** (10-20 mg/kg p.o. b.i.d.), **Pepcid** (0.5-1 mg/kg s.i.d.) and **Sucralfate** (0.5-2 g/dog PO) or **Omeprazole** (1 mg/kg p.o. s.i.d.) over the next 3 weeks along with a **novel-protein or hydrolyzed diet** with slurry feeding b.i.d./t.i.d. over the next 2-4 days and then increase to canned diet bid. Dry food should be avoided over the next 4 weeks. A recheck sonogram to assess GI improvement or progression would be ideal in 4 weeks.

IMAGING PERFORMED BY

Sara Hansen

HOSPITAL NAME

Pawsitive Wellness VC

REFERRING VET

Dr. Hardy

DATE

8/4/22

Invoice

32192



PATIENT

Nieko Newman

SPECIES

Canine

BREED

Shih Tzu

SEX

Neutered male

AGE

14 years

WEIGHT

14.2 lbs

INTERPRETED BY

Eric Lindquist, DMV,
DABVP, Cert. IVUSS

IMAGING PERFORMED BY

Sara Hansen

HOSPITAL NAME

Pawsitive Wellness VC

REFERRING VET

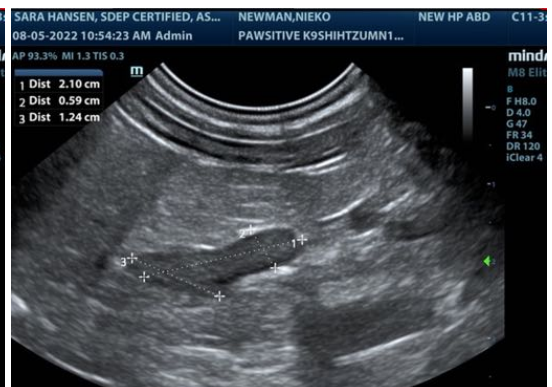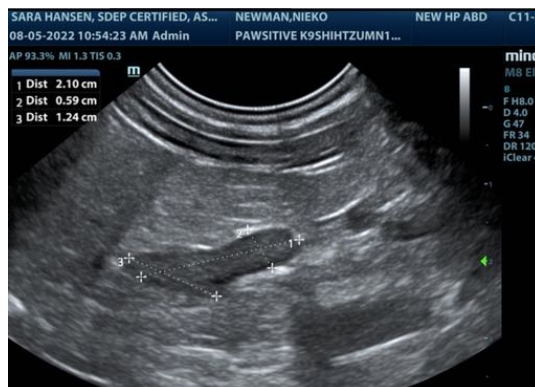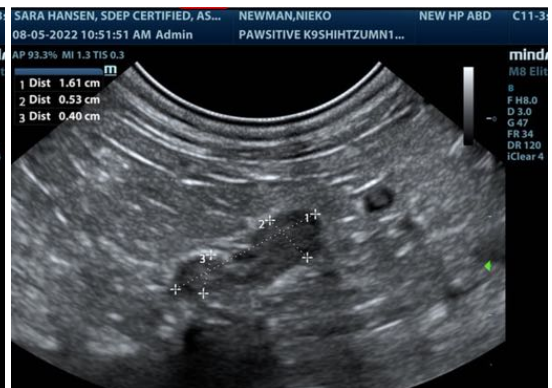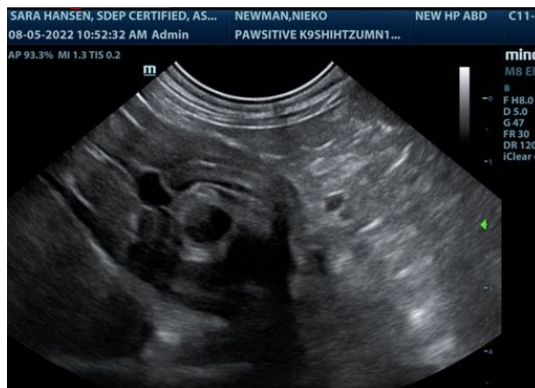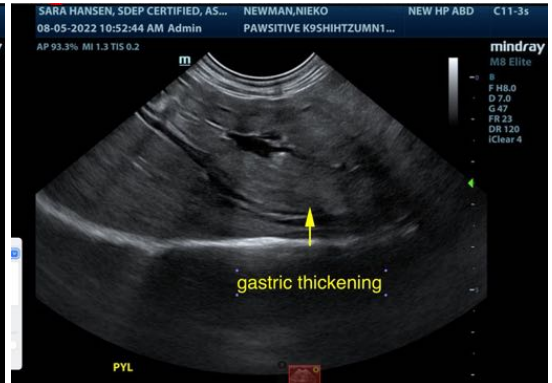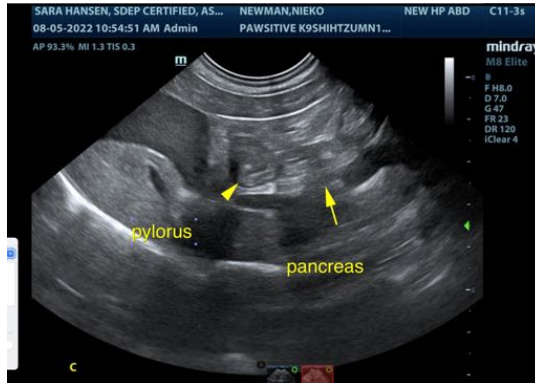
Dr. Hardy

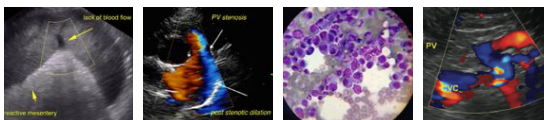
DATE

8/4/22

Invoice

32192





PATIENT

Nieko Newman

SPECIES

Canine

BREED

Shih Tzu

SEX

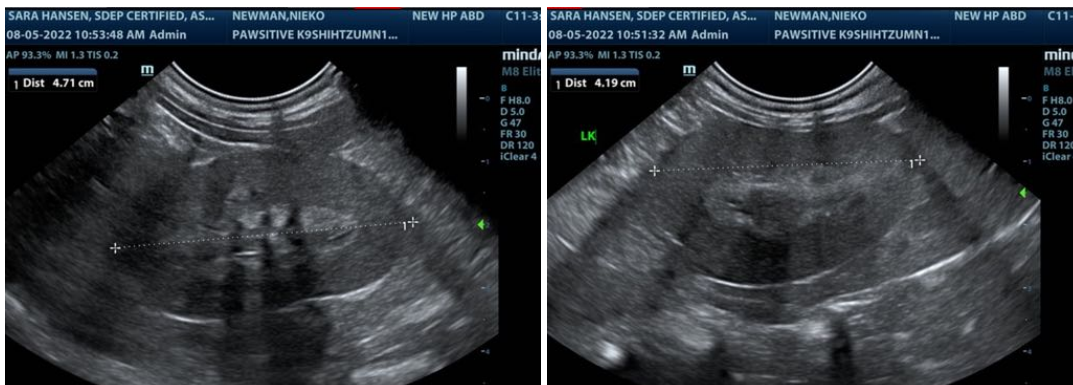Neutered male

AGE

14 years

WEIGHT

14.2 lbs



The information and recommendations provided are based on the images presented by the referring veterinarian/sonographer. No evaluation can be communicated regarding pathology that was not visible in the image/video clips provided.

Thank you for this referral. If the clinical or image interpretation does not parallel your findings or if I can be of any further assistance please contact me.

Eric Lindquist, DMV, DABVP, Cert. IVUSS

CEO of SonoPath.com

Eric.Lindquist@SonoPath.com

INTERPRETED BY

Eric Lindquist, DMV,
DABVP, Cert. IVUSS

IMAGING PERFORMED BY

Sara Hansen

HOSPITAL NAME

Pawsitive Wellness VC

REFERRING VET

Dr. Hardy

DATE

8/4/22

Invoice

32192