



PATIENT

Magic Bryan

SPECIES

Canine

BREED

Miniature Schnauzer

SEX

Neutered male

AGE

13 years

WEIGHT

15.3 lbs

INTERPRETED BY

Eric Lindquist, DMV,
DABVP, Cert. IVUSS

IMAGING PERFORMED BY

Jenna Walsh, CVT

HOSPITAL NAME

For the Love of Pets

REFERRING VET

Dr. Jernstedt

PRESENTING CLINICAL SIGNS

History: • Clinical history of cough on and off, owner reports it's a dry cough. • Overweight. • Cataracts. • No cardiac murmurs or arrhythmia auscultated. Owner wanting diagnostics. Heart Rate and Respiratory Rates HR: 106 Blood Pressure Measurements 129/81

ULTRASONOGRAPHIC EXAMINATION OF THE HEART

The echocardiogram in this patient demonstrated normal **left atrial** size based on 3 separate methods of LA evaluation. **Mitral** valve insufficiency was noted and measured 6.5 m/sec. The **left ventricle** presented thicknesses with linear contour and was not dilated nor restricted. The **myocardium** presented normal echogenicity without subjective evidence of significant fibrotic or ischemic disease. **Contractility** of the ventricular walls was adequate and in normal range for this patient evidenced by the fractional shortening measurement and subjective evaluation of the different regions of the myocardium. The **left ventricular outflow** tract demonstrated normal laminar flow and subjective structural integrity. The **right atrium** and auricle revealed normal size, structure and content. No evidence of masses was noted. **Tricuspid** insufficiency was noted. The **right ventricle** was of normal size (1/3 diameter of LV), chordae structure, myocardial echogenicity and thickness. **Pulmonary outflow** tract assessment revealed normal valve structure, laminar flow, and diameter (approx. 1:1 pa/ao ratio). No visible **pericardial** or free pleura fluid was noted. The cranial **mediastinum and pericardial and extra-cardiac regions** were free of masses in the visible window.

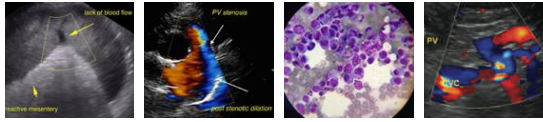
CANINE CARDIAC PARAMETERS	MR VMAX (m/s)	TR VMAX (m/s)	LA/AO (Boon method)	LA/AO (Heart Base; Swe)	FS (%)	EF (%)	EPSS (cm)
NORMAL PARAMETER	4.5-5.5	<2.7	1.3	<1.6	28-40	40-100	<0.6
PATIENT	6.5	3.0	1.15	1.2	45	90	0.2
CANINE CARDIAC PARAMETERS	HR (BPM)	AV VMAX (m/s)	PV MAX (m/s)	BODY WEIGHT	LA 2D short axis Base view (cm)	LVIDd Avg; 2D and m- mode short axis (cm)	LVIDs Avg; 2D and m- mode short axis (cm)
NORMAL PARAMETER	50-100	0.7-1.7	0.7-1.6				
PATIENT		1.1	1.3	15.3 lbs		2.5	

DATE

8/17/21

Invoice

91231



PATIENT

Magic Bryan

ULTRASONOGRAPHIC FINDINGS

Mitral and tricuspid insufficiency, presented minor jets. There was no evidence of volume overload in either atria.

SPECIES

Canine

INTERPRETATION OF THE FINDINGS & FURTHER RECOMMENDATIONS

The cough is non-cardiogenic in this patient. The mitral and tricuspid insufficiency are relatively minor given the M-mode measurements. Primary respiratory protocol is recommended in this patient. A recheck echocardiogram is recommended in 6 months or earlier if murmur grade increases or clinical signs initiate. No cardiac medications are recommended.

BREED

Miniature Schnauzer

SEX

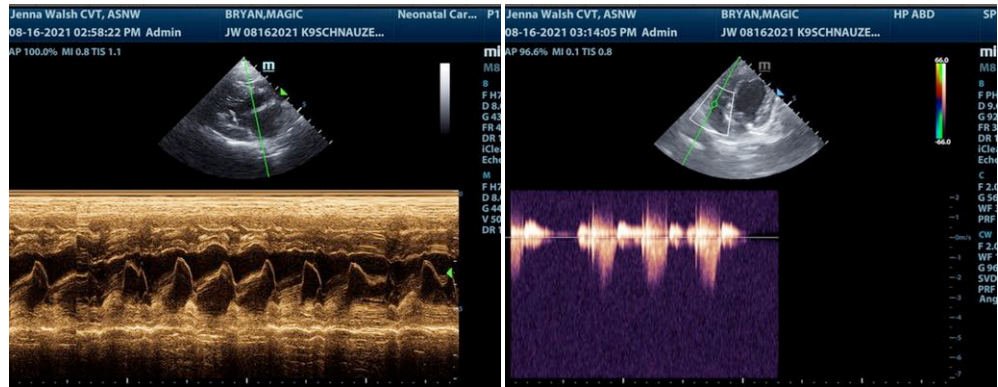
Neutered male

AGE

13 years

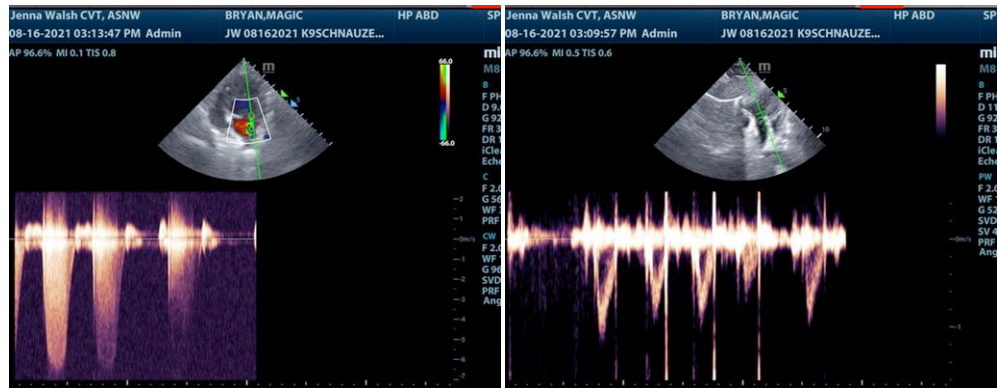
WEIGHT

15.3 lbs



INTERPRETED BY

Eric Lindquist, DMV,
DABVP, Cert. IVUSS



IMAGING PERFORMED BY

Jenna Walsh, CVT

HOSPITAL NAME

For the Love of Pets

REFERRING VET

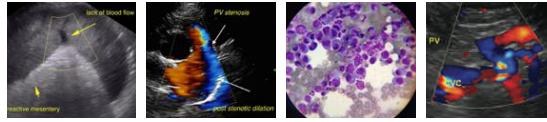
Dr. Jernstedt

DATE

8/17/21

Invoice

91231



PATIENT

Magic Bryan

SPECIES

Canine

BREED

Miniature Schnauzer

SEX

Neutered male

AGE

13 years

WEIGHT

15.3 lbs

INTERPRETED BY

Eric Lindquist, DMV,
DABVP, Cert. IVUSS

IMAGING PERFORMED BY

Jenna Walsh, CVT

HOSPITAL NAME

For the Love of Pets

REFERRING VET

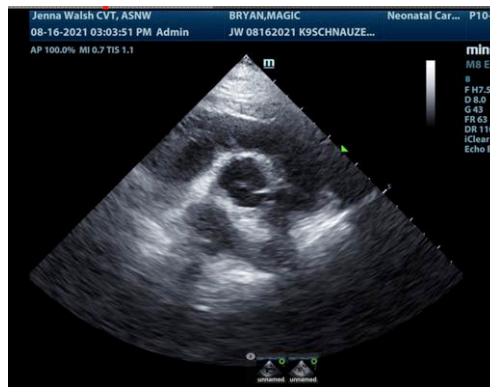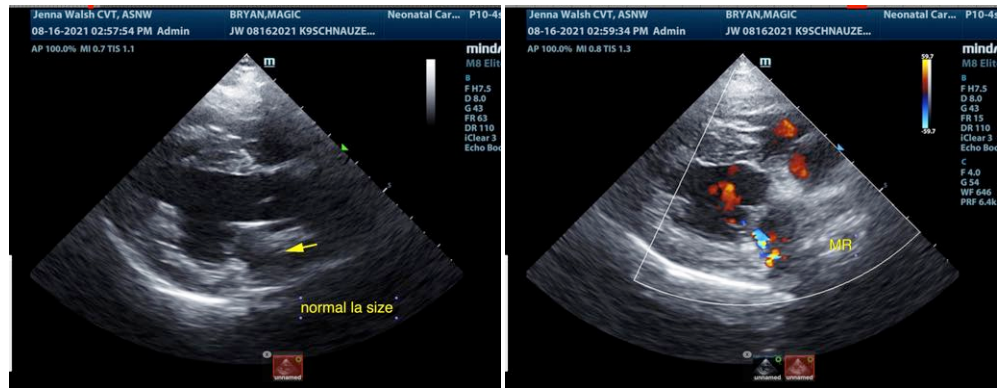
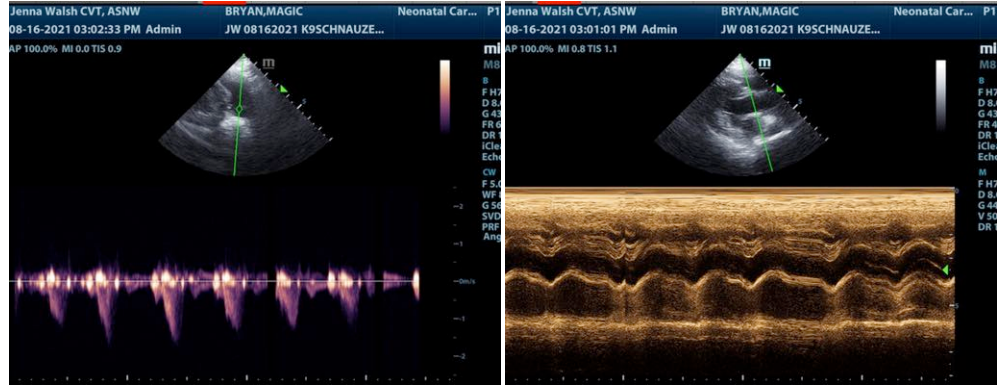
Dr. Jernstedt

DATE

8/17/21

Invoice

91231

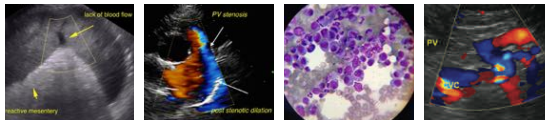


The information and recommendations provided are based on the images presented by the referring veterinarian. No evaluation can be communicated regarding pathology that was not visible in the image/video clips provided.

Thank you for this referral. If the clinical or image interpretation does not parallel your findings or if I can be of any further assistance please contact me.

Eric Lindquist, DMV, DABVP, Cert. IVUSS

CEO of SonoPath.com



PATIENT

Eric.Lindquist@SonoPath.com

Magic Bryan

SPECIES

Canine

BREED

Miniature Schnauzer

SEX

Neutered male

AGE

13 years

WEIGHT

15.3 lbs

INTERPRETED BY

Eric Lindquist, DMV,
DABVP, Cert. IVUSS

**IMAGING
PERFORMED BY**

Jenna Walsh, CVT

HOSPITAL NAME

For the Love of Pets

REFERRING VET

Dr. Jernstedt

DATE

8/17/21

Invoice

91231