



PATIENT PRESENTING CLINICAL SIGNS

Moose Snow

History: -RAPID WEIGHT LOSS -INCREASED APPETITE AND URINATION -HEPATOMEGALY
Abnormal PE/Chem/CBC/UA Results: AP 1200, ALT 700'S Current Medications DENAMARIN

SPECIES

Canine

ULTRASONOGRAPHIC EXAMINATION OF THE ABDOMEN

Urinary System

BREED

Malamute Cross

The **urinary bladder**, trigone, and pelvic urethra presented normal thicknesses and normal tone. The ureters were not visible which is normal. No uroliths or sediment were visualized and anechoic urine was present. No evidence of inflammatory or neoplastic changes was noted. Ureteral papillae were normal.

SEX

Neutered male

The **kidneys** revealed normal size and structure, corticomedullary definition and ratio for this age. The cortices presented largely uniform texture with normal echogenic relationship to liver and spleen. Medullary structure differed distinctly from the cortex and no evidence of pelvic dilation was present. The capsules were acceptably uniform without significant irregularities. The left kidney measured 9.2 cm. The right kidney measured 9.3 cm.

AGE

9 years

WEIGHT

93.2 lbs

Adrenal Glands

Both **adrenal glands** were visualized and recognized as having normal shape, size, position and echogenicity for this breed. The phrenic vasculature, glandular echogenicity and detail were unremarkable. Capsule, cortex, and medullary definition were normal for this age patient. The right adrenal gland measured 3.6 x 3.3 cm at the cranial pole and 1.65 cm at the caudal pole. The left adrenal gland measured 4.6 x 0.76 cm at the caudal pole and 0.98 cm at the cranial pole.

INTERPRETED BY

Eric Lindquist, DMV,
DABVP, Cert. IVUSS

IMAGING PERFORMED BY

Sara Hansen

Spleen

The **spleen** presented a smooth homogeneous parenchyma hyperechoic to liver and renal cortical parenchyma. The capsule was smooth without noticeable expansion or deviation from within the spleen or adjacent pathology. The splenic vasculature demonstrated normal volume without signs of congestion or thrombosis. No sonographic evidence of acute or chronic inflammatory, neoplastic, or infarctual changes was noted.

HOSPITAL NAME

Reid VH

REFERRING VET

Dr. Heider

Liver

The **liver** in this patient revealed a complex, attenuating 10+ cm puffy cloud type liver mass that is most consistent with carcinoma. The mass appeared to be pedunculated and deriving from the caudal aspect of the left liver. The mass impinged medially upon the portal hilus and gallbladder. The right liver revealed multi-focal, hyperechoic nodules that may be non-related. The gallbladder presented acceptably thin walls with primarily anechoic content. The cystic and common bile ducts were normal. No pathological hepatic lymphadenopathy was evident.

DATE

8/11/22

Invoice

32312



PATIENT

Gastrointestinal

Moose Snow

Examination of the **gastrointestinal tract** revealed a stomach and intestine free of stasis, of normal wall thickness, acceptable curvilinear mural detail, and peristaltic activity. Small and large intestine demonstrated normal luminal chyme and stool consistency respectively. No obstructive or overt infiltrative disease was noted. No associated abnormal lymphatic activity was noted.

SPECIES

Canine

BREED

Malamute Cross

Pancreas

The base and limbs of the **pancreas** were observed to be largely isoechoic to surrounding omental fat. Pancreatic duct and capsular contour were acceptably normal and parenchyma respected normal curvilinear patterns. No overt evidence of active inflammatory or neoplastic disease was noted.

SEX

Neutered male

ULTRASONOGRAPHIC FINDINGS

Left sided hepatic mass. Suspect carcinoma.

AGE

9 years

Right sided hepatic nodules. Nodular hyperplasia versus metastatic carcinoma.

WEIGHT

93.2 lbs

INTERPRETATION OF THE FINDINGS & FURTHER RECOMMENDATIONS

CT evaluation is warranted for surgical planning. FNA of the left sided liver mass and right sided nodules are warranted for staging purposes or direct surgical intervention with left liver lobectomy and right-sided liver biopsies.

INTERPRETED BY

Eric Lindquist, DMV,
DABVP, Cert. IVUSS

IMAGING PERFORMED BY

Sara Hansen

HOSPITAL NAME

Reid VH

REFERRING VET

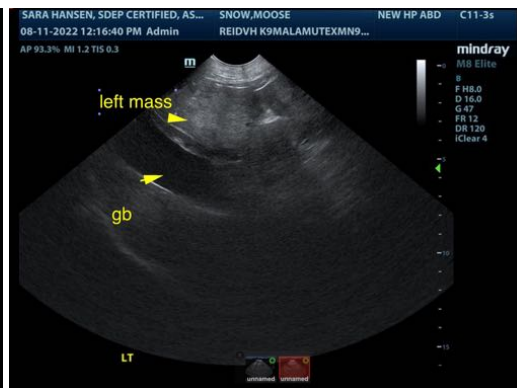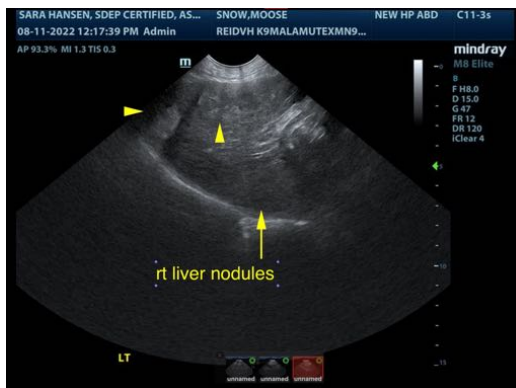
Dr. Heider

DATE

8/11/22

Invoice

32312





PATIENT

Moose Snow

SPECIES

Canine

BREED

Malamute Cross

SEX

Neutered male

AGE

9 years

WEIGHT

93.2 lbs

INTERPRETED BY

Eric Lindquist, DMV,
DABVP, Cert. IVUSS

IMAGING PERFORMED BY

Sara Hansen

HOSPITAL NAME

Reid VH

REFERRING VET

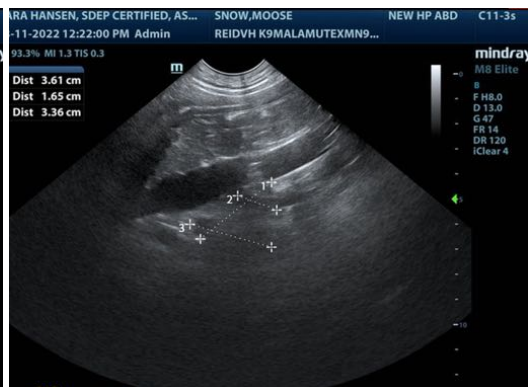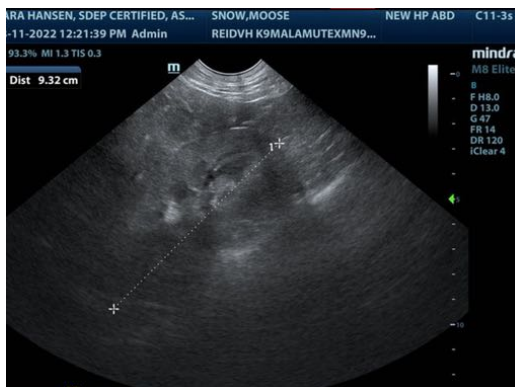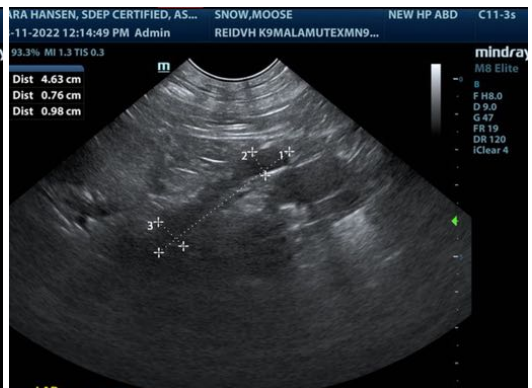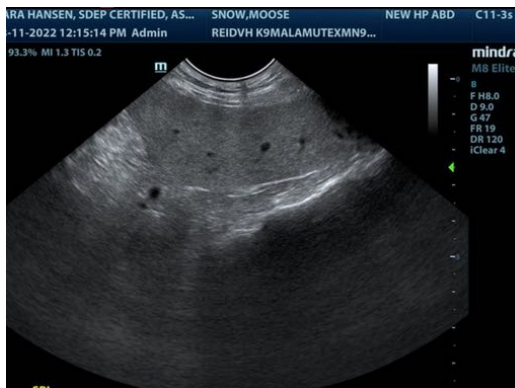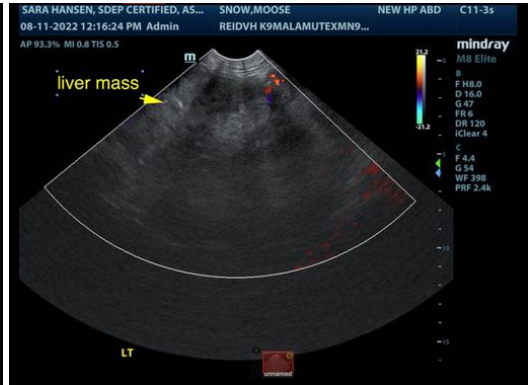
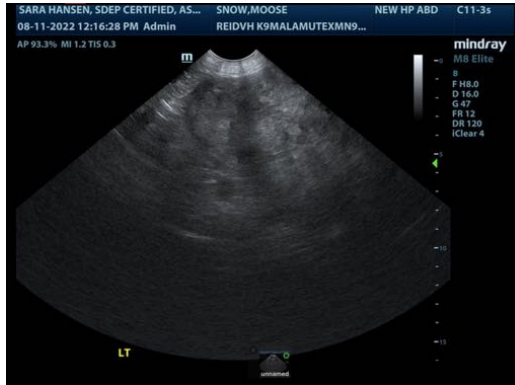Dr. Heider

DATE

8/11/22

Invoice

32312





PATIENT

Moose Snow

SPECIES

Canine

BREED

Malamute Cross

SEX

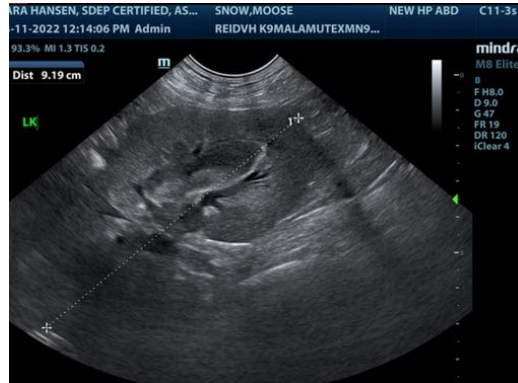Neutered male

AGE

9 years

WEIGHT

93.2 lbs



The information and recommendations provided are based on the images presented by the referring veterinarian/sonographer. No evaluation can be communicated regarding pathology that was not visible in the image/video clips provided.

Thank you for this referral. If the clinical or image interpretation does not parallel your findings or if I can be of any further assistance please contact me.

Eric Lindquist, DMV, DABVP, Cert. IVUSS

CEO of Sonopath.com

Eric.Lindquist@SonoPath.com

INTERPRETED BY

Eric Lindquist, DMV,
DABVP, Cert. IVUSS

IMAGING PERFORMED BY

Sara Hansen

HOSPITAL NAME

Reid VH

REFERRING VET

Dr. Heider

DATE

8/11/22

Invoice

32312