

PATIENT

Max Trepanier

SPECIES

Canine

BREED

Golden Retriever Cross

SEX

Neutered male

AGE

13 years

WEIGHT

49 lbs

INTERPRETED BY

Eric Lindquist, DMV,
DABVP, Cert. IVUSS

IMAGING PERFORMED BY

Sara Hansen

HOSPITAL NAME

Amazon Park AC

REFERRING VET

Dr. Jones

DATE

8/10/23

Invoice

46546

PRESENTING CLINICAL SIGNS

History: Presented 7/7 with complaint of PU/PD - labwork showed creatinine of 1.9, USG 1.016, slightly high ALT at 219. Started on Purina NF. Weighed 53 pounds. Came back 8/8 after losing 4 pounds, having reduced appetite and periodic vomiting. Creatinine up to 2.2, ALT up to 295 and ALP now high at 437. Radiographs moderately thickened stomach and stomach axis notably abnormal on lateral view.

ABNORMAL Laboratory Findings 11/29/2022 - creatinine 1.2, ALT 245, ALP 337 7/7 creatinine 1.9, ALT 219, ALP 194 (normal), USG 1.016 with 2+ proteinuria, quiet sediment 8/8 creatinine 2.2, ALT 295, ALP 437 CBC normal throughout Current Medications None

ULTRASONOGRAPHIC EXAMINATION OF THE ABDOMEN

Urinary System

The **urinary bladder**, trigone, and pelvic urethra presented normal thicknesses and normal tone. The pelvic urethra was imaged 2.0 cm beyond the cystourethral junction and appeared normal. The ureters were not visible which is normal. No uroliths or sediment were visualized and anechoic urine was present. No evidence of inflammatory or neoplastic changes was noted. Ureteral papillae were normal.

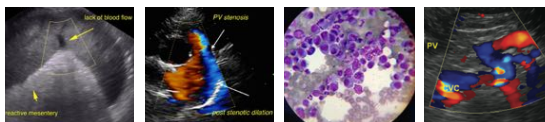
The **kidneys** revealed largely normal size and structure, corticomedullary definition and ratio (cortex 1/3 of medulla) were essentially maintained with some age-related loss of curvilinear patterns regarding the capsule and C/M junction. The cortices presented largely uniform texture with some increased echogenicity expected for his age patient. Medullary structure differed distinctly from that of the cortex and no evidence of pelvic dilation was present. An anechoic cyst was noted at the cranial cortex of the right kidney and measured 2.1 cm. The right kidney measured 3.93 cm with slight pinpoint mineralization. The left kidney measured 6.44 cm.

Adrenal Glands

The **adrenal glands** appeared slightly enlarged and swollen. No evidence of focal capsular expansion or invasion into the phrenic veins was noted. No overt suspicion of neoplasia was noted. This is considered likely a hyperplastic change associated with stress or adrenal endocrinopathy (PDH). If isosthenuria is persistently present and the patient morphologically suggests Cushing's disease then ACTH testing would be indicated. The left adrenal gland measured 2.93 x 1.29 cm at the cranial pole and 0.9 cm at the caudal pole. The right adrenal gland measured 2.88 x 1.92 cm at the cranial pole and 0.63 cm at the caudal pole.

Spleen

The **spleen** presented a smooth homogeneous parenchyma hyperechoic to liver and renal cortical parenchyma. The capsule was smooth without noticeable expansion or deviation from within the spleen or adjacent pathology. The splenic vasculature demonstrated normal volume without signs of congestion or thrombosis. No sonographic evidence of acute or chronic inflammatory, neoplastic, or infarctual changes was noted.



PATIENT

Max Trepanier

SPECIES

Canine

BREED

Golden Retriever Cross

SEX

Neutered male

AGE

13 years

WEIGHT

49 lbs

INTERPRETED BY

Eric Lindquist, DMV,
DABVP, Cert. IVUSS

IMAGING PERFORMED BY

Sara Hansen

HOSPITAL NAME

Amazon Park AC

REFERRING VET

Dr. Jones

DATE

8/10/23

Invoice

46546

Liver

The **liver** revealed coarse architecture with increased portal markings. Hyperechoic, non-disruptive, nodular changes were noted. The gallbladder presented acceptably thin walls with primarily anechoic content. The cystic and common bile ducts were normal.

Gastrointestinal

Examination of the **gastrointestinal tract** revealed a stomach and intestine free of stasis, of normal wall thickness, acceptable curvilinear mural detail, and peristaltic activity. Small and large intestine demonstrated normal luminal chyme and stool consistency respectively. No obstructive or overt infiltrative disease was noted. No associated abnormal lymphatic activity was noted.

Pancreas

The base and limbs of the **pancreas** were observed to be largely isoechoic to surrounding omental fat. Pancreatic duct and capsular contour were acceptably normal and parenchyma respected normal curvilinear patterns. No overt evidence of active inflammatory or neoplastic disease was noted.

ULTRASONOGRAPHIC FINDINGS

Hepatic remodeling, nodular hyperplasia pattern.

Anechoic cyst in the right kidney.

Bilateral adrenal hypertrophy, potential emerging PDH.

Otherwise, benign abdomen.

INTERPRETATION OF THE FINDINGS & FURTHER RECOMMENDATIONS

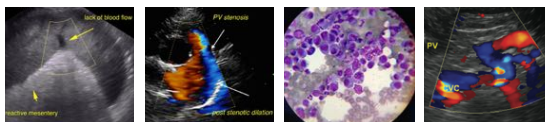
Bile acid profile is warranted. FNA of the liver could be considered for further definition to assess inflammatory cell type. Core biopsy is necessary for structure. If the patient appears Cushingoid then work-up for PDH is indicated. No evidence of neoplasia. Full CNS exam and thoracic radiographs are warranted given the weight loss.

Efficient & Accurate Cushing's Work up-Lindquist

Notes regarding Cushing's Clinical Presentations:

Nearly all Cushing's dogs have SAP elevations and true PU/PD (USG < 1.025) and most are polyphagic.

Cushing's dogs are > 6 years and usually > 9 years old, usually have poor skin coats, body scores > 3/5, and are usually sedentary animals.



PATIENT

Max Trepanier

SPECIES

Canine

BREED

Golden Retriever Cross

SEX

Neutered male

AGE

13 years

WEIGHT

49 lbs

INTERPRETED BY

Eric Lindquist, DMV,
DABVP, Cert. IVUSS

IMAGING PERFORMED BY

Sara Hansen

HOSPITAL NAME

Amazon Park AC

REFERRING VET

Dr. Jones

DATE

8/10/23

Invoice

46546

Its important to remember that Cushing's dogs usually look and play the part and other diseases cause false + stress related cortisol spikes. On rare occasion a Cushing's dog will not follow the rules but this is truly an exception.

Potential Cushing's patient workups can be costly and frustrating if not definitive and, in my experience, the non-definitive patient usually has something else going on that may be contributing to some of the clinical signs a Cushing's dog will have, especially SAP elevations or PU/PD. Based on this prelude of information I came up with the following algorithm in the spirit of diagnostic efficiency. The following suggested protocol is based on current available literature on Cushing's disease and extensive clinical-sonographic experience evaluation + Cushing's and False + LDDST & ACTH stim. cases in order to maximize the efficiency of a Cushing's workup in practice.

Screen first, workup second

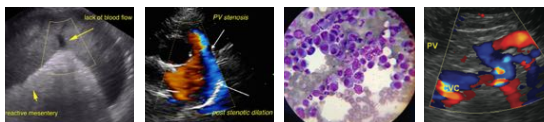
1) **UA:** Repeatable (2-3 urine samples) Urine specific gravity & urine cortisol/creatinine ratio (UCCR): If **repeatable USG < 10.20 and + UCCR** move to next step 2.

Note: UA is inexpensive and easy to obtain and if UA criteria is not met for Cushing's then resources can be spent into other more pertinent diagnostics or left on hold until the UA criteria is met in emerging Cushing's cases.

2) **Sonogram:** Does the patient **have concurrent disease** clinically or sonographically as non-Cushing's illness will influence the potential false + LDDST or even ACTH stim. The sonogram gives a global perspective of the internal health of the patient to be considered in the Cushing's workup as an assessment of concurrent disease. Is there a concurrent neoplastic process, UTI pancreatitis, mucocele....? Are the adrenals enlarged (Cushing's-PDH, stress, age related or breed variant), or atrophied (iatrogenic Cushing's or adrenal burnout), have asymmetric enlargement (Adrenal tumor, hyperplasia, adenoma, age related variant), or is there vascular invasion (Invasive pheo with false + UA criteria or adenocarcinoma or phrenic thrombosis)? The sonogram answers these questions proactively.

Address & treat concurrent disease first before performing Cushing's testing or testing will be artificially altered increasing false negatives and positives.

3) **LDDST** (0.01 D-Sodium phosphate mg/kg IV **with precise dosing******) (Better screening test but plagued with false + but considered more specific than ACTH stim) Use if there is potential early Cushing's or if adrenal asymmetry present on sonogram suspecting tumor. Use LDDST in cats at a higher dose (0.1 mg/kg IV). **Interpretation LDDST:** Look at 8-hour post first: If > 1.4 = Cushing's. Then look at 4-hour: if > 1.4 or > 50% baseline = Cushing's. 4-hour do then 8-hour spike most consistent with PDH. Flat line high constant curve without dip more consistent with tumor but can be PDH. See attached graph.



PATIENT

Max Trepanier

SPECIES

Canine

BREED

Golden Retriever Cross

SEX

Neutered male

AGE

13 years

WEIGHT

49 lbs

INTERPRETED BY

Eric Lindquist, DMV,
DABVP, Cert. IVUSS

IMAGING PERFORMED BY

Sara Hansen

HOSPITAL NAME

Amazon Park AC

REFERRING VET

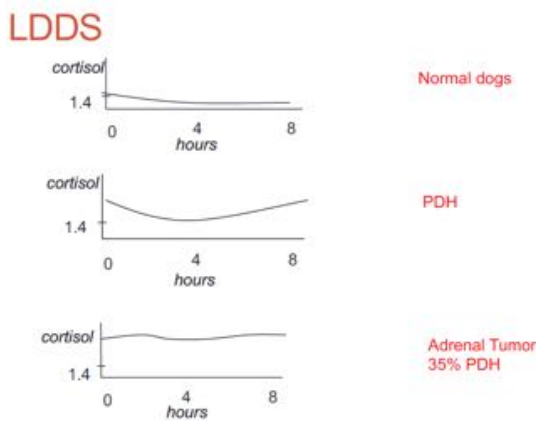
Dr. Jones

DATE

8/10/23

Invoice

46546



Courtesy: Rebecca Berg DACVIM, DECVIM

4) **ACTH stim.** (Better confirming test but can have false +) Use if the patient “looks” Cushingoid or if bilateral adrenal enlargement is present, or high normal width on sonogram, or if iatrogenic Cushing’s suspected (Cortisone Tx in past). ACTH stim is better for diagnosis of Addisons, Iatrogenic Cushing’s, and Cushing’s therapy monitoring but problematic with initial Cushing’s diagnosis. First dx LDDST is suggested.

5) If **diabetic** then run both LDDST & ACTH stim but stabilize as much as possible first.

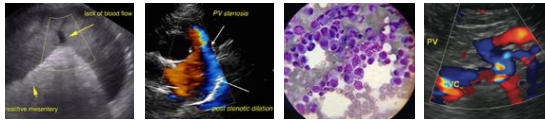
5) Run a **serial blood pressure** in a BP friendly non “white coat effect” atmosphere. Run at least 3 at different times over a few hours or when eating as the patient tends to be calm when eating or give Torbutrol when entering the facility. Cushing’s hypertension is usually 150-180 systolic range while pheochromocytoma range is more often > 180 systolic.

6) **Perform CT** of the pituitary to identify macro adenoma expansion if any lethargy or dullness or other central clinical CNS signs are minimally present. CT for adrenal may be more thorough for adrenalectomy surgical planning if ultrasound views of the CVC were problematic.

7) **Adrenectomy** for adrenal mass is prescribed then it is essential to stabilize the patient first regarding secondary disease such as organ dysfunction, hypertension, diabetes mellitus, hypernatremia, thromboembolic risk urinary and other infection in order to minimize potential for operative and postoperative complications as they are common in adrenalectomy. Trilostane stabilization therapy for Cushing’s would be the first approach then address surgery and hypertension should be managed ideally < 160 systolic with ace inhibitors, phenoxybenzamine, or amlodipine.

Suggested reading:

Behrend EN, Kooistra HS, Nelson R, et al. Diagnosis of Spontaneous Canine Hyperadrenocorticism: 2012 ACVIM Consensus Statement (Small Animal). J Vet Intern Med 2013;27:1292–1304.



PATIENT

Max Trepanier

SPECIES

Canine

BREED

Golden Retriever Cross

SEX

Neutered male

AGE

13 years

WEIGHT

49 lbs

INTERPRETED BY

Eric Lindquist, DMV,
DABVP, Cert. IVUS

IMAGING PERFORMED BY

Sara Hansen

HOSPITAL NAME

Amazon Park AC

REFERRING VET

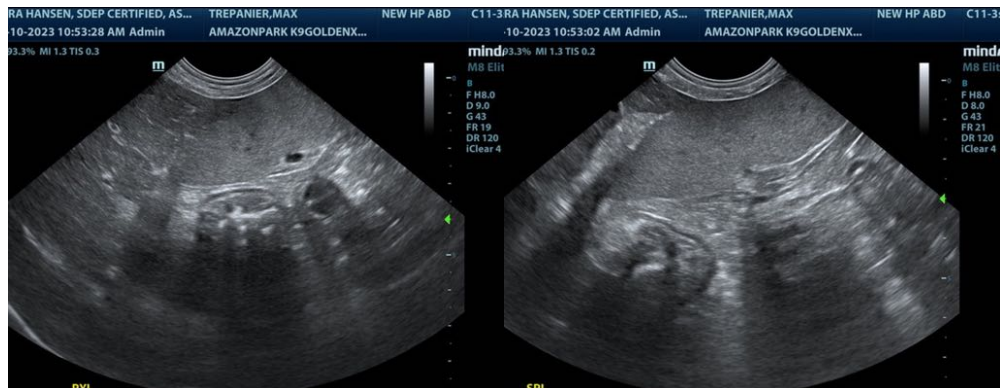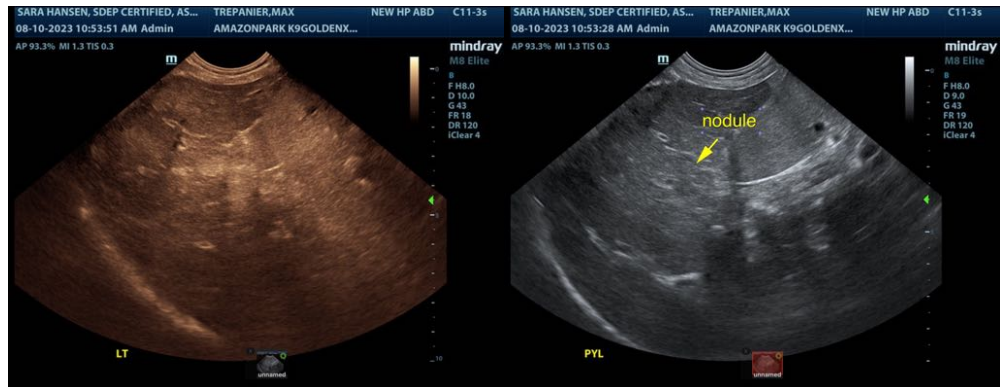
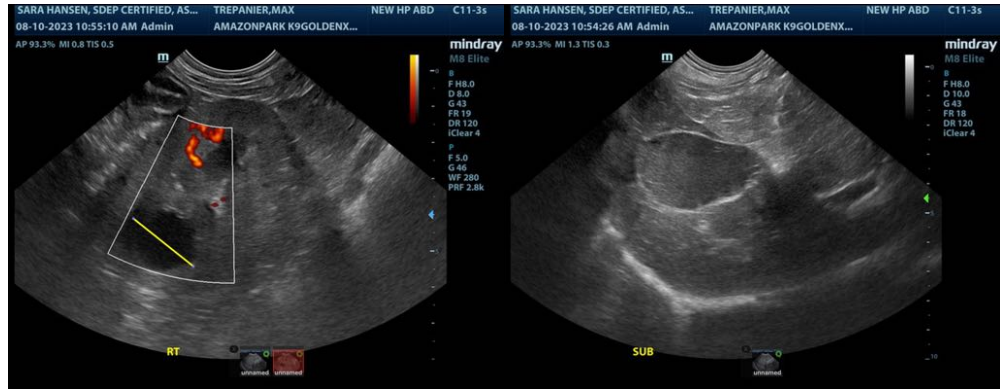
Dr. Jones

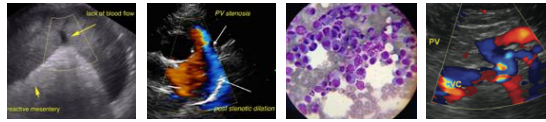
DATE

8/10/23

Invoice

46546





PATIENT

Max Trepanier

SPECIES

Canine

BREED

Golden Retriever Cross

SEX

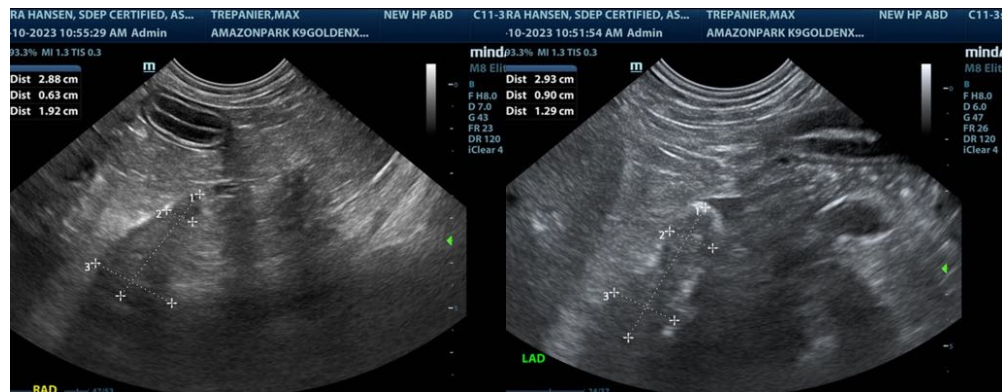
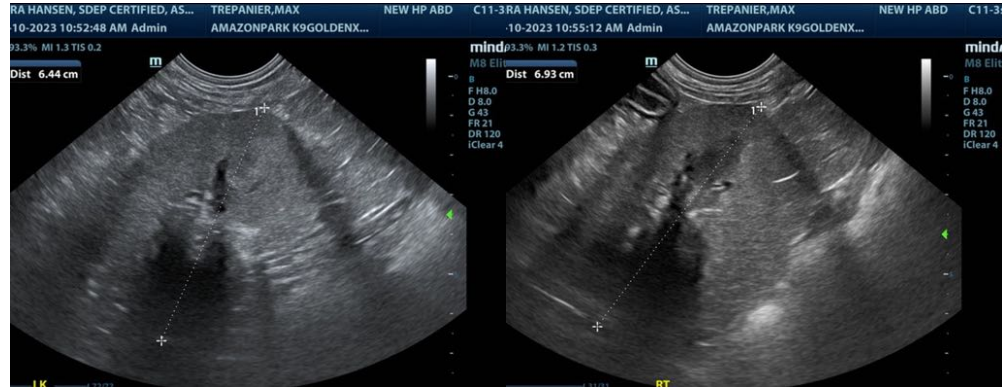
Neutered male

AGE

13 years

WEIGHT

49 lbs



INTERPRETED BY

Eric Lindquist, DMV,
DABVP, Cert. IVUSS

IMAGING PERFORMED BY

Sara Hansen

HOSPITAL NAME

Amazon Park AC

REFERRING VET

Dr. Jones

DATE

8/10/23

Invoice

46546

The information and recommendations provided are based on the images presented by the referring veterinarian/sonographer. No evaluation can be communicated regarding pathology that was not visible in the image/video clips provided.

Thank you for this referral. If the clinical or image interpretation does not parallel your findings or if I can be of any further assistance please contact me.

Eric Lindquist, DMV, DABVP, Cert. IVUSS

CEO of SonoPath.com

info@SonoPath.com