

PATIENT

Grassy Jacobson

SPECIES

Feline

BREED

Domestic Shorthair

SEX

Spayed female

AGE

11 years

WEIGHT

13.12 lbs

INTERPRETED BY

Eric Lindquist, DMV,
DABVP, Cert. IVUSS

IMAGING PERFORMED BY

Sara Hansen

HOSPITAL NAME

Hello Pets for Wellness
Center

REFERRING VET

Dr. Christensen

DATE

6/21/23

Invoice

47882

PRESENTING CLINICAL SIGNS

History: Firm mass on R hip/ileum. Painful to the touch and growing.
Abnormal PE/Chem/CBC/UA Results: ABNORMAL Laboratory Findings Radiographic findings how an area of lucency on the right ileum. Current Medications Gabapentin 10 mg/kg q8-12 hours
Radiographic Findings Radiographic findings how an area of lucency on the right ileum.

ULTRASONOGRAPHIC EXAMINATION OF THE ABDOMEN

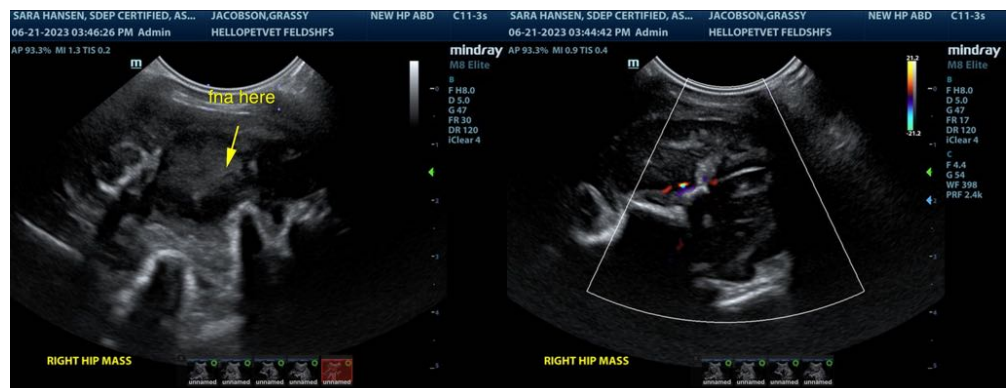
The right hip in this patient revealed a mixed, hypoechoic regionally mineralizing mass that extended up to 3.5 cm deep from the subcutaneous area into the bone with periosteal proliferation. The mass revealed ill-defined margins and extended up to 3.4 cm in width and up to 6.0 cm in width from subcutaneous tissue through the muscle and bone with areas of mineralization and moderate vascularity. This would suggest sarcoma, chondrosarcoma, fibrosarcoma are the primary concerns.

ULTRASONOGRAPHIC FINDINGS

Sarcomatous type mass with ill-defined margins and bony involvement. Periosteal proliferation and multi-focal mineralization.

INTERPRETATION OF THE FINDINGS & FURTHER RECOMMENDATIONS

Ultrasound-guided FNA of the hypoechoic portions of the mass are recommended with likely radiation +/- chemotherapy and/or surgical debulking would likely all be necessary. Abdominal sonogram and chest radiographs are warranted to assess for metastatic disease. Clean resection would be very difficult in this patient given the ill-defined margins and bony involvement. CT evaluation would be ideal.





PATIENT

Grassy Jacobson

SPECIES

Feline

BREED

Domestic Shorthair

SEX

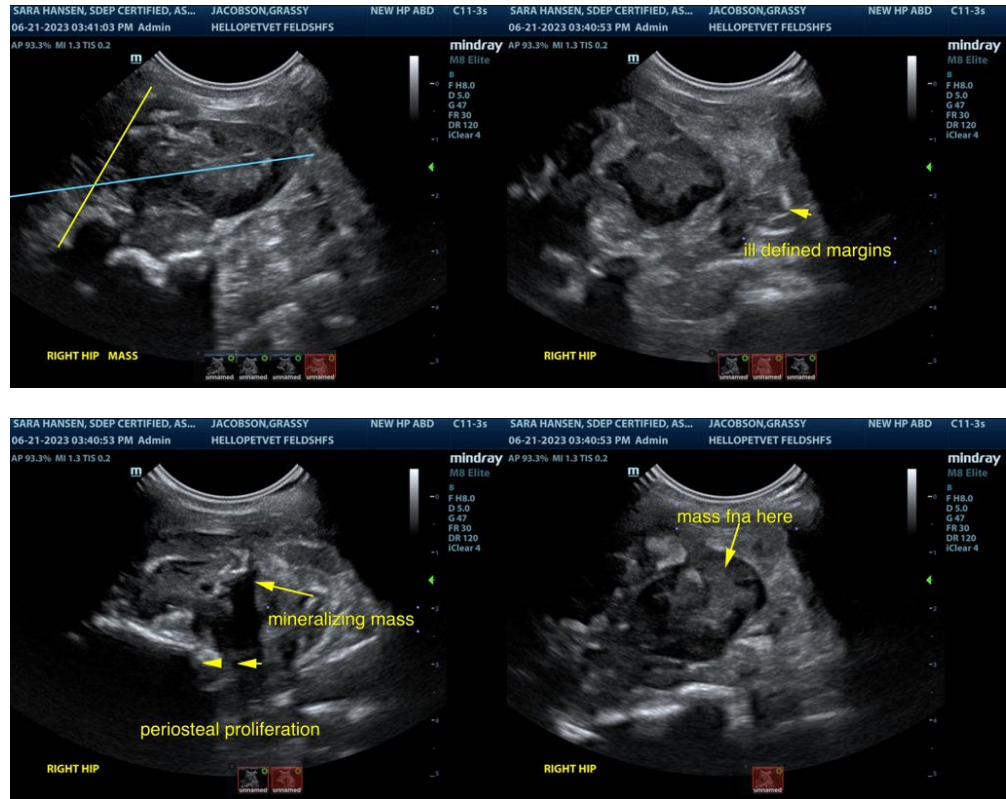
Spayed female

AGE

11 years

WEIGHT

13.12 lbs



INTERPRETED BY

Eric Lindquist, DMV,
DABVP, Cert. IVUSS

IMAGING PERFORMED BY

Sara Hansen

HOSPITAL NAME

Hello Pets for Wellness
Center

REFERRING VET

Dr. Christensen

DATE

6/21/23

Invoice

47882

The information and recommendations provided are based on the images presented by the referring veterinarian/sonographer. No evaluation can be communicated regarding pathology that was not visible in the image/video clips provided.

Thank you for this referral. If the clinical or image interpretation does not parallel your findings or if I can be of any further assistance please contact me.

Eric Lindquist, DMV, DABVP, Cert. IVUSS

CEO of Sonopath.com

Eric.Lindquist@SonoPath.com