



PATIENT PRESENTING CLINICAL SIGNS

Orlie Williams History: Cardiac murmur grade 3/6

SPECIES ULTRASONOGRAPHIC EXAMINATION OF THE HEART

Canine

BREED

Lagotto Romagnolo

SEX

Spayed Female

AGE

10 years

WEIGHT

28 lbs

INTERPRETED BY

Eric Lindquist, DMV,
DABVP, Cert. IVUSS

IMAGING PERFORMED BY

Sara Hansen

HOSPITAL NAME

Pawsitive Wellness VC

REFERRING VET

Dr. Hardy

DATE

5/10/22

Invoice
30239

ULTRASONOGRAPHIC EXAMINATION OF THE HEART

The echocardiogram in this patient demonstrated normal **left atrial** size based on 3 different LA measurement methods. Chamber volumes and echogenicity were normal. The cranial and caudal **mitral** valve leaflets presented vegetative thickening consistent with endocardiosis. Doppler indicated measurable insufficiency. The **left ventricle** presented thicknesses with linear contour and was not dilated nor restricted. The **myocardium** presented normal echogenicity without subjective evidence of significant fibrotic or ischemic disease. **Contractility** of the ventricular walls was adequate and in normal range for this patient evidenced by the fractional shortening measurement and subjective evaluation of the different regions of the myocardium. The **left ventricular outflow** tract demonstrated normal laminar flow and subjective structural integrity. The **right atrium** and auricle revealed normal size, structure and content. No evidence of masses was noted or chamber overload. **Tricuspid** valvular assessment demonstrated adequate linear morphology. The **right ventricle** was of normal size (1/3 diameter of LV), chordae structure, myocardial echogenicity and thickness. **Pulmonic** tract assessment revealed normal valve structure, laminar flow, and diameter (approx.1:1 pa/ao ratio). No visible **pericardial** or free pleura fluid was noted. No echographically detectable evidence of infiltrative disease was visible. The cranial **mediastinum and pericardial regions** were free of masses in the visible window. The hepatic veins were not dilated.

CANINE CARDIAC PARAMETERS	MR VMAX (m/s)	TR VMAX (m/s)	LA/AO (Boon method)	LA/AO (Heart Base; Swe)	FS (%)	EF (%)	EPSS (cm)
NORMAL PARAMETER	4.5-5.5	<2.7	1.3	<1.3	28-40	40-100	<0.6
PATIENT	5.0	2.21	1.0	1.3	38	69	0.1
CANINE CARDIAC PARAMETERS	HR (BPM)	AV VMAX (m/s)	PV MAX (m/s)	BODY WEIGHT	LA 2D short axis Base view (cm)	LVIDd Avg; 2D and m- mode short axis (cm)	LVIDs Avg; 2D and m- mode short axis (cm)
NORMAL PARAMETER	50-100	0.7-1.7	0.7-1.6				
PATIENT	129	2.44		28 lbs	3.7 max	3.65	

ULTRASONOGRAPHIC FINDINGS

Stage B1 valvular disease.



PATIENT

Orlie Williams

SPECIES

Canine

BREED

Lagotto Romagnolo

SEX

Spayed Female

AGE

10 years

WEIGHT

28 lbs

INTERPRETED BY

Eric Lindquist, DMV,
DABVP, Cert. IVUSS

IMAGING PERFORMED BY

Sara Hansen

HOSPITAL NAME

Pawsitive Wellness VC

REFERRING VET

Dr. Hardy

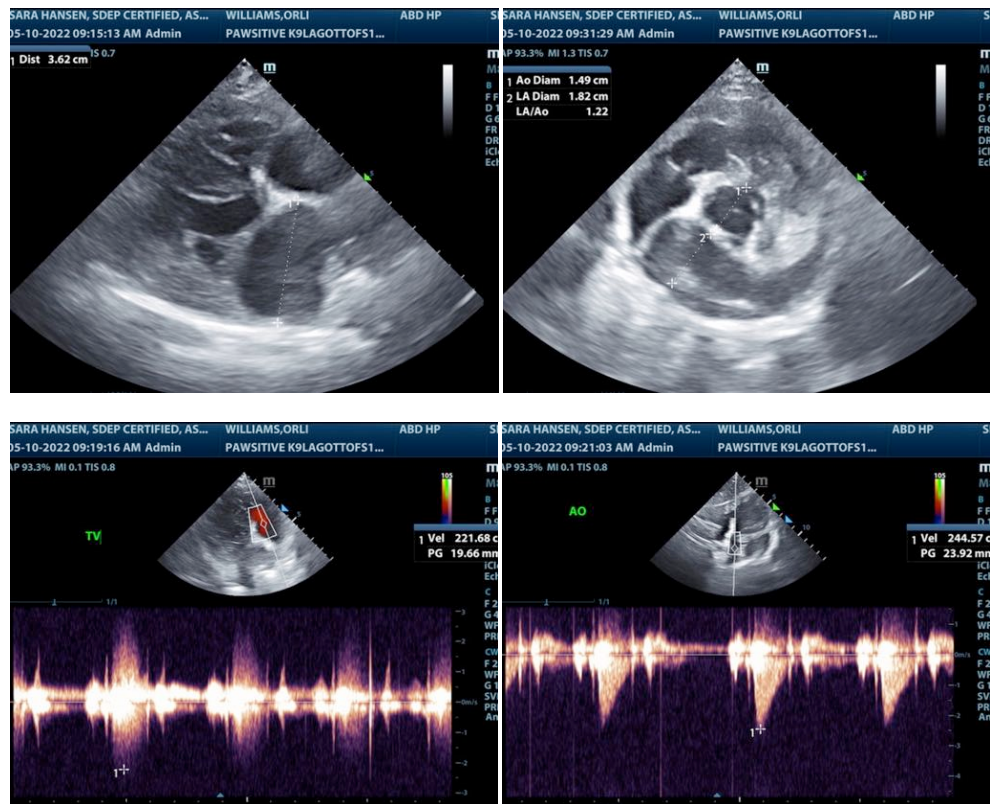
DATE

5/10/22

Invoice
30239

INTERPRETATION OF THE FINDINGS & FURTHER RECOMMENDATIONS

B1: The heart is stable without clinical disease. No overt contraindication for anesthesia of brief to moderate duration. I suggest Torbutrol premed, Propofol induction, Isoflurane maintenance or similar protocol if anesthesia is desired. Blood pressure recommended if not already performed and target white coat negative systolic pressure of < 160 mmHg. If higher than this ACE-inhibitor is suggested to reach this level. Recheck echocardiogram is recommended in 6 months, earlier if murmur grade increases or clinical signs initiate.





PATIENT

Orlie Williams

SPECIES

Canine

BREED

Lagotto Romagnolo

SEX

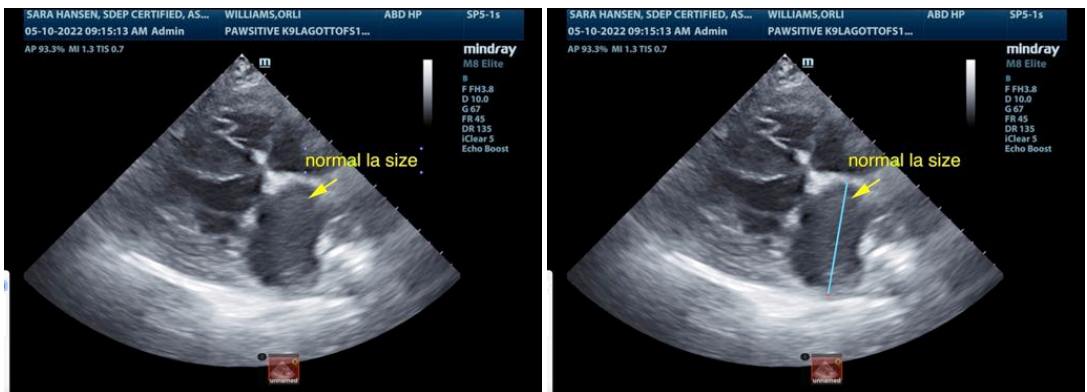
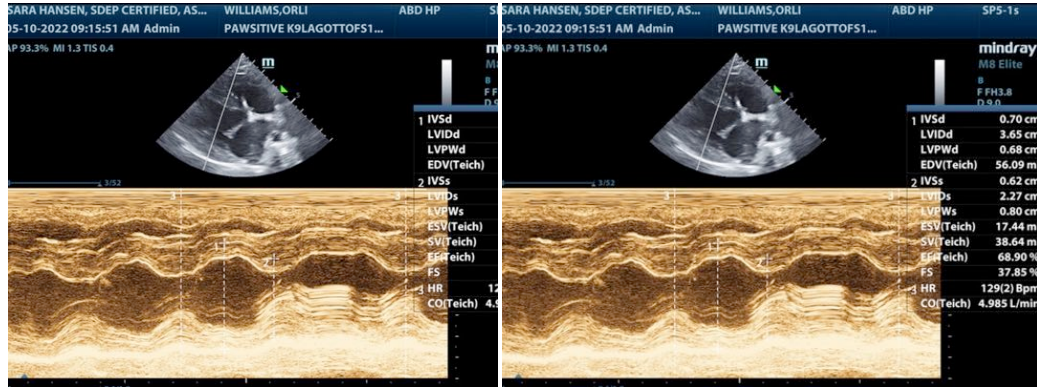
Spayed Female

AGE

10 years

WEIGHT

28 lbs



INTERPRETED BY

Eric Lindquist, DMV,
DABVP, Cert. IVUSS

IMAGING PERFORMED BY

Sara Hansen

HOSPITAL NAME

Pawsitive Wellness VC

REFERRING VET

Dr. Hardy

DATE

5/10/22

Invoice
30239

The information and recommendations provided are based on the images presented by the referring veterinarian/sonographer. No evaluation can be communicated regarding pathology that was not visible in the image/video clips provided.

Thank you for this referral. If the clinical or image interpretation does not parallel your findings or if I can be of any further assistance please contact me.

Eric Lindquist, DMV, DABVP, Cert. IVUSS

CEO of Sonopath.com

Eric.Lindquist@SonoPath.com