



PATIENT

Henry Derrickson

SPECIES

Canine

BREED

Boston Terrier

SEX

Neutered male

AGE

10 years

WEIGHT

16 lbs

INTERPRETED BY

Eric Lindquist, DMV,
DABVP, Cert. IVUSS

IMAGING PERFORMED BY

Sara Hansen

HOSPITAL NAME

Countryside Animal
Clinic

REFERRING VET

Dr. Cox

DATE

4/7/22

Invoice
98126

PRESENTING CLINICAL SIGNS

History: Presented 3/23/2022 - right side scrotal/prepuccial swelling- nodular. Does not feel painful or reducible. First noted by owner earlier in the year last year, but seems to have grown.

ULTRASONOGRAPHIC EXAMINATION OF THE ABDOMEN

Urinary System

The **urinary bladder**, trigone, and pelvic urethra presented normal thicknesses and normal tone. The pelvic urethra was imaged 3.0 cm beyond the cystourethral junction. The ureters were not visible which is normal. No uroliths or sediment were visualized and anechoic urine was present. No evidence of inflammatory or neoplastic changes was noted. Ureteral papillae were normal.

The residual prostate measured 0.6 cm. The inguinal region revealed enlarged lymph nodes that measured up to 0.8 x 0.4 cm.

The **kidneys** revealed largely normal size and structure, corticomedullary definition and ratio (cortex 1/3 of medulla) were essentially maintained with some age-related loss of curvilinear patterns regarding the capsule and C/M junction. The cortices presented largely uniform texture with some increased echogenicity expected for this age patient. Medullary structure differed distinctly from that of the cortex and no evidence of pelvic dilation was present. The right kidney measured 4.78 cm. The left kidney measured 4.83 cm.

Adrenal Glands

Both **adrenal glands** were visualized and recognized as having normal shape, size, position and echogenicity for this breed. The phrenic vasculature, glandular echogenicity and detail were unremarkable. Capsule, cortex, and medullary definition were normal for this age patient. The right adrenal gland measured 2.2 x 1.6 cm at the cranial pole and 0.57 cm at the caudal pole. The left adrenal gland measured 1.77 x 0.59 cm at the caudal pole and 0.75 cm at the cranial pole.

Spleen

The **spleen** presented a smooth homogeneous parenchyma hyperechoic to liver and renal cortical parenchyma. The capsule was smooth without noticeable expansion or deviation from within the spleen or adjacent pathology. The splenic vasculature demonstrated normal volume without signs of congestion or thrombosis. No sonographic evidence of acute or chronic inflammatory, neoplastic, or infarctual changes was noted.

Liver

The **liver** was uniformly swollen with minor, excessive gallbladder debris and over distension with dependent and suspended bile without evidence of overt mucocele formation. However, excessive sludge was present. The liver presented coarse architecture with mildly increased portal markings and subtle, mixed echogenic changes. This is consistent with vacuolar hepatopathy and some level of remodeling and history of inflammatory component. There was no overt suspicion of neoplasia.



PATIENT

Gastrointestinal

Henry Derrickson

Examination of the **gastrointestinal tract** revealed a stomach and intestine free of stasis, of normal wall thickness, acceptable curvilinear mural detail, and peristaltic activity. Small and large intestine demonstrated normal luminal chyme and stool consistency respectively. No obstructive or overt infiltrative disease was noted.

SPECIES

Canine

BREED

Boston Terrier

Pancreas

The base and limbs of the **pancreas** were observed to be largely isoechoic to surrounding omental fat. Pancreatic duct and capsular contour were acceptably normal and parenchyma respected normal curvilinear patterns. No overt evidence of active inflammatory or neoplastic disease was noted.

SEX

Neutered male

Free Abdomen

Subcutaneous undifferentiated nodules were noted. Regional inflammation was noted.

AGE

10 years

ULTRASONOGRAPHIC FINDINGS

WEIGHT

16 lbs

Subcutaneous nodules or lymph nodes with regional inflammation.

INTERPRETATION OF THE FINDINGS & FURTHER RECOMMENDATIONS

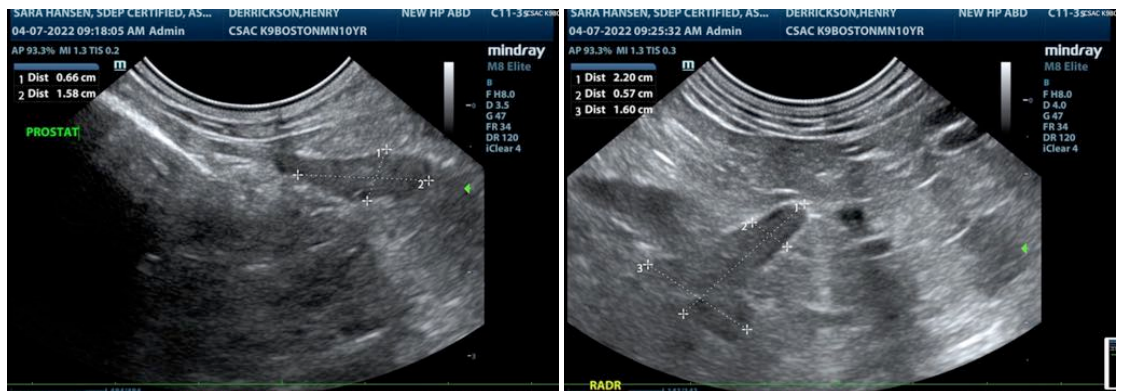
INTERPRETED BY

Ultrasound-guided FNA, culture and cytology are indicated. There was no evidence of significant pathology.

Eric Lindquist, DMV,
DABVP, Cert. IVUSS

IMAGING PERFORMED BY

Sara Hansen



HOSPITAL NAME

Countryside Animal
Clinic

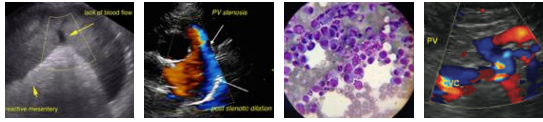
REFERRING VET

Dr. Cox

DATE

4/7/22

Invoice
98126



PATIENT

Henry Derrickson

SPECIES

Canine

BREED

Boston Terrier

SEX

Neutered male

AGE

10 years

WEIGHT

16 lbs

INTERPRETED BY

Eric Lindquist, DMV,
DABVP, Cert. IVUSS

IMAGING PERFORMED BY

Sara Hansen

HOSPITAL NAME

Countryside Animal
Clinic

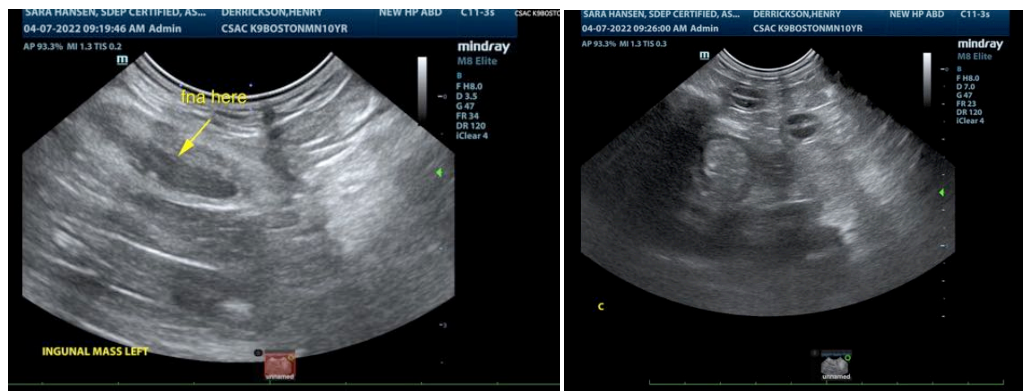
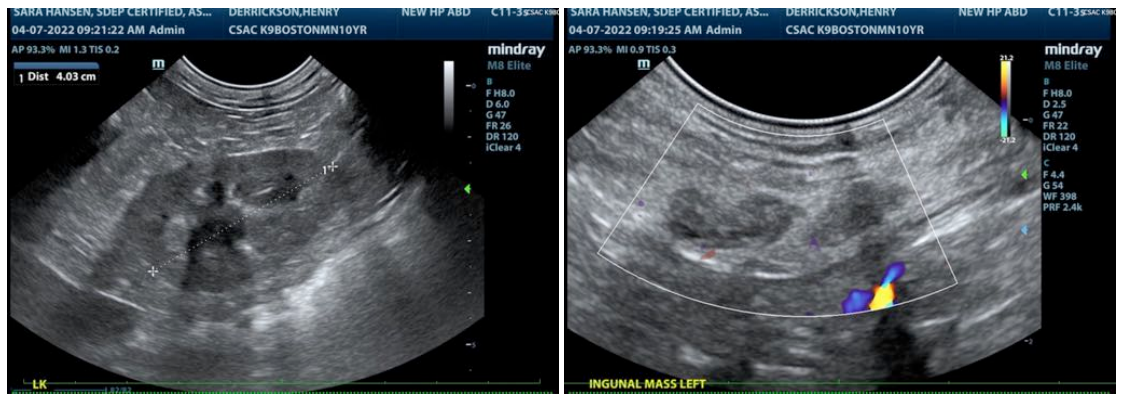
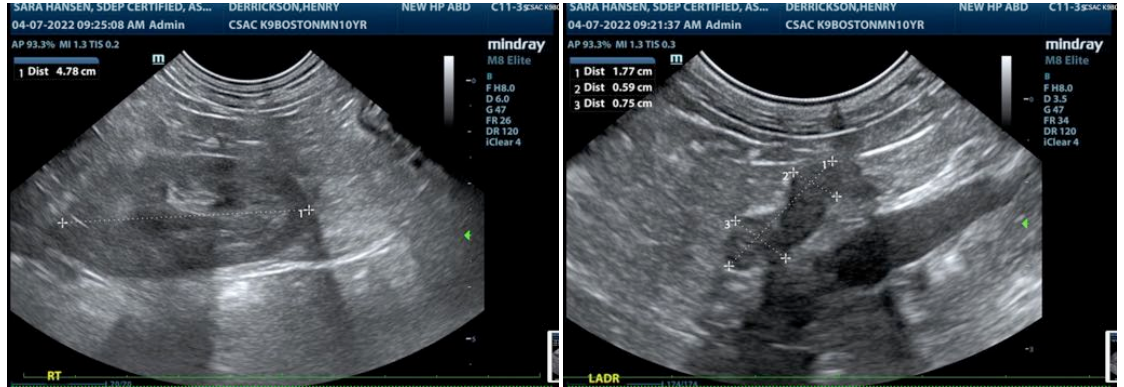
REFERRING VET

Dr. Cox

DATE

4/7/22

Invoice
98126



The information and recommendations provided are based on the images presented by the referring veterinarian/sonographer. No evaluation can be communicated regarding pathology that was not visible in the image/video clips provided.

Thank you for this referral. If the clinical or image interpretation does not parallel your findings or if I can be of any further assistance please contact me.

Eric Lindquist, DMV, DABVP, Cert. IVUSS

CEO of SonoPath.com

Eric.Lindquist@SonoPath.com