

PATIENT

Rambo Barrett

SPECIES

Canine

BREED

Weimaraner

SEX

Neutered male

AGE

5 years

WEIGHT

77.2 lbs

INTERPRETED BY

Eric Lindquist, DMV,
DABVP, Cert. IVUSS

IMAGING PERFORMED BY

Sara Hansen

HOSPITAL NAME

Echo Hollow VH

REFERRING VET

Dr. Kenna

DATE

4/6/22

Invoice
98097

PRESENTING CLINICAL SIGNS

History: weight loss crystalluria
Abnormal PE/Chem/CBC/UA Results: HCT = 57.6 H minor minor decrease WBCs Current
Medications Bravecto and Heartgard

ULTRASONOGRAPHIC EXAMINATION OF THE ABDOMEN

Urinary System

The **urinary bladder**, trigone, and pelvic urethra presented normal thicknesses and normal tone. The ureters were not visible which is normal. No uroliths or sediment were visualized and anechoic urine was present. No evidence of inflammatory or neoplastic changes was noted. Ureteral papillae were normal.

The **kidneys** revealed normal size and structure, corticomedullary definition and ratio for this age. The cortices presented largely uniform texture with normal echogenic relationship to liver and spleen. Medullary structure differed distinctly from the cortex and no evidence of pelvic dilation was present. The capsules were acceptably uniform without significant irregularities. The left kidney measured 8.06 cm. The right kidney measured 7.56 cm.

Adrenal Glands

Both **adrenal glands** were visualized and recognized as having normal shape, size, position and echogenicity for this breed. The phrenic vasculature, glandular echogenicity and detail were unremarkable. Capsule, cortex, and medullary definition were normal for this age patient. The right adrenal gland measured 3.03 x 1.32 cm at the cranial pole and 0.57 cm at the caudal pole. The left adrenal gland measured 2.9 x 0.55 cm at the caudal pole and 0.62 cm at the cranial pole.

Spleen

The **spleen** in this patient was mildly enlarged with uniform parenchyma and was folded upon itself cranially. This is a positional variant and is not pathological. There was no evidence of significant disease.

Liver

The **liver** images submitted revealed subjectively normal liver size, contour, and structure. Parenchymal echogenicity was naturally coarse and hypoechoic to the spleen. Vascular and biliary tracts were of normal volume with no evidence of congestion. The gallbladder presented acceptably thin walls with primarily anechoic content. The cystic and common bile ducts were normal. No pathological hepatic lymphadenopathy was evident. No overt structural evidence of inflammatory, infiltrative or regenerative pathology was evident.



PATIENT

Rambo Barrett

SPECIES

Canine

BREED

Weimaraner

SEX

Neutered male

AGE

5 years

WEIGHT

77.2 lbs

Gastrointestinal

Examination of the **gastrointestinal tract** revealed a stomach and intestine free of stasis, of normal wall thickness, acceptable curvilinear mural detail, and peristaltic activity. Some retention of ingesta was noted in the stomach. Soft stool was noted in the colon.

Pancreas

The base and limbs of the **pancreas** were observed to be largely isoechoic to surrounding omental fat. Pancreatic duct and capsular contour were acceptably normal and parenchyma respected normal curvilinear patterns. No overt evidence of active inflammatory or neoplastic disease was noted.

ULTRASONOGRAPHIC FINDINGS

Structurally unremarkable abdomen.

INTERPRETATION OF THE FINDINGS & FURTHER RECOMMENDATIONS

The cause of weight loss is unclear. Even though the adrenal glands appear normal baseline cortisol is indicated to rule out occult Addison's given the age of the patient and vague clinical signs.

INTERPRETED BY

Eric Lindquist, DMV,
DABVP, Cert. IVUSS

IMAGING PERFORMED BY

Sara Hansen

HOSPITAL NAME

Echo Hollow VH

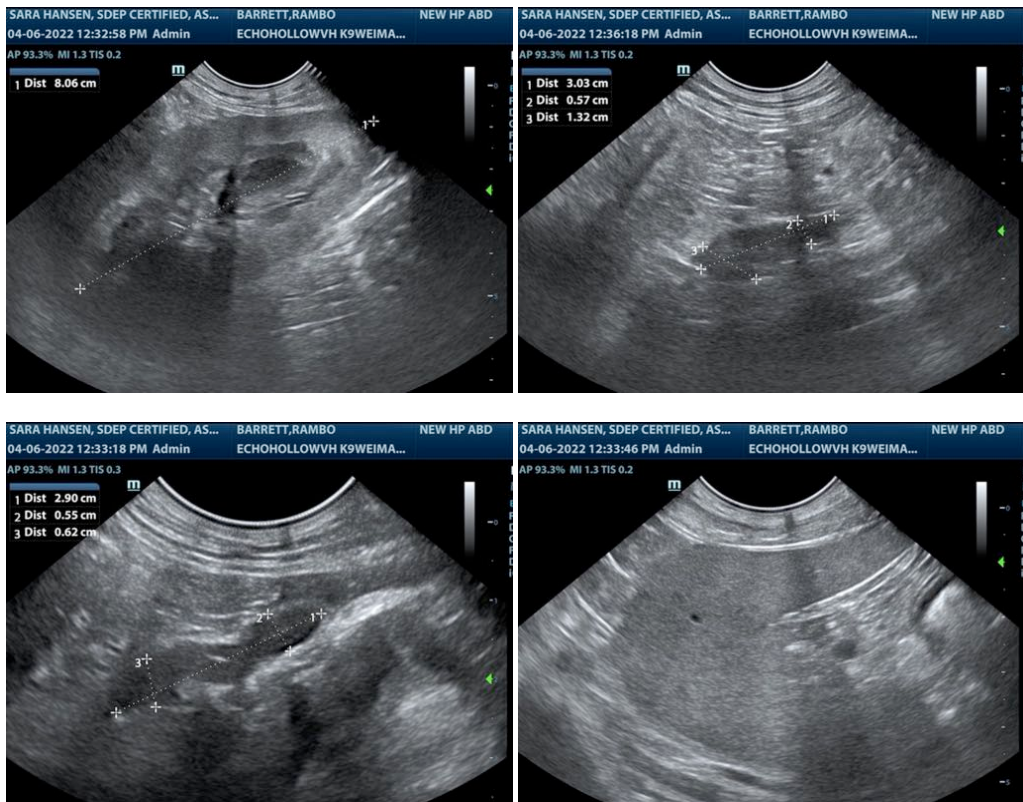
REFERRING VET

Dr. Kenna

DATE

4/6/22

Invoice
98097





PATIENT

Rambo Barrett

SPECIES

Canine

BREED

Weimaraner

SEX

Neutered male

AGE

5 years

WEIGHT

77.2 lbs

INTERPRETED BY

Eric Lindquist, DMV,
DABVP, Cert. IVUSS

IMAGING PERFORMED BY

Sara Hansen

HOSPITAL NAME

Echo Hollow VH

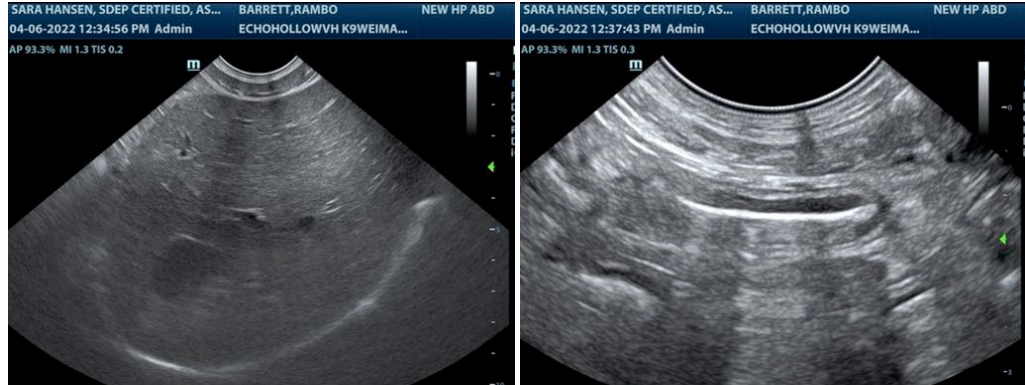
REFERRING VET

Dr. Kenna

DATE

4/6/22

Invoice
98097



The information and recommendations provided are based on the images presented by the referring veterinarian/sonographer. No evaluation can be communicated regarding pathology that was not visible in the image/video clips provided.

Thank you for this referral. If the clinical or image interpretation does not parallel your findings or if I can be of any further assistance please contact me.

Eric Lindquist, DMV, DABVP, Cert. IVUSS

CEO of Sonopath.com

Eric.Lindquist@SonoPath.com