



PATIENT

Yoda Arico

SPECIES

Feline

BREED

Domestic Shorthair

SEX

Neutered male

AGE

12 years

WEIGHT

13.6 lbs

INTERPRETED BY

Eric Lindquist, DMV,
DABVP, Cert. IVUSS

IMAGING PERFORMED BY

Sara Hansen

HOSPITAL NAME

Eastgate VC

REFERRING VET

Dr. Herdener

DATE

3/8/22

Invoice
96661

PRESENTING CLINICAL SIGNS

History: - Crackles/wheezes on thoracic auscultation (chronic, >1 yr hx of consolidated R middle lung lobe) - 3/6 Sternal systolic heart murmur - History of self trauma to digits when not on Prednisolone - Hind limb weakness/lameness, improving since started on pain meds (Gabapentin, Buprenex) - Lumbosacral chronic intervertebral disc degeneration with spondylosis deformans

ULTRASONOGRAPHIC EXAMINATION

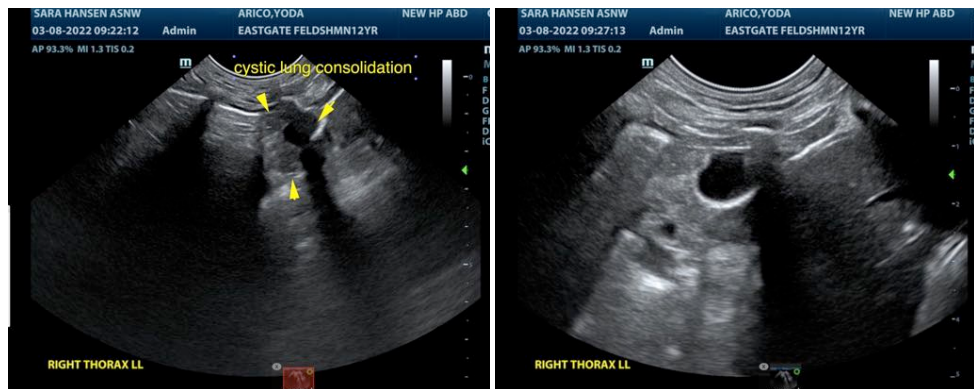
A 2.0 x 2.0 cm, mixed echogenic and cystic lung consolidation was noted adjacent to the heart. This appears to be very passive. There was no evidence of inflammation present. This is likely sequelae from prior insult. The cystic portion has minor echogenic debris with a possibility of localized infection. There is a minor potential for neoplasia such as carcinoma.

ULTRASONOGRAPHIC FINDINGS

Subjectively benign cystic lung consolidation, likely secondary to prior episodes of bronchial disease, possible low-grade imbedded infection.

INTERPRETATION OF THE FINDINGS & FURTHER RECOMMENDATIONS

The lung consolidation appears potentially resectable with thoracotomy as the lesion is adjacent to the heart and is only 40-50% parenchymal, the remainder is cystic.



The information and recommendations provided are based on the images presented by the referring veterinarian/sonographer. No evaluation can be communicated regarding pathology that was not visible in the image/video clips provided.

Thank you for this referral. If the clinical or image interpretation does not parallel your findings or if I can be of any further assistance please contact me.



PATIENT

Eric Lindquist, DMV, DABVP, Cert. IVUSS

Yoda Arico

CEO of Sonopath.com

Eric.Lindquist@SonoPath.com

SPECIES

Feline

BREED

Domestic Shorthair

SEX

Neutered male

AGE

12 years

WEIGHT

13.6 lbs

INTERPRETED BY

**Eric Lindquist, DMV,
DABVP, Cert. IVUSS**

**IMAGING
PERFORMED BY**

Sara Hansen

HOSPITAL NAME

Eastgate VC

REFERRING VET

Dr. Herdener

DATE

3/8/22

Invoice
96661