



PATIENT

Tank Bushman

SPECIES

Canine

BREED

Pit Bull Mix

SEX

Neutered male

AGE

7 years

WEIGHT

90.9 lbs

INTERPRETED BY

Eric Lindquist, DMV,
DABVP, Cert. IVUSS

IMAGING PERFORMED BY

Sara Hansen

HOSPITAL NAME

Countryside Animal
Clinic

REFERRING VET

Dr. Cox

DATE

3/29/23

Invoice
43621

PRESENTING CLINICAL SIGNS

History: weight loss distended abdomen, megly small skin tag just below the right eye mild scleral injection of the left eye, mild entropion dental disease, worn, broken teeth otitis externa - bilateral joint disease

Abnormal PE/Chem/CBC/UA Results: Senior Screen 1/31/2023: Mild lymphopenia SDMA = 17, Phos= 2.4, Ca high at 12.3 Urinalysis: spgr 1.010, ph = 8, 1+ protein T4 is wnl at 2.2 Parathyroid Hormone, Ionized Calcium 2/10/2023 i Ca = 1.64 PTH = 13 Current Medications No current medications

ULTRASONOGRAPHIC EXAMINATION OF THE THYROID

The cervical region was imaged in this patient. The trachea, esophagus, salivary glands and regional tissues were all normal. The left thyroid lobe was uniform with minor, heterogenous parenchymal changes with normal parathyroids measuring up to 0.2 cm. The left thyroid measured 0.5 cm in width. The right thyroid lobe measured 0.5 cm in width with a focal, hypoechoic 0.5 x 0.4 cm nodule in the midbody of the thyroid lobe. This is consistent with parathyroid adenoma.

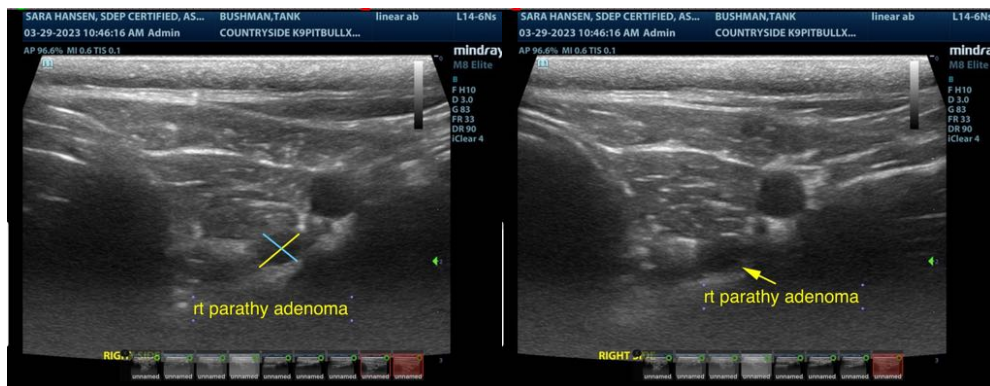
ULTRASONOGRAPHIC FINDINGS

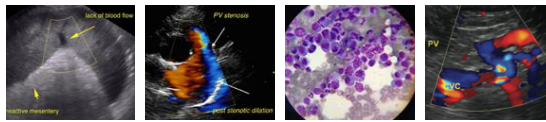
Right medial parathyroid adenoma, consistent with primary hyperparathyroidism.

Normal regional tissues.

INTERPRETATION OF THE FINDINGS & FURTHER RECOMMENDATIONS

Surgical intervention is recommended.





PATIENT

Tank Bushman

SPECIES

Canine

BREED

Pit Bull Mix

SEX

Neutered male

AGE

7 years

WEIGHT

90.9 lbs

INTERPRETED BY

Eric Lindquist, DMV,
DABVP, Cert. IVUSS

IMAGING PERFORMED BY

Sara Hansen

HOSPITAL NAME

Countryside Animal
Clinic

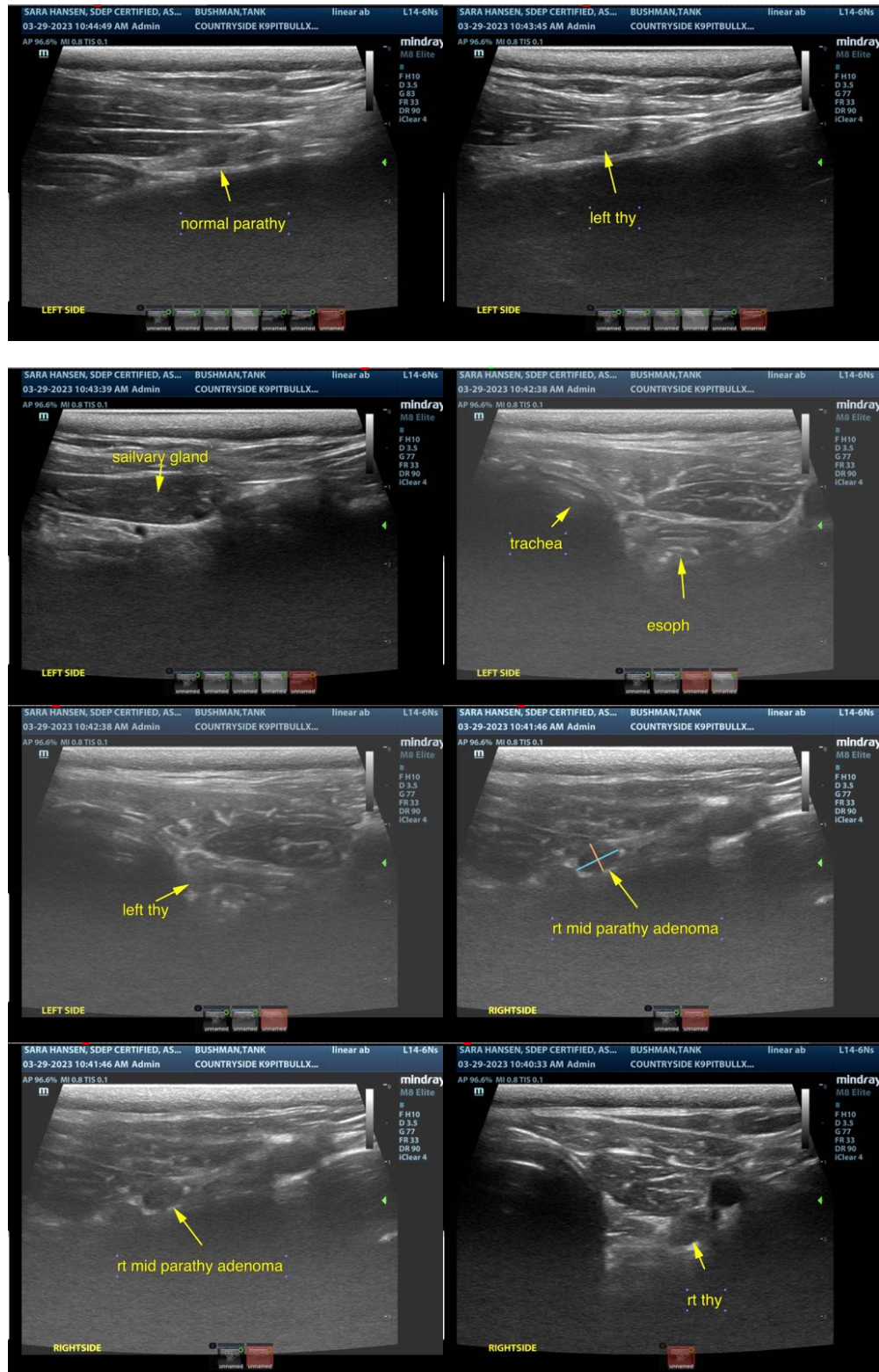
REFERRING VET

Dr. Cox

DATE

3/29/23

Invoice
43621





PATIENT

Tank Bushman

SPECIES

Canine

BREED

Pit Bull Mix

SEX

Neutered male

AGE

7 years

WEIGHT

90.9 lbs

INTERPRETED BY

**Eric Lindquist, DMV,
DABVP, Cert. IVUSS**

**IMAGING
PERFORMED BY**

Sara Hansen

HOSPITAL NAME

Countryside Animal
Clinic

REFERRING VET

Dr. Cox

DATE

3/29/23

Invoice
43621

The information and recommendations provided are based on the images presented by the referring veterinarian/sonographer. No evaluation can be communicated regarding pathology that was not visible in the image/video clips provided.

Thank you for this referral. If the clinical or image interpretation does not parallel your findings or if I can be of any further assistance please contact me.

Eric Lindquist, DMV, DABVP, Cert. IVUSS

CEO of SonoPath.com

Eric.Lindquist@SonoPath.com