



PATIENT PRESENTING CLINICAL SIGNS

Lady Witt

History: *3 month recheck post previous thyroid US, no new history since last ultrasound* previous history: -seen 10/22 for senior exam, abd palpation non-diagnostic, tense pt, obese -coxofemoral joint reduced ROM, stifle joint reduced ROM and crepitus -sensitivity in hind end, slow to rise, otherwise fairly normal PE -after labs there was concern for hyperparathyroidism, recc US

SPECIES

Canine

BREED

Lhasa Apso

SEX

Spayed female

AGE

9 years

WEIGHT

19.5 lbs

ULTRASONOGRAPHIC EXAMINATION

The left thyroid lobe revealed a moderate amount of remodeling. The thyroid lobe itself measured 0.3 cm in width. The largest medial parathyroid measured 0.32 cm. The cranial parathyroid measured 0.4 x 0.15 cm. These are most consistent with parathyroid hyperplasia and thyroid remodeling. Regional tissue such as subcutaneous space, lymph nodes and salivary glands appear to be unremarkable. The right thyroid lobe presented remodeling with uniform parenchyma. The right thyroid lobe revealed the largest parathyroid measuring 0.34 cm in the mid body. The remainder of the parathyroids were smaller and unremarkable. There was no evidence of pathology. The esophagus, carotid, and salivary glands were all normal.

ULTRASONOGRAPHIC FINDINGS

Thyroid remodeling.

Bilateral prominent parathyroids. Most consistent with parathyroid hyperplasia.

INTERPRETED BY

Eric Lindquist, DMV,
DABVP, Cert. IVUSS

INTERPRETATION OF THE FINDINGS & FURTHER RECOMMENDATIONS

If the patient has clinical signs of hypothyroidism then full thyroid profile is indicated. Repeat of the full hypercalcemia panel is indicated in light of the clinical signs. There was no progression from the prior sonogram.

IMAGING PERFORMED BY

Jenna Walsh, CVT

HOSPITAL NAME

VCA Westmoreland
AH

REFERRING VET

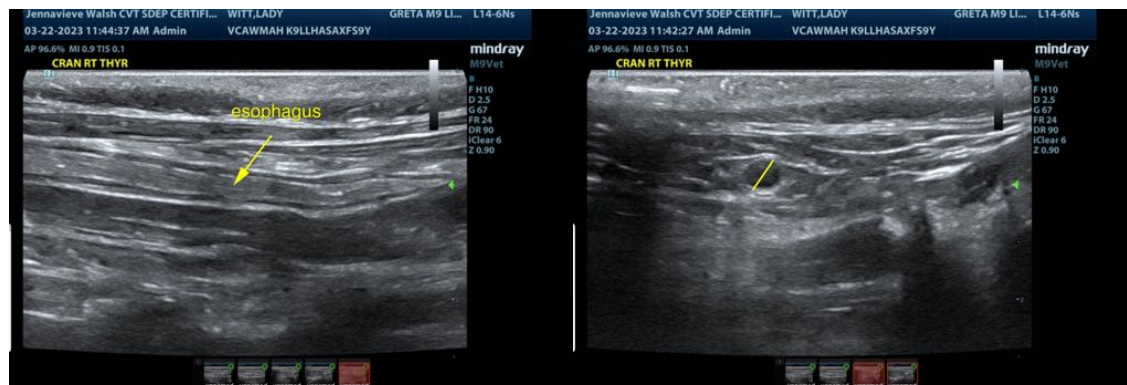
Dr. Sullivan

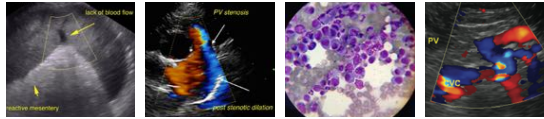
DATE

3/22/23

Invoice

43465





PATIENT

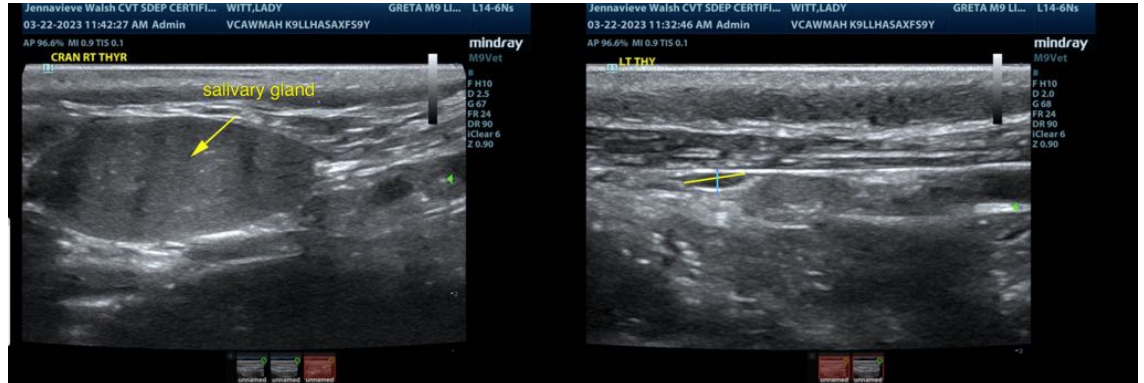
Lady Witt

SPECIES

Canine

BREED

Lhasa Apso



SEX

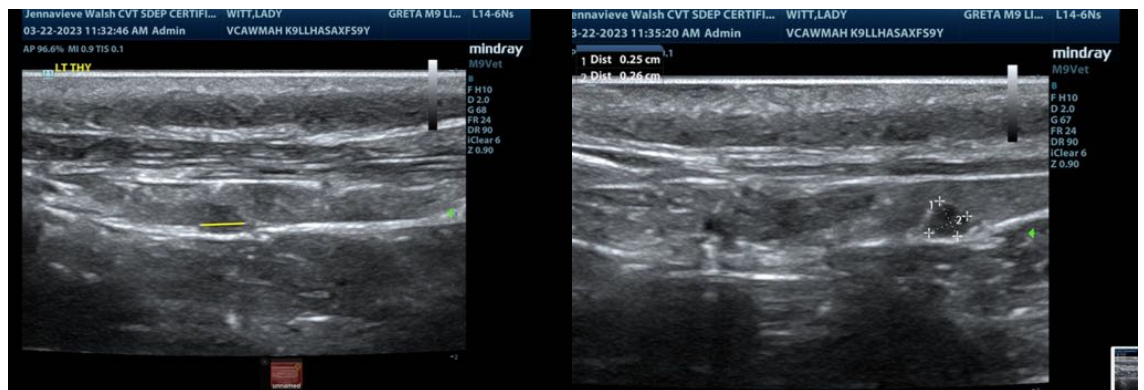
Spayed female

AGE

9 years

WEIGHT

19.5 lbs



INTERPRETED BY

Eric Lindquist, DMV,
DABVP, Cert. IVUSS

IMAGING PERFORMED BY

Jenna Walsh, CVT

HOSPITAL NAME

VCA Westmoreland
AH

REFERRING VET

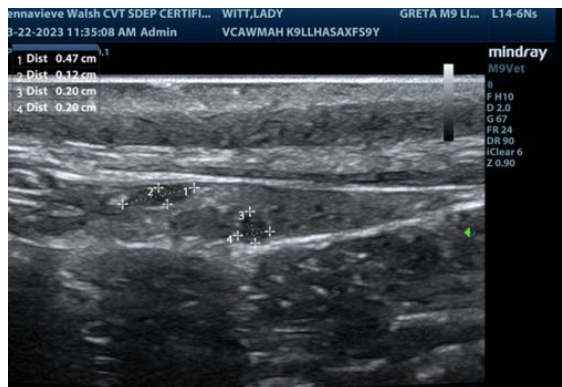Dr. Sullivan

DATE

3/22/23

Invoice

43465



The information and recommendations provided are based on the images presented by the referring veterinarian/sonographer. No evaluation can be communicated regarding pathology that was not visible in the image/video clips provided.

Thank you for this referral. If the clinical or image interpretation does not parallel your findings or if I can be of any further assistance please contact me.

Eric Lindquist, DMV, DABVP, Cert. IVUSS

CEO of Sonopath.com



PATIENT Eric.Lindquist@SonoPath.com

Lady Witt

SPECIES

Canine

BREED

Lhasa Apso

SEX

Spayed female

AGE

9 years

WEIGHT

19.5 lbs

INTERPRETED BY

Eric Lindquist, DMV,
DABVP, Cert. IVUSS

**IMAGING
PERFORMED BY**

Jenna Walsh, CVT

HOSPITAL NAME

VCA Westmoreland
AH

REFERRING VET

Dr. Sullivan

DATE

3/22/23

Invoice

43465