

PATIENT PRESENTING CLINICAL SIGNS

Lady Witt

SPECIES

Canine

BREED

Lhasa Apso Cross

SEX

Spayed female

AGE

9 years

WEIGHT

19.5 lbs

History: *3 month recheck post previous thyroid US, no new history since last ultrasound* previous history: -seen 10/22 for senior exam, abd palpation non-diagnostic, tense pt, obese -coxofemoral joint reduced ROM, stifle joint reduced ROM and crepitus -sensitivity in hind end, slow to rise, otherwise fairly normal PE -after labs there was concern for hyperparathyroidism, rec US Current Medications possibly welactin or carprofen Primary Question/Differential to Be Answered in This Exam is there any changes noticed compared to previous thyroid US from 3 months ago, is there anything abnormal found on US?

ULTRASONOGRAPHIC EXAMINATION OF THE THYROID

The left cranial parathyroid nodule in this patient has increased in size and measures 0.51 x 0.37 cm. Thyroid remodeling was noted.

Submandibular lymph nodes are slightly enlarged and measured 1.0 cm in length. Regional tissues are unremarkable.

The salivary gland was unremarkable.

ULTRASONOGRAPHIC FINDINGS

Parathyroid nodule/adenoma or hyperplastic nodule increased to 0.5 cm.

INTERPRETATION OF THE FINDINGS & FURTHER RECOMMENDATIONS

If primary hypercalcemia is present in this patient's history then left parathyroidectomy is indicated. FNA can be considered for confirmation.

INTERPRETED BY

Eric Lindquist, DMV,
DABVP, Cert. IVUSS

IMAGING PERFORMED BY

Jenna Walsh, CVT

HOSPITAL NAME

VCA Westmoreland
AH

REFERRING VET

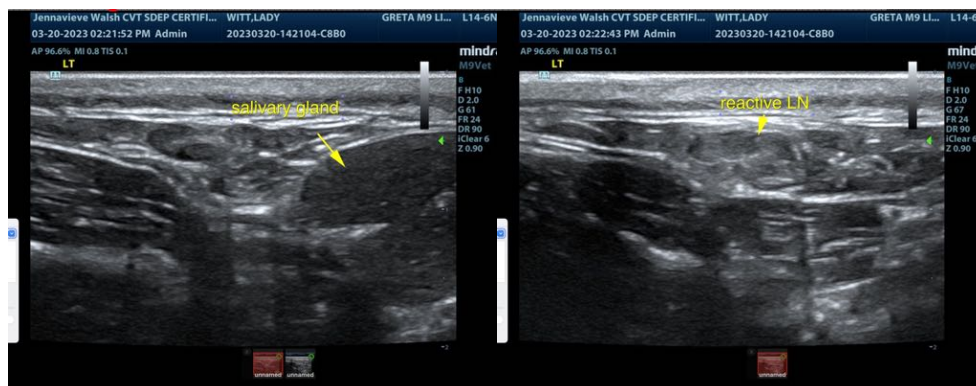
Dr. Sullivan

DATE

3/20/23

Invoice

43362





PATIENT

Lady Witt

SPECIES

Canine

BREED

Lhasa Apso Cross

SEX

Spayed female

AGE

9 years

WEIGHT

19.5 lbs

INTERPRETED BY

Eric Lindquist, DMV,
DABVP, Cert. IVUSS

IMAGING PERFORMED BY

Jenna Walsh, CVT

HOSPITAL NAME

VCA Westmoreland
AH

REFERRING VET

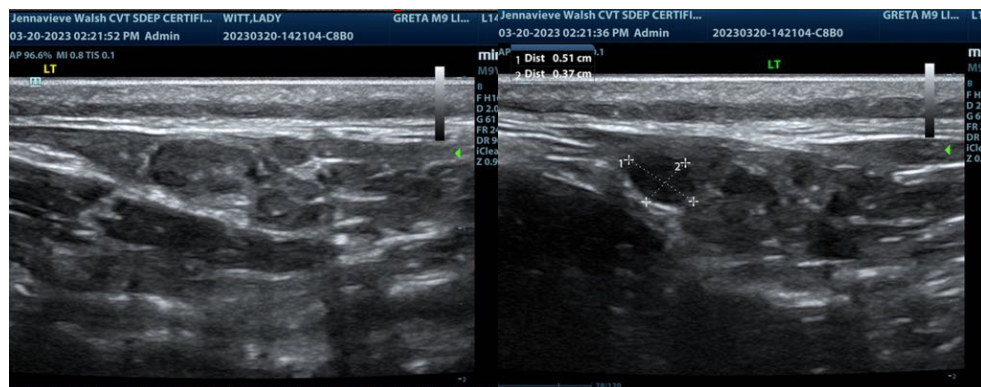
Dr. Sullivan

DATE

3/20/23

Invoice

43362



The information and recommendations provided are based on the images presented by the referring veterinarian/sonographer. No evaluation can be communicated regarding pathology that was not visible in the image/video clips provided.

Thank you for this referral. If the clinical or image interpretation does not parallel your findings or if I can be of any further assistance please contact me.

Eric Lindquist, DMV, DABVP, Cert. IVUSS

CEO of Sonopath.com

Eric.Lindquist@SonoPath.com