



PATIENT

Beckett Dickey

SPECIES

Canine

BREED

Bichon Frise

SEX

Neutered male

AGE

6 years

WEIGHT

18 lbs

INTERPRETED BY

Eric Lindquist, DMV,
DABVP, Cert. IVUSS

IMAGING PERFORMED BY

Sara Hansen

HOSPITAL NAME

Ark AH

REFERRING VET

Dr. Jackson

PRESENTING CLINICAL SIGNS

History: Systolic clicking auscultated on PE on 2/16/22 for pre dental check. No other relevant information in history or PE. No related clinical signs to cardiac disease per O.

Abnormal PE/Chem/CBC/UA Results: Presurgical bloodwork and HWT WNL, ECG revealed sinus rhythm and R wave amplitude increase. Heart Rate and Respiratory Rates 120- 80 -130

ULTRASONOGRAPHIC EXAMINATION OF THE HEART

The echocardiogram in this patient demonstrated normal **left atrial** size based on 3 separate methods of LA evaluation. The cranial and caudal **mitral** valve leaflets presented normal linear structure, extension in systole, and union in diastole with normal kinesis. The **left ventricle** presented thicknesses with linear contour and was not dilated nor restricted. The **myocardium** presented normal echogenicity without subjective evidence of significant fibrotic or ischemic disease. **Contractility** of the ventricular walls was adequate and in normal range for this patient evidenced by the fractional shortening measurement and subjective evaluation of the different regions of the myocardium. The **left ventricular outflow** tract demonstrated normal laminar flow and subjective structural integrity. The **right atrium** and auricle revealed normal size, structure and content. No evidence of masses was noted. **Tricuspid** valvular assessment demonstrated adequate linear morphology and kinesis. The **right ventricle** was of normal size (1/3 diameter of LV), chordae structure, myocardial echogenicity and thickness. **Pulmonary outflow** tract assessment revealed normal valve structure, laminar flow, and diameter (approx. 1:1 pa/ao ratio). No visible **pericardial** or free pleura fluid was noted. The cranial **mediastinum and pericardial and extra-cardiac regions** were free of masses in the visible window. Sweep of the liver revealed unremarkable vasculature. There was no evidence of passive congestion.

CANINE CARDIAC PARAMETERS	MR VMAX (m/s)	TR VMAX (m/s)	LA/AO (Boon method)	LA/AO (Heart Base; Swe)	FS (%)	EF (%)	EPSS (cm)
NORMAL PARAMETER	4.5-5.5	<2.7	1.3	<1.6	28-40	40-100	<0.6
PATIENT			1.2	1.4	35	90	NM
CANINE CARDIAC PARAMETERS	HR (BPM)	AV VMAX (m/s)	PV MAX (m/s)	BODY WEIGHT	LA (2D short axis Base view) (cm)	LVIDd (Avg; 2D and m-mode short axis) (cm)	LVIDs (Avg; 2D and m-mode short axis) (cm)
NORMAL PARAMETER	50-100	0.7-1.7	0.7-1.6				
PATIENT		1.59	1.07	18 lbs	2.02	2.2	

DATE

3/1/22

Invoice
96519

ULTRASONOGRAPHIC FINDINGS

Normal echocardiogram.



PATIENT

Beckett Dickey

INTERPRETATION OF THE FINDINGS & FURTHER RECOMMENDATIONS

There is no contraindication to anesthetic procedure.

SPECIES

Canine

BREED

Bichon Frise

SEX

Neutered male

AGE

6 years

WEIGHT

18 lbs

INTERPRETED BY

Eric Lindquist, DMV,
DABVP, Cert. IVUSS

IMAGING PERFORMED BY

Sara Hansen

HOSPITAL NAME

Ark AH

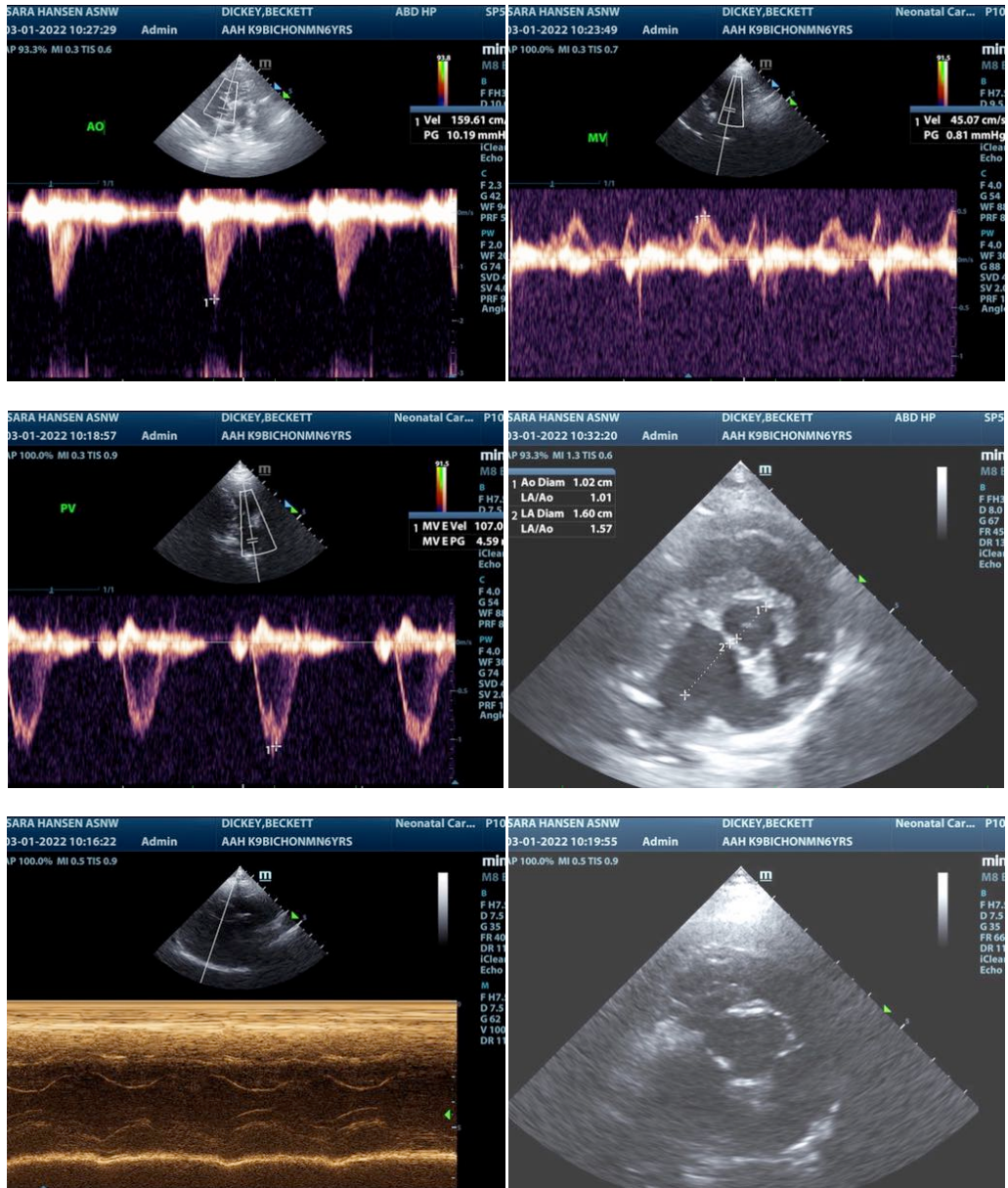
REFERRING VET

Dr. Jackson

DATE

3/1/22

Invoice
96519





PATIENT

Beckett Dickey

SPECIES

Canine

BREED

Bichon Frise

SEX

Neutered male

AGE

6 years

WEIGHT

18 lbs

INTERPRETED BY

Eric Lindquist, DMV,
DABVP, Cert. IVUSS

IMAGING PERFORMED BY

Sara Hansen

HOSPITAL NAME

Ark AH

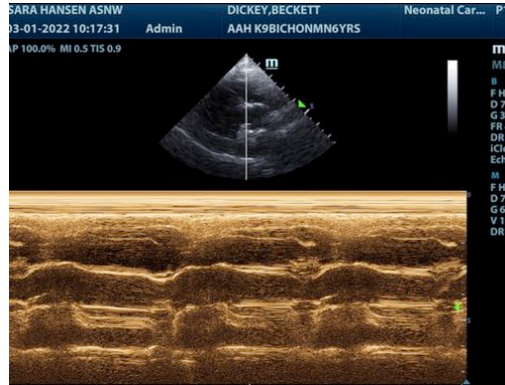
REFERRING VET

Dr. Jackson

DATE

3/1/22

Invoice
96519



The information and recommendations provided are based on the images presented by the referring veterinarian/sonographer. No evaluation can be communicated regarding pathology that was not visible in the image/video clips provided.

Thank you for this referral. If the clinical or image interpretation does not parallel your findings or if I can be of any further assistance please contact me.

Eric Lindquist, DMV, DABVP, Cert. IVUSS

CEO of SonoPath.com

Eric.Lindquist@SonoPath.com