



PATIENT PRESENTING CLINICAL SIGNS

Kaluah Damron NA Ultrasound done during echo lab

SPECIES ULTRASONOGRAPHIC EXAMINATION OF THE HEART

Feline

The echocardiogram in this patient demonstrated **mitral** valve insufficiency with an eccentric jet and normal **left atrial** size. The **left ventricle** presented normal thicknesses with linear contour and was not dilated nor restricted. Mild **myocardial** remodeling was noted. **Contractility** of the ventricular walls was adequate and in normal range for this patient evidenced by the fractional shortening measurement and subjective evaluation of the different regions and angles of the myocardium. The **left ventricular outflow** tract demonstrated normal laminar flow and subjective structural integrity. The **right atrium** and auricle revealed normal size, structure and content. No evidence of masses was noted or chamber overload. **Tricuspid** insufficiency was noted at 2.16 m/sec. The **right ventricle** was of normal size (1/3 diameter of LV), chordae structure, myocardial echogenicity and thickness. **Pulmonic** tract assessment revealed normal valve structure, laminar flow, and diameter (approx.1:1 pa/ao ratio). No visible **pericardial** or free pleura fluid was noted or extra cardiac pathology in the visible planes. The cranial **mediastinum** and **pericardial** regions were free of masses in the visible window.

BREED

Domestic Medium Hair

SEX

Spayed Female

AGE

1 ½ years

WEIGHT

INTERPRETED BY

Eric Lindquist, DMV,
DABVP, Cert. IVUSS

IMAGING PERFORMED BY

Jenna Walsh, CVT

HOSPITAL NAME

FELINE CARDIAC PARAMETERS	BODY WEIGHT (kg)	HR (BPM)	IVSd (cm)	LVIDd (cm)	LVWd (cm)	FS (%)	EF (%)
NORMAL PARAMETER	-----	150-240	0.3-0.6	1.0-2.1	0.25-0.6	35-67	80-100
PATIENT		NM	0.55	1.12	0.49	76	98
FELINE CARDIAC PARAMETERS	LA/AO (Boon)	LA/AO HEART BASE (Sisson)	LA 2D 4-chamber long axis AS to FW (Sisson) (cm)	LVOT VEL. (m/s)	RVOT VEL. (m/s)	IVRT (m/)	
NORMAL PARAMETER	<1.5	0.88-1.79	0.7-1.7	<1.6	<1.3	40-60	
PATIENT		1.25		1.2	1.21	NM	
Adapted from June Boon, Veterinary Echocardiography, 1998 Sisson D et al. JVIM 1991; 5: 232, Jacobs et al. Am J Vet Res 1985; 46:1705							

ULTRASONOGRAPHIC FINDINGS

Mitral and tricuspid insufficiency with myocardial remodeling.

REFERRING VET

**

DATE

2/7/22

Invoice
95298

INTERPRETATION OF THE FINDINGS & FURTHER RECOMMENDATIONS

No volume overload was noted and no treatment is necessary at this time. A recheck echocardiogram is recommended in 6-12 months or earlier if murmur grade increases or if clinical signs initiate.



PATIENT

Kaluah Damron

SPECIES

Feline

BREED

Domestic Medium Hair

SEX

Spayed Female

AGE

1 ½ years

WEIGHT

INTERPRETED BY

Eric Lindquist, DMV,
DABVP, Cert. IVUSS

IMAGING PERFORMED BY

Jenna Walsh, CVT

HOSPITAL NAME

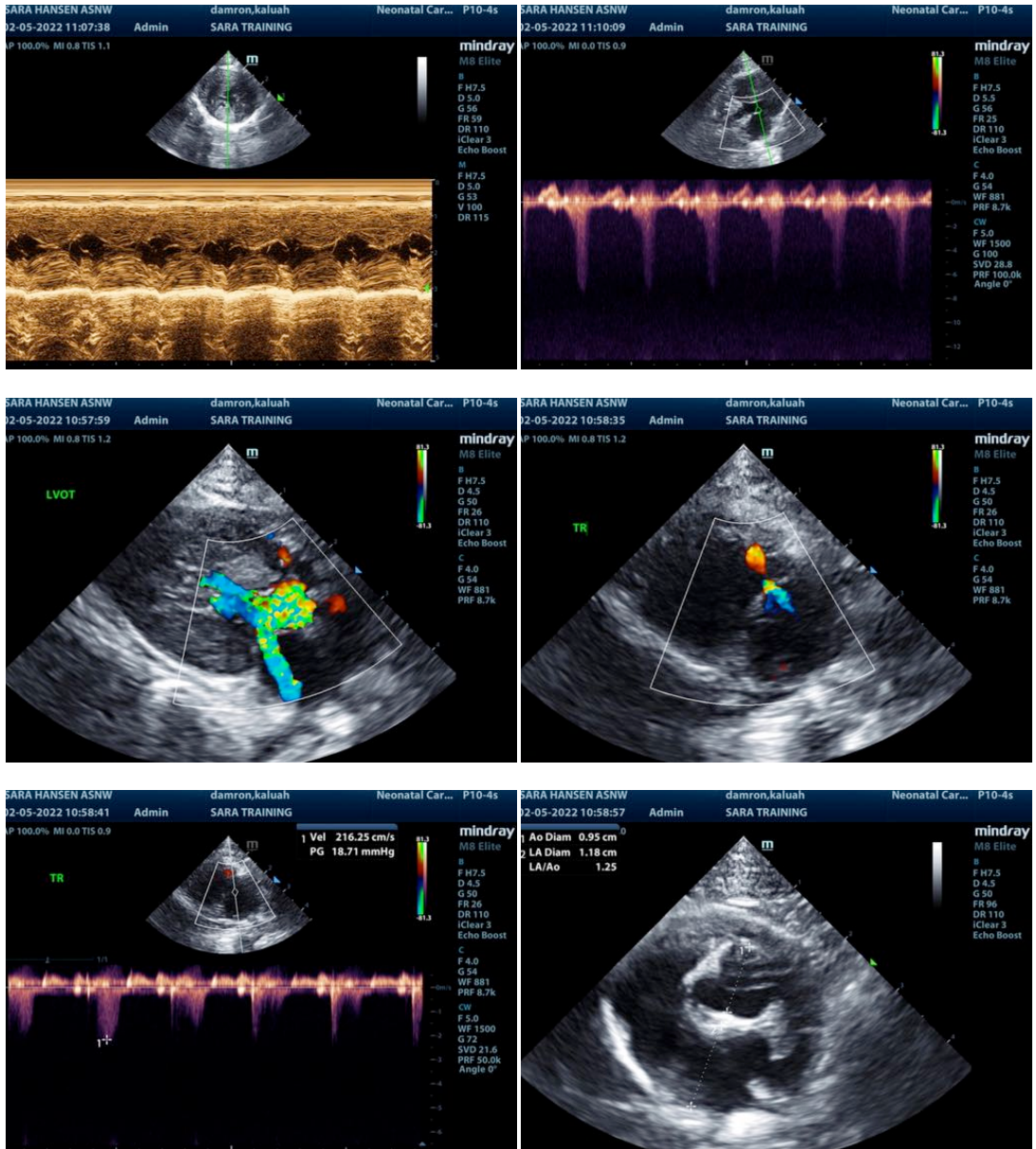
REFERRING VET

**

DATE

2/7/22

Invoice
95298





PATIENT

Kaluah Damron

SPECIES

Feline

BREED

Domestic Medium Hair

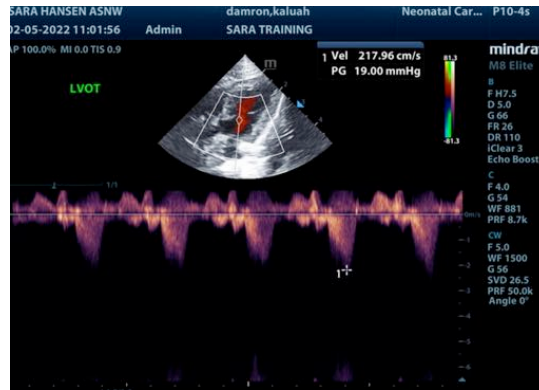
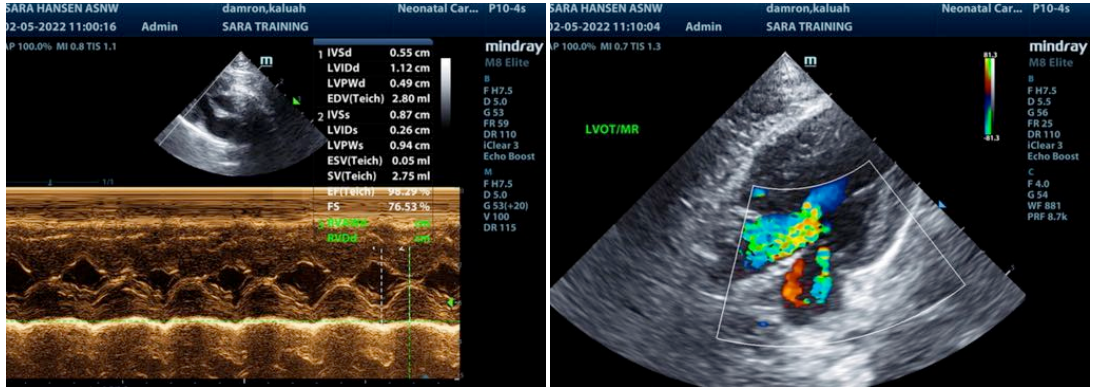
SEX

Spayed Female

AGE

1 ½ years

WEIGHT



INTERPRETED BY

Eric Lindquist, DMV,
DABVP, Cert. IVUSS

IMAGING PERFORMED BY

Jenna Walsh, CVT

HOSPITAL NAME

REFERRING VET

**

DATE

2/7/22

Invoice
95298

The information and recommendations provided are based on the images presented by the referring veterinarian/sonographer. No evaluation can be communicated regarding pathology that was not visible in the image/video clips provided.

Thank you for this referral. If the clinical or image interpretation does not parallel your findings or if I can be of any further assistance please contact me.

Eric Lindquist, DMV, DABVP, Cert. IVUSS

CEO of Sonopath.com

Eric.Lindquist@SonoPath.com