

## PATIENT

Shelby Cameron

## SPECIES

Canine

## BREED

Cavalier King Charles  
Spaniel

## SEX

Neutered male

## AGE

12 years

## WEIGHT

26.2 lbs

## PRESENTING CLINICAL SIGNS

Lumbosacral and hip arthritis anxiety hx of IMTP III/VI L systolic apical heart murmur (chronic since 2016 with minimal progression) overweight BCS 4/5  
Abnormal PE/Chem/CBC/UA Results: ^Alk Phos 408 U/L

## ULTRASONOGRAPHIC EXAMINATION OF THE HEART

The echocardiogram in this patient demonstrated normal **left atrial** size based on 3 different LA measurement methods. Chamber volumes and echogenicity were normal. The cranial and caudal **mitral** valve leaflets presented vegetative thickening consistent with endocardiosis. Doppler indicated measurable insufficiency. The **left ventricle** presented thicknesses with linear contour and was not dilated nor restricted. The **myocardium** presented normal echogenicity without subjective evidence of significant fibrotic or ischemic disease. **Contractility** of the ventricular walls was adequate and in normal range for this patient evidenced by the fractional shortening measurement and subjective evaluation of the different regions of the myocardium. The **left ventricular outflow** tract demonstrated normal laminar flow and subjective structural integrity. The **right atrium** and auricle revealed normal size, structure and content. No evidence of masses was noted or chamber overload. **Tricuspid** insufficiency jets were minor and eccentric. The **right ventricle** was of normal size (1/3 diameter of LV), chordae structure, myocardial echogenicity and thickness. **Pulmonic** tract assessment revealed normal valve structure, laminar flow, and diameter (approx. 1:1 pa/ao ratio). No visible **pericardial** or free pleura fluid was noted. No echographically detectable evidence of infiltrative disease was visible. The cranial **mediastinum** and **pericardial** regions were free of masses in the visible window.

## INTERPRETED BY

Eric Lindquist, DMV,  
DABVP, Cert. IVUSS

## IMAGING PERFORMED BY

Sara Hansen

## HOSPITAL NAME

Animal Health  
Associates

## REFERRING VET

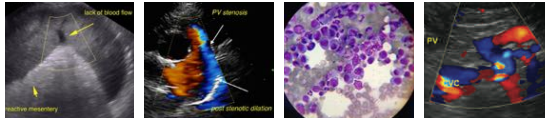
Dr. Johnson

CANINE	MR	TR	LA/AO	LA/AO	FS	EF	EPSS
<b>CARDIAC PARAMETERS</b>	<b>VMAX</b> (m/s)	<b>VMAX</b> (m/s)	(Boon method)	(Heart Base; Swe)	(%)	(%)	(cm)
<b>NORMAL PARAMETER</b>	4.5-5.5	<2.7	1.3	<1.6	28-40	40-100	<0.6
<b>PATIENT</b>		2.12	1.17	1.3	50		83
CANINE	HR	AV	PV	BODY WEIGHT	LA	LVIDd	LVIDs
<b>CARDIAC PARAMETERS</b>	(BPM)	<b>VMAX</b> (m/s)	<b>MAX</b> (m/s)		2D short axis Base view (cm)	Avg; 2D and m-mode short axis (cm)	Avg; 2D and m-mode short axis (cm)
<b>NORMAL PARAMETER</b>	50-100	0.7-1.7	0.7-1.6				
<b>PATIENT</b>	89	1.23	0.8	26.2 lbs	2.53 max	2.17	

## DATE

2/24/22

Invoice  
96388



**PATIENT                      ULTRASONOGRAPHIC FINDINGS**

Shelby Cameron                      Stage B1 valvular disease.

**SPECIES**                      Minor mitral centralized insufficiency.

Canine                                  Minor eccentric tricuspid insufficiency.

**INTERPRETATION OF THE FINDINGS & FURTHER RECOMMENDATIONS**

No therapy is recommended.

B1: The heart is stable without clinical disease. No overt contraindication for anesthesia of brief to moderate duration. I suggest Torbutrol premed, Propofol induction, Isoflurane maintenance or similar protocol if anesthesia is desired. Blood pressure recommended if not already performed and target white coat negative systolic pressure of < 160 mmHg. If higher than this ACE-inhibitor is suggested to reach this level. Recheck echocardiogram is recommended in 6 months, earlier if murmur grade increases or clinical signs initiate.

**BREED**

Cavalier King Charles  
Spaniel

**SEX**

Neutered male

**AGE**

12 years

**WEIGHT**

26.2 lbs

**INTERPRETED BY**

Eric Lindquist, DMV,  
DABVP, Cert. IVUSS

**IMAGING PERFORMED BY**

Sara Hansen

**HOSPITAL NAME**

Animal Health  
Associates

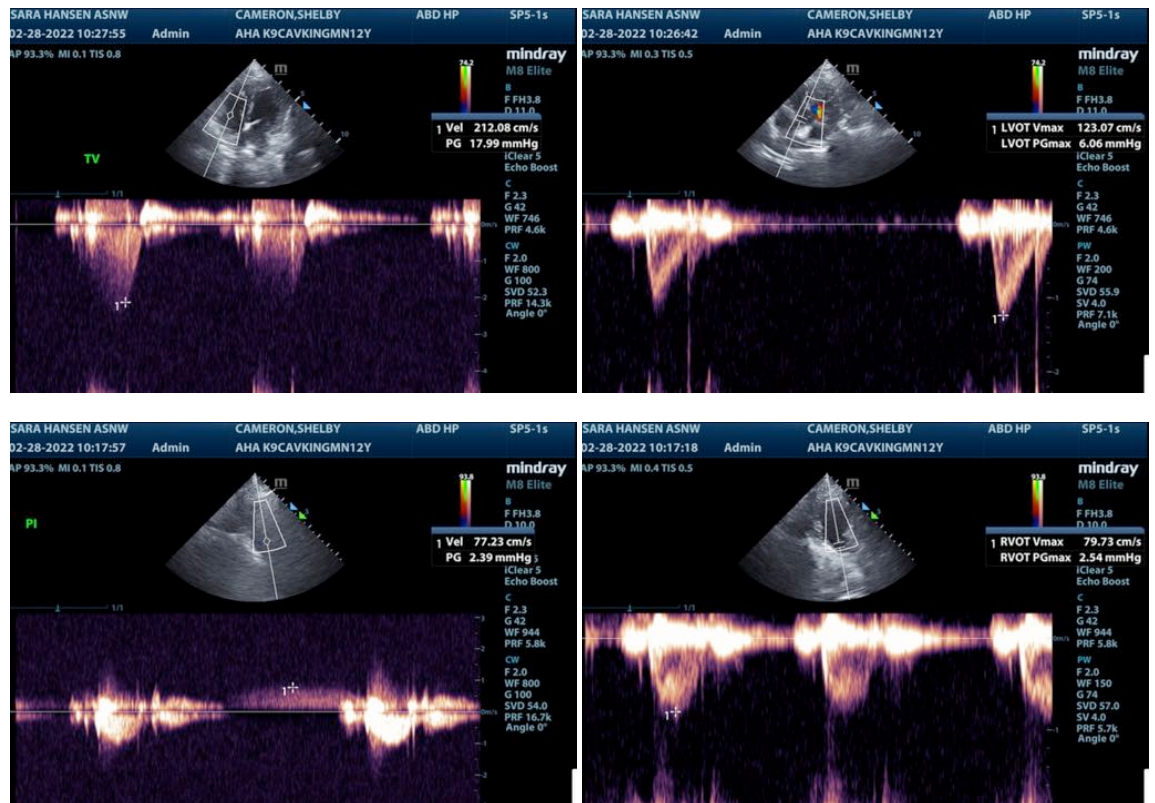
**REFERRING VET**

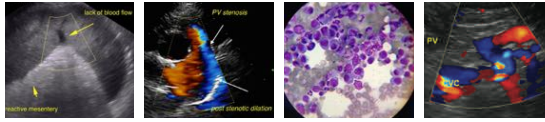
Dr. Johnson

**DATE**

2/24/22

**Invoice**  
96388





**PATIENT**

Shelby Cameron

**SPECIES**

Canine

**BREED**

Cavalier King Charles  
Spaniel

**SEX**

Neutered male

**AGE**

12 years

**WEIGHT**

26.2 lbs

**INTERPRETED BY**

Eric Lindquist, DMV,  
DABVP, Cert. IVUSS

**IMAGING PERFORMED BY**

Sara Hansen

**HOSPITAL NAME**

Animal Health  
Associates

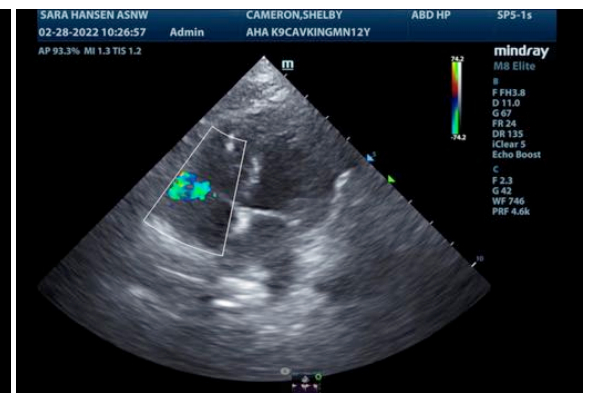
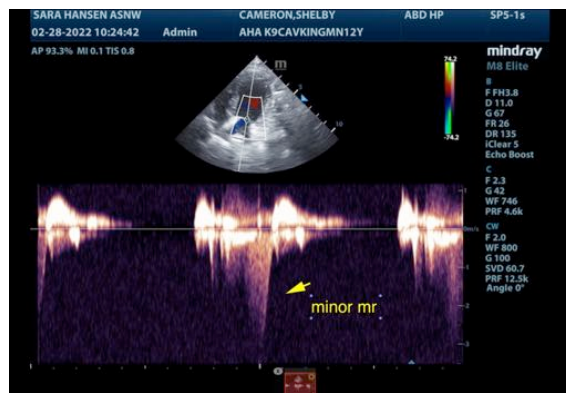
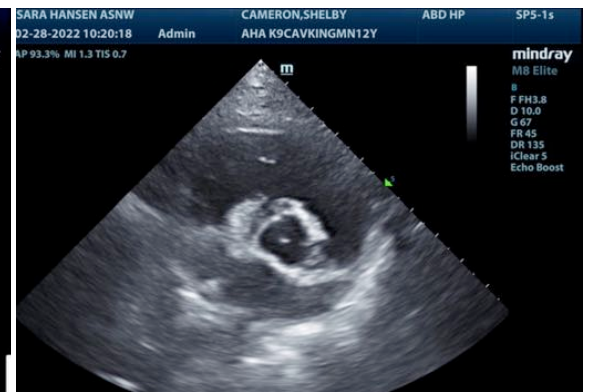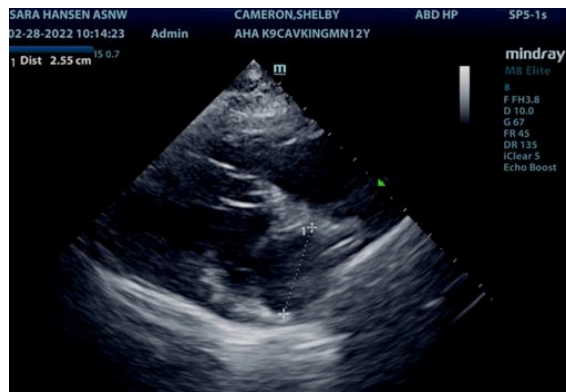
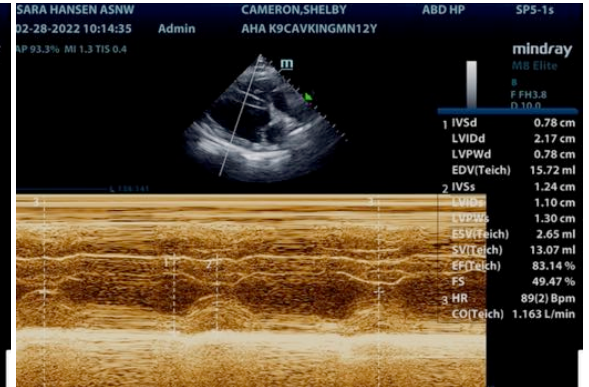
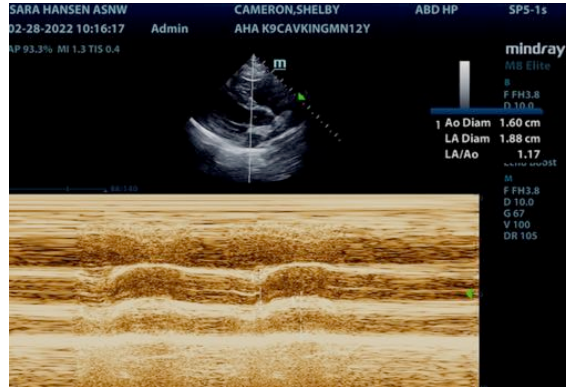
**REFERRING VET**

Dr. Johnson

**DATE**

2/24/22

Invoice  
96388

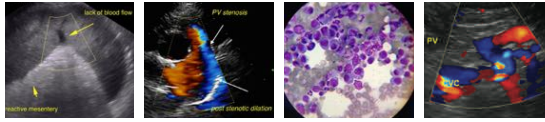


The information and recommendations provided are based on the images presented by the referring veterinarian/sonographer. No evaluation can be communicated regarding pathology that was not visible in the image/video clips provided.

Thank you for this referral. If the clinical or image interpretation does not parallel your findings or if I can be of any further assistance please contact me.

Eric Lindquist, DMV, DABVP, Cert. IVUSS

CEO of Sonopath.com



**PATIENT**

Eric.Lindquist@SonoPath.com

Shelby Cameron

**SPECIES**

Canine

**BREED**

Cavalier King Charles  
Spaniel

**SEX**

Neutered male

**AGE**

12 years

**WEIGHT**

26.2 lbs

**INTERPRETED BY**

Eric Lindquist, DMV,  
DABVP, Cert. IVUSS

**IMAGING  
PERFORMED BY**

Sara Hansen

**HOSPITAL NAME**

Animal Health  
Associates

**REFERRING VET**

Dr. Johnson

**DATE**

2/24/22

**Invoice**  
96388