SonoPath
Clinical Sonography & Telecytology
EDUCATIONAL TELECONSULTATION SERVICES™
1-800-838-4268 info@sonopath.com SonoPath.com

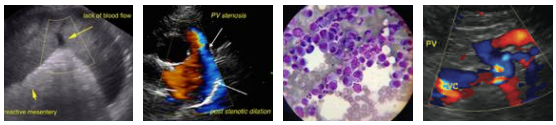

ANIMAL SOUNDS NW
MOBILE VETERINARY ULTRASOUND
IMAGING PERFORMED BY
AnimalSoundsNW.com 541-357-9423

PATIENT

Macaroni Brownstein

SPECIES

Feline

BREED

Domestic Shorthair

SEX

Neutered male

AGE

11 years

WEIGHT

12.6 lbs

INTERPRETED BY

Eric Lindquist, DMV, DABVP, Cert. IVUSS

IMAGING PERFORMED BY

Sara Hansen

HOSPITAL NAME

Pawsitive Wellness

REFERRING VET

Dr. Hardy

DATE

2/28/22

Invoice
96387

PRESENTING CLINICAL SIGNS

CKD, historically stage II Murmur r/o anemia, heart disease, hypertension, hyperthyroid, open
RBC- 3.27 HCT-19.7 HGB-5.2 MCV-60.2 MCHC- 26.4 MONO-1.06 PLT-91 MPV21.7

ULTRASONOGRAPHIC EXAMINATION OF THE ABDOMEN

Urinary System

The **urinary bladder**, trigone, and pelvic urethra presented normal thicknesses and normal tone. The ureters were not visible which is normal. No uroliths or sediment were visualized and anechoic urine was present. No evidence of inflammatory or neoplastic changes was noted. Ureteral papillae were normal.

The **kidneys** revealed largely normal size and structure, corticomedullary definition and ratio (cortex 1/3 of medulla) were essentially maintained with some age-related loss of curvilinear patterns regarding the capsule and C/M junction. The cortices presented largely uniform texture with some increased echogenicity expected for this age patient. Medullary structure differed distinctly from that of the cortex and no evidence of pelvic dilation was present. The left kidney measured 4.13 cm. The right kidney measured 4.15 cm.

Adrenal Glands

Both **adrenal glands** were visualized and recognized as having normal shape, size, position and echogenicity for this breed. The phrenic vasculature, glandular echogenicity and detail were unremarkable. Capsule, cortex, and medullary definition were normal for this age patient. The right adrenal gland measured 0.3 cm. The left adrenal gland measured 0.46 cm with slight pinpoint mineralization without loss of structural detail or contour.

Spleen

The **spleen** is enlarged and measured up to 2.0 cm in width with scalloping contour and heterogenous parenchymal changes.

Liver

The **liver** was enlarged and irregular with passive congestion pattern and hypoechoic nodules. The gallbladder wall was thickened. The common bile duct was normal with no evidence of post hepatic obstruction.

Gastrointestinal

Examination of the **gastrointestinal tract** revealed a stomach and intestine free of stasis, of normal wall thickness, acceptable curvilinear mural detail, and peristaltic activity. Small and large intestine

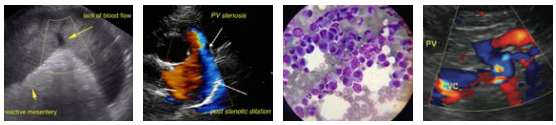

PATIENT

Macaroni Brownstein

SPECIES

Feline

BREED

Domestic Shorthair

SEX

Neutered male

AGE

11 years

WEIGHT

12.6 lbs

INTERPRETED BY

Eric Lindquist, DMV, DABVP, Cert. IVUSS

IMAGING PERFORMED BY

Sara Hansen

HOSPITAL NAME

Pawsitive Wellness

REFERRING VET

Dr. Hardy

DATE

2/28/22

Invoice
96387

demonstrated normal luminal chyme and stool consistency respectively. No obstructive or overt infiltrative disease was noted. No associated abnormal lymphatic activity was noted.

Pancreas

The **pancreas** was edematous.

Free Abdomen

A moderate amount of ascites was noted in this patent. Pleural effusion and pericardial effusion was noted through the diaphragm. This is suggestive for metastatic disease to the thorax given the splenic and hepatic patterns. Enhanced mesentery was noted throughout the midabdomen.

ULTRASONOGRAPHIC FINDINGS

Minor age related renal changes.

Spleno hepatomegaly.

Enhanced mesentery. Strongly suggestive for lymphomatosis or similar.

Pleural and pericardial effusion.

INTERPRETATION OF THE FINDINGS & FURTHER RECOMMENDATIONS

An echocardiogram is warranted to assess for cardiac component. However, FNA of the spleen, abdominocentesis and cytospin is recommended to confirm suspicion of lymphomatosis, mast cell disease or similar. The prognosis is guarded to poor depending on cytology results. This is a passive congestion pattern in the liver, secondary ascites may be caused by underlying thoracic neoplasia, right-sided failure or pericardial effusion depending upon cardiac parameters.

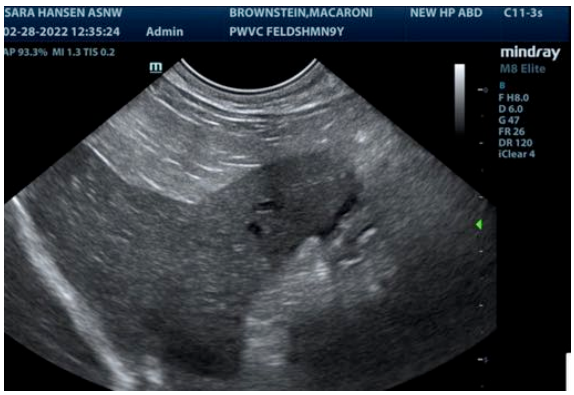

SonoPath
Clinical Sonography & Telecytology
EDUCATIONAL TELECONSULTATION SERVICES™
1-800-838-4268 info@sonopath.com SonoPath.com

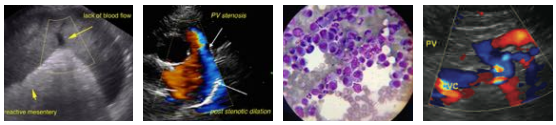

ANIMAL SOUNDS NW
MOBILE VETERINARY ULTRASOUND
IMAGING PERFORMED BY
AnimalSoundsNW.com 541-357-9423

PATIENT

Macaroni Brownstein

SPECIES

Feline

BREED

Domestic Shorthair

SEX

Neutered male

AGE

11 years

WEIGHT

12.6 lbs

INTERPRETED BY

Eric Lindquist, DMV, DABVP, Cert. IVUSS

IMAGING PERFORMED BY

Sara Hansen

HOSPITAL NAME

Pawsitive Wellness

REFERRING VET

Dr. Hardy

DATE

2/28/22

Invoice
96387

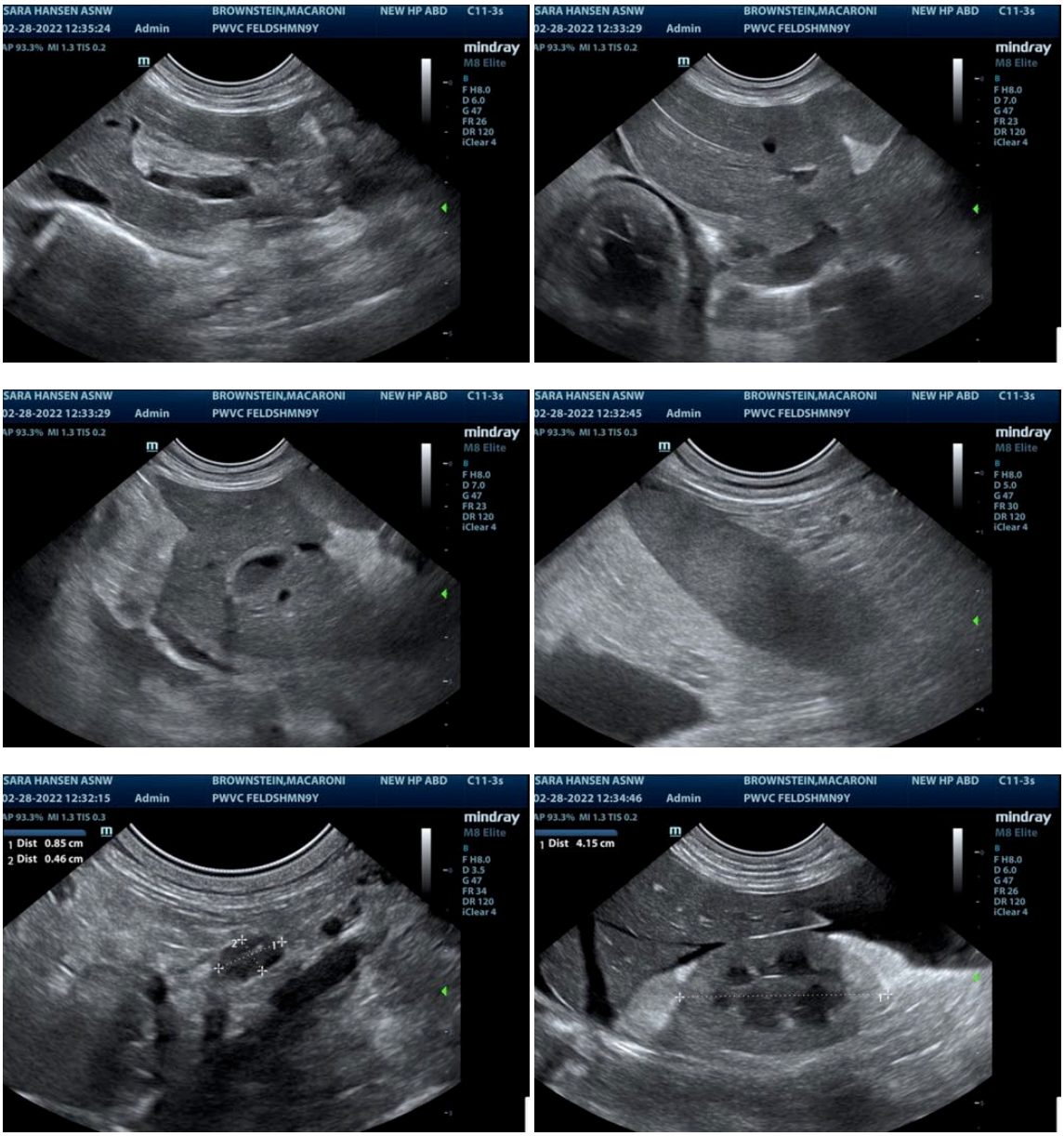

SonoPath
Clinical Sonography & Telecytology
EDUCATIONAL TELECONSULTATION SERVICES™
1-800-838-4268 info@sonopath.com SonoPath.com

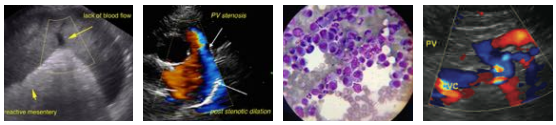

ANIMAL SOUNDS NW
MOBILE VETERINARY ULTRASOUND
IMAGING PERFORMED BY
AnimalSoundsNW.com 541-357-9423

PATIENT

Macaroni Brownstein

SPECIES

Feline

BREED

Domestic Shorthair

SEX

Neutered male

AGE

11 years

WEIGHT

12.6 lbs

INTERPRETED BY

Eric Lindquist, DMV, DABVP, Cert. IVUSS

IMAGING PERFORMED BY

Sara Hansen

HOSPITAL NAME

Pawsitive Wellness

REFERRING VET

Dr. Hardy

DATE

2/28/22

Invoice
96387

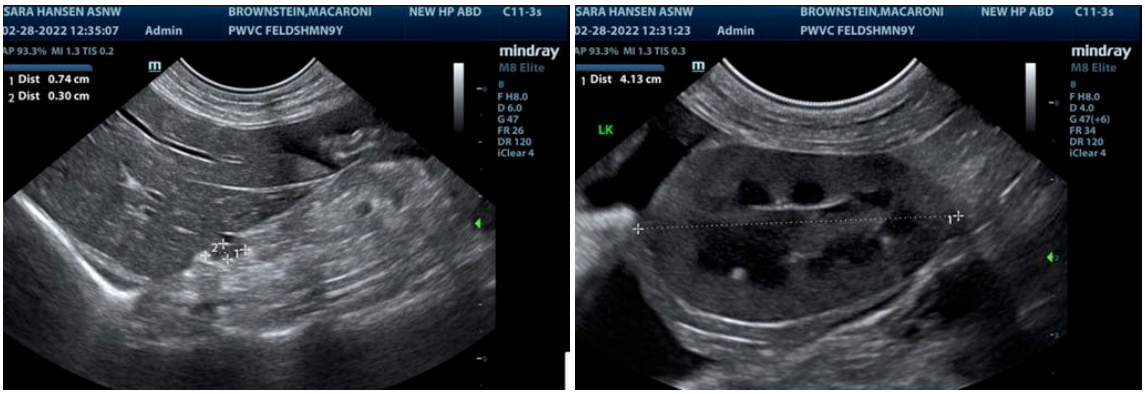

The information and recommendations provided are based on the images presented by the referring veterinarian/sonographer. No evaluation can be communicated regarding pathology that was not visible in the image/video clips provided.

Thank you for this referral. If the clinical or image interpretation does not parallel your findings or if I can be of any further assistance please contact me.

Eric Lindquist, DMV, DABVP, Cert. IVUSS

CEO of Sonopath.com

Eric.Lindquist@SonoPath.com