

PATIENT .PRESENTING CLINICAL SIGNS

Baxter Ritter

History: Clinical Exam Findings: History of congestive heart failure, collapsing trachea. Heart Rate and Respiratory Rates 130/60 Current Medications Currently on furosemide, enalapril, pimobendan. Primary Question/Differential to Be Answered in This Exam Is he stable enough for anesthesia and dental cleaning?

SPECIES

Canine

ULTRASONOGRAPHIC EXAMINATION OF THE HEART

BREED

Chihuahua Mix

The echocardiogram in this patient presented tachycardia and moderate to severe persistent volume overload. Severe left atrial enlargement was noted. The left ventricle revealed severe prolapse of the anterior and posterior leaflets and mitral valve leaflets. Tricuspid insufficiency was noted. This is consistent with moderate pulmonary hypertension. The right atrium and right ventricle appeared normal.

SEX

Neutered male

AGE

12 years

WEIGHT

8.5 lbs

CANINE CARDIAC PARAMETERS	MR VMAX (m/s)	TR VMAX (m/s)	LA/AO (Boon method)	LA/AO (Heart Base;)	FS (%)	EF (%)	EPSS (cm)
NORMAL PARAMETER	4.5-5.5	<2.7	1.3	<1.6	28-40	40-100	<0.6
PATIENT	5.01	3.77	2.05	1.9	42	74	0.4
CANINE CARDIAC PARAMETERS	HR (BPM)	AV VMAX (m/s)	PV MAX (m/s)	BODY WEIGHT	LA 2D short axis Base view (cm)	LVIDd Avg; 2D and m-mode short axis (cm)	LVIDs Avg; 2D and m-mode short axis (cm)
NORMAL PARAMETER	50-100	0.7-1.7	0.7-1.6	BELOW	BELOW	BELOW	BELOW
PATIENT	203	1.0	0.65	8.5 lbs	4.1 max	3.57	

INTERPRETED BY

Eric Lindquist, DMV, DABVP, Cert. IVUSS

IMAGING PERFORMED BY

Jenna Walsh, CVT

HOSPITAL NAME

Cottage Grove VC

ULTRASONOGRAPHIC FINDINGS

Decompensating C1 valvular disease.

REFERRING VET

Dr. Damewood

INTERPRETATION OF THE FINDINGS & FURTHER RECOMMENDATIONS

The cardiac presentation is in a severely precarious volume overload tachycardia. I do not recommend any anesthetic procedure in this patient as the risk is high. Risk is high for sudden death in the current presentation.

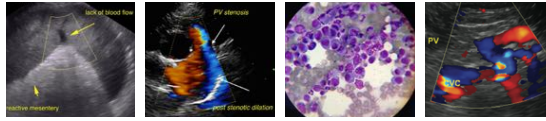
DATE

2/10/23

I recommend maximizing Enalapril at 0.5 mg/kg b.i.d., Pimobendan at 0.3 mg/kg b.i.d. Furosemide should be increased depending on the current dose. I recommend adding Spironolactone at 1-2 mg/kg b.i.d. cardiology referral is recommended for further treatment; however, the options for treatment are

Invoice

42707



PATIENT

Baxter Ritter

extremely limited. Sildenafil can be considered given the pulmonary hypertension. However, the primary issue at this time appears to be left-sided volume overload.

SPECIES

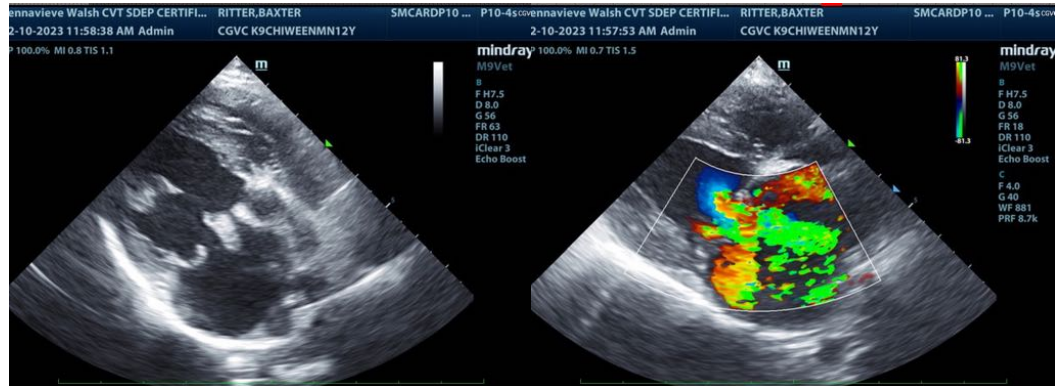
Canine

BREED

Chihuahua Mix

SEX

Neutered male

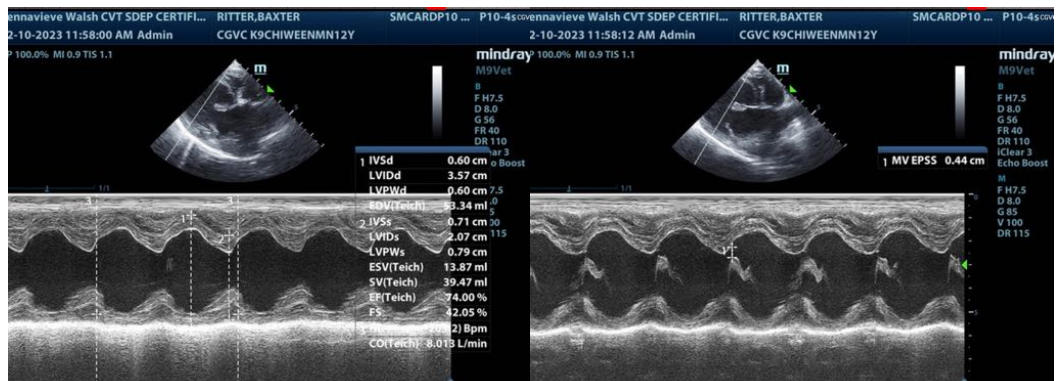


AGE

12 years

WEIGHT

8.5 lbs

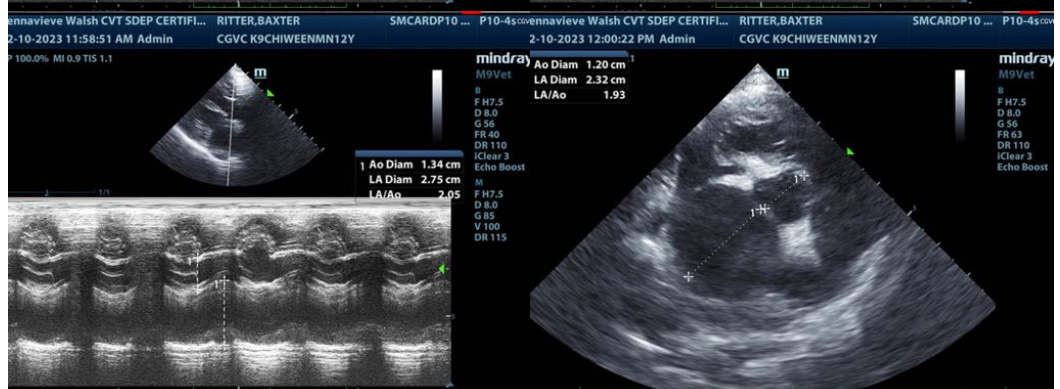


INTERPRETED BY

Eric Lindquist, DMV,
DABVP, Cert. IVUSS

IMAGING PERFORMED BY

Jenna Walsh, CVT



HOSPITAL NAME

Cottage Grove VC

REFERRING VET

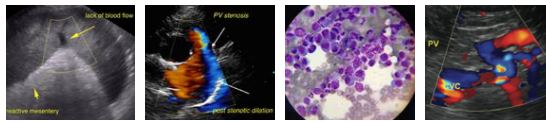
Dr. Damewood

DATE

2/10/23

Invoice

42707



PATIENT

Baxter Ritter

SPECIES

Canine

BREED

Chihuahua Mix

SEX

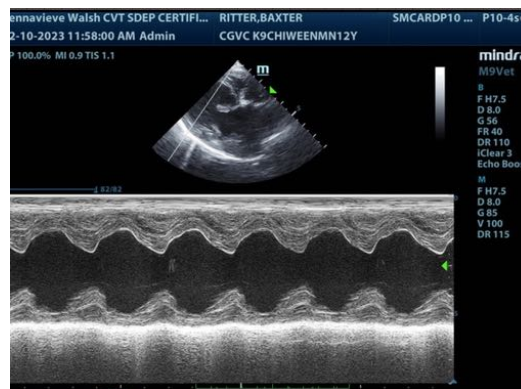
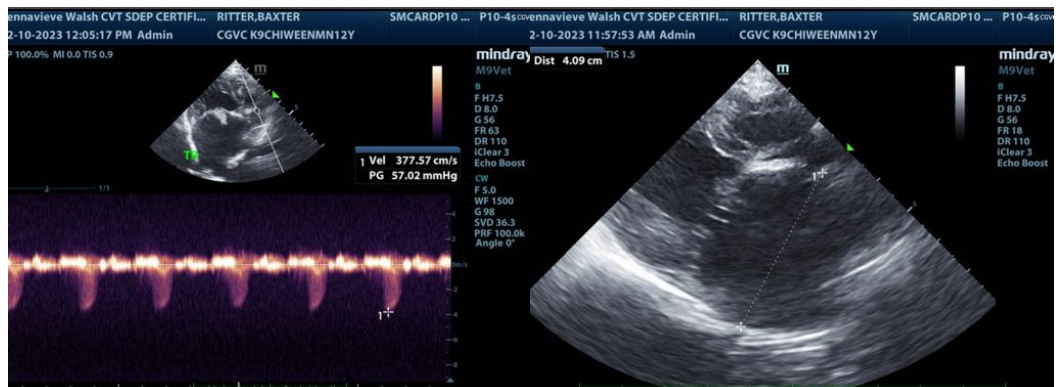
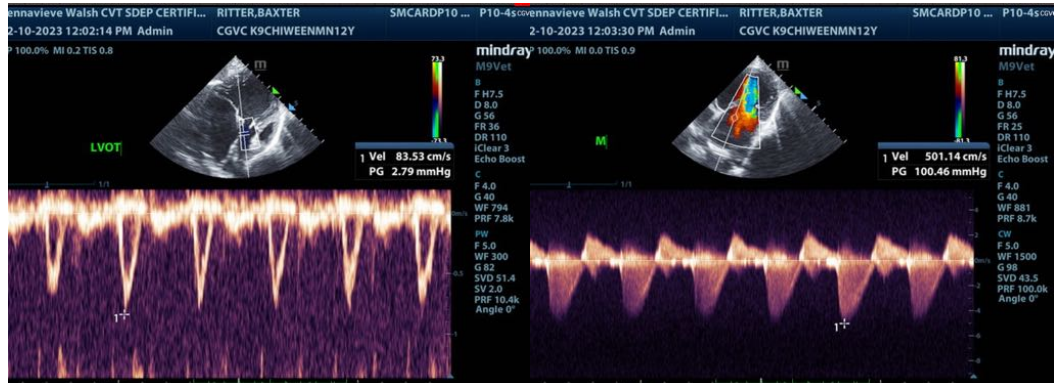
Neutered male

AGE

12 years

WEIGHT

8.5 lbs



INTERPRETED BY

Eric Lindquist, DMV,
DABVP, Cert. IVUSS

IMAGING PERFORMED BY

Jenna Walsh, CVT

HOSPITAL NAME

Cottage Grove VC

REFERRING VET

Dr. Damewood

DATE

2/10/23

Invoice

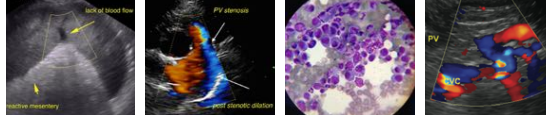
42707

The information and recommendations provided are based on the images presented by the referring veterinarian/sonographer. No evaluation can be communicated regarding pathology that was not visible in the image/video clips provided.

Thank you for this referral. If the clinical or image interpretation does not parallel your findings or if I can be of any further assistance please contact me.

Eric Lindquist, DMV, DABVP, Cert. IVUSS

CEO of Sonopath.com



PATIENT

Eric.Lindquist@SonoPath.com

Baxter Ritter

SPECIES

Canine

BREED

Chihuahua Mix

SEX

Neutered male

AGE

12 years

WEIGHT

8.5 lbs

INTERPRETED BY

Eric Lindquist, DMV,
DABVP, Cert. IVUSS

**IMAGING
PERFORMED BY**

Jenna Walsh, CVT

HOSPITAL NAME

Cottage Grove VC

REFERRING VET

Dr. Damewood

DATE

2/10/23

Invoice

42707