



**PATIENT PRESENTING CLINICAL SIGNS**

Leonardo Martin

Grade 5/6 PMI: left sided patient presenting with increase in coughing Heart Rate and Respiratory Rates 120/44

**SPECIES**

Canine

**BREED**

Terrier

**SEX**

Neutered male

**AGE**

13 years

**WEIGHT**

9.8 lbs

**ULTRASONOGRAPHIC EXAMINATION OF THE HEART**

The echocardiogram in this patient demonstrated enlarged **left atrial** size based on 3 different LA measurement methods. Chamber volumes and echogenicity were normal. The cranial and caudal **mitral** valve leaflets presented vegetative thickening consistent with endocardiosis. Prolapse of the anterior mitral valve leaflet was noted. Doppler indicated measurable insufficiency. The **left ventricle** presented thicknesses with linear contour and was not dilated nor restricted. The **myocardium** presented normal echogenicity without subjective evidence of significant fibrotic or ischemic disease. **Contractility** of the ventricular walls was adequate and in normal range for this patient evidenced by the fractional shortening measurement and subjective evaluation of the different regions of the myocardium. The **left ventricular outflow** tract demonstrated normal laminar flow and subjective structural integrity. The **right atrium** and auricle revealed normal size, structure and content. No evidence of masses was noted or chamber overload. Minor **tricuspid** insufficiency was noted. The **right ventricle** was of normal size (1/3 diameter of LV), chordae structure, myocardial echogenicity and thickness. **Pulmonic** tract assessment revealed normal valve structure, laminar flow, and diameter (approx. 1:1 pa/ao ratio). No visible **pericardial** or free pleura fluid was noted. No echographically detectable evidence of infiltrative disease was visible. The cranial **mediastinum** and **pericardial** regions were free of masses in the visible window. A large amount of lung interference was noted.

**INTERPRETED BY**

Eric Lindquist, DMV  
DABVP, Cert. IVUSS

**IMAGING PERFORMED BY**

Jessica Miller, RDMS

**HOSPITAL NAME**

Willakenzie AC

**REFERRING VET**

Dr. Whalen

CANINE CARDIAC PARAMETERS	MR VMAX (m/s)	TR VMAX (m/s)	LA/AO (Boon method)	LA/AO (Heart Base; Swe)	FS (%)	EF (%)	EPSS (cm)
NORMAL PARAMETER	4.5-5.5	<2.7	1.3	<1.6	28-40	40-100	<0.6
PATIENT	6.65		NM	1.6	50		0.1
CANINE CARDIAC PARAMETERS	HR (BPM)	AV VMAX (m/s)	PV MAX (m/s)	BODY WEIGHT (kg)	LA (2D short axis Base view) (cm)	LVIDd (Avg; 2D and m-mode short axis) (cm)	LVIDs (Avg; 2D and m-mode short axis) (cm)
NORMAL PARAMETER	50-100	0.7-1.7	0.7-1.6				
PATIENT		1.78	0.75		3.5 max	3.0	

**ULTRASONOGRAPHIC FINDINGS**

**INVOICE**

94852

**DATE**

12/22/21

Stage B2 valvular disease.

Mitral insufficiency.

Mild left atrial enlargement.

Minor tricuspid insufficiency, not clinically significant.



**PATIENT**

Leonardo Martin

**SPECIES**

Canine

**BREED**

Terrier

**SEX**

Neutered male

**AGE**

13 years

**WEIGHT**

9.8 lbs

**INTERPRETED BY**

Eric Lindquist, DMV  
DABVP, Cert. IVUSS

**IMAGING PERFORMED BY**

Jessica Miller, RDMS

**HOSPITAL NAME**

Willakenzie AC

**REFERRING VET**

Dr. Whalen

**INVOICE**

94852

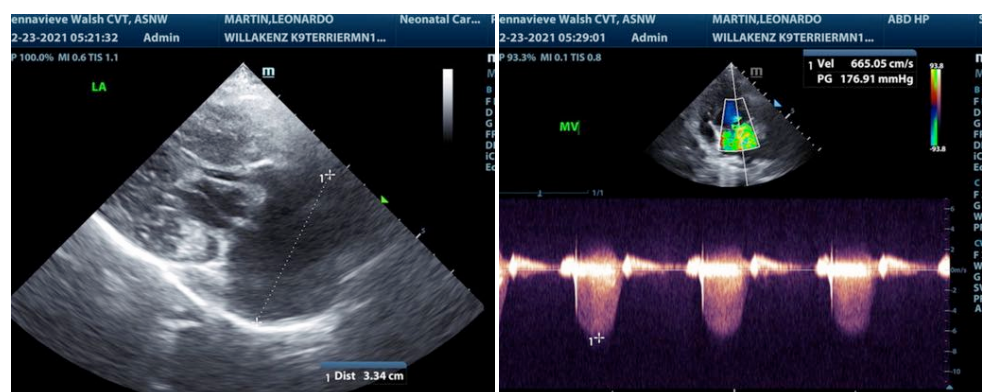
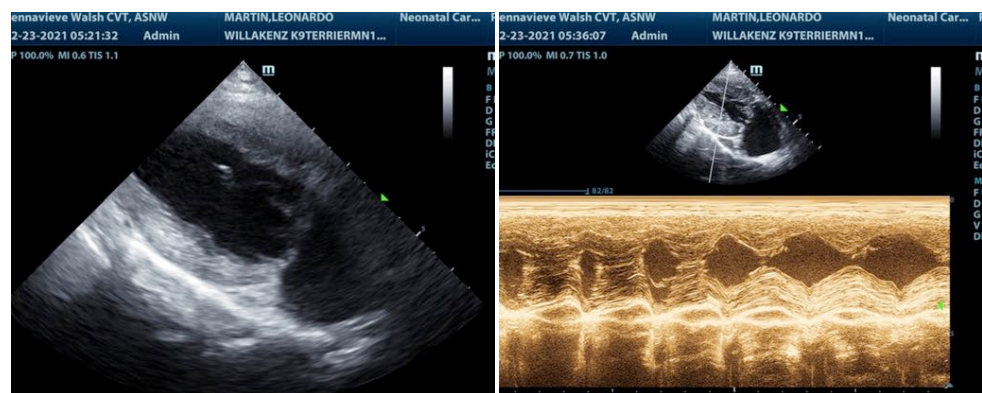
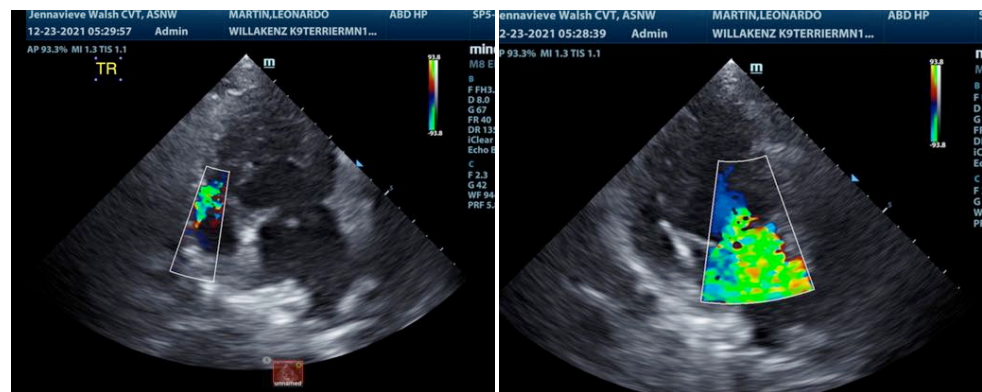
**DATE**

12/22/21

**INTERPRETATION OF THE FINDINGS & FURTHER RECOMMENDATIONS**

I recommend initiating Pimobendan at 0.3 mg/kg b.i.d. Blood pressure measurements are warranted. If systolic pressure is greater than 160 then ace inhibitor therapy is warranted.

B2/C1: The heart is in a somewhat precarious state with volume overload and a heart that is working to compensate for the valvular insufficiency. Target respiratory rate is < 20 resp/minute after therapy. After initiating therapy, I recommend recheck on the clinical exam, BUN, Creatinine, USG, Chest radiographs & Blood pressure in 5-7 days. Recheck echo in 1 month. Earlier if clinical decompensation is occurring. I do not recommend anesthesia at this time until stabilization has occurred on the recommended medications. Repeat pre-anesthetic echo is ideal if anesthesia is eventually necessary.





**PATIENT**

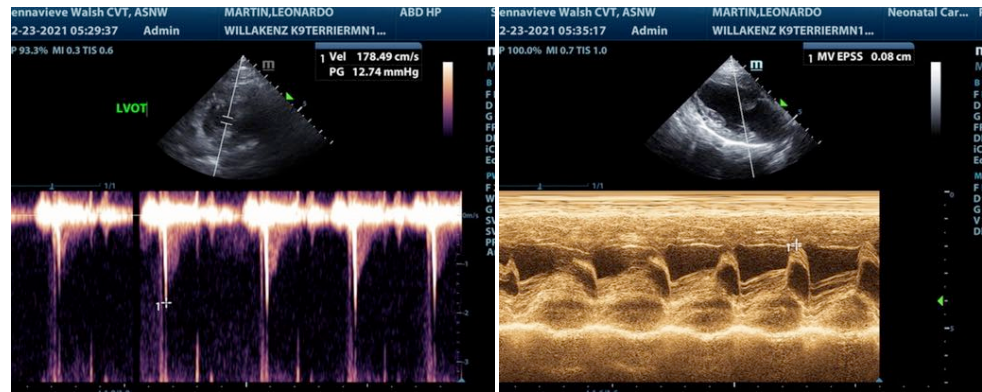
Leonardo Martin

**SPECIES**

Canine

**BREED**

Terrier



**SEX**

Neutered male

**AGE**

13 years

**WEIGHT**

9.8 lbs

**INTERPRETED BY**

Eric Lindquist, DMV  
DABVP, Cert. IVUSS

**IMAGING PERFORMED BY**

Jessica Miller, RDMS

**HOSPITAL NAME**

Willakenzie AC

**REFERRING VET**

Dr. Whalen

**INVOICE**

94852

**DATE**

12/22/21

The information and recommendations provided are based on the images presented by the referring veterinarian. No evaluation can be communicated regarding pathology that was not visible in the image/video clips provided.

Thank you for this referral. If the clinical or image interpretation does not parallel your findings or if I can be of any further assistance please contact me.

**Eric Lindquist, DMV, DABVP, Cert. IVUSS, CEO of SonoPath.com**  
info@SonoPath.com