



PATIENT

Atticus Sandler Hewitt

SPECIES

Feline

BREED

Domestic Shorthair

SEX

Neutered male

AGE

8 years

WEIGHT

13.47 ;bs

INTERPRETED BY

Eric Lindquist, DMV,
DABVP, Cert. IVUSS

IMAGING PERFORMED BY

Jenna Walsh, CVT

HOSPITAL NAME

West Eugene AH

REFERRING VET

Dr. Seyler

DATE

12/22/21

Invoice
94846

PRESENTING CLINICAL SIGNS

High fever, dehydration. Recommend CBC and biochemistry as initial diagnostics. Recommend Cerenia, SQ fluids, I/D diet and acupuncture (specifically to address fever and bloating). Owner agreed to lab work, Cerenia and SQ fluids. Recommended owner using isopropyl alcohol on pads to help decrease fever. Imaging- radiographs and/or abdominal ultrasound would be next diagnostic steps. More specific treatment may be determined based on lab work results. MES: 12-21-21 at 5:30p:
Abnormal PE/Chem/CBC/UA Results: -CBC- lymphopenia (0.83), mild thrombocytopenia (299). - Biochemistry- mildly elevated ALT (205), elevated amylase (1354), mild hyperglycemia (246), mild hyponatremia (140), elevated total protein (8.8).

ULTRASONOGRAPHIC EXAMINATION OF THE ABDOMEN

Urinary System

The **urinary bladder** and visible pelvic urethra were unremarkable for the level of repletion presented. The urine, however, did present some mildly echogenic debris consistent with mucous, exfoliated cells from renal or bladder origin, and/or blood clots as these echogenic changes can all present similarly. This is often related to urinary tract infection but may represent simple evidence of exfoliated debris or sterile inflammation. Cystocentesis, urinalysis, +/- culture would be recommended to rule out and define any UTI.

The **kidneys** revealed mildly increased cortical echogenicity and slight pericapsular inflammatory pattern. This was primarily noted in the left kidney. The left kidney measured 4.44 cm. The right kidney measured 4.7 cm.

Adrenal Glands

Both **adrenal glands** were visualized and recognized as having normal shape, size, position and echogenicity for this breed. The phrenic vasculature, glandular echogenicity and detail were unremarkable. Capsule, cortex, and medullary definition were normal for this age patient. The right adrenal gland measured 0.45 cm. The left adrenal gland measured 0.37 cm.

Spleen

The **spleen** presented a smooth homogeneous parenchyma hyperechoic to liver and renal cortical parenchyma. The capsule was smooth without noticeable expansion or deviation from within the spleen or adjacent pathology. The splenic vasculature demonstrated normal volume without signs of congestion or thrombosis. No sonographic evidence of acute or chronic inflammatory, neoplastic, or infarctual changes was noted.

Liver

The **liver** images submitted revealed subjectively normal liver size, contour, and structure. Parenchymal echogenicity was naturally coarse and hypoechoic to the spleen. Vascular and biliary tracts were of



PATIENT

Atticus Sandler Hewitt

normal volume with no evidence of congestion. The gallbladder presented acceptably thin walls with primarily anechoic content. The cystic and common bile ducts were normal. No pathological hepatic lymphadenopathy was evident. No overt structural evidence of inflammatory, infiltrative or regenerative pathology was evident.

SPECIES

Feline

Gastrointestinal

BREED

Domestic Shorthair

Examination of the **gastrointestinal tract** revealed a stomach and intestine free of stasis, of normal wall thickness, acceptable curvilinear mural detail, and peristaltic activity. Small and large intestine demonstrated normal luminal chyme and stool consistency respectively. No obstructive or overt infiltrative disease was noted. No associated abnormal lymphatic activity was noted.

SEX

Neutered male

Pancreas

AGE

8 years

The base and limbs of the **pancreas** were observed to be largely isoechoic to surrounding omental fat. Pancreatic duct and capsular contour were acceptably normal and parenchyma respected normal curvilinear patterns. No overt evidence of active inflammatory or neoplastic disease was noted.

WEIGHT

13.47 ;bs

ULTRASONOGRAPHIC FINDINGS

Mild nephritis pattern.

Bladder debris.

INTERPRETED BY

Eric Lindquist, DMV,
DABVP, Cert. IVUSS

INTERPRETATION OF THE FINDINGS & FURTHER RECOMMENDATIONS

Full urinary work-up is warranted to assess if urinary tract may be the cause of the clinical profile. There was no evidence of neoplasia. Manual palpation of the kidneys is warranted to assess for discomfort. Otherwise, unremarkable abdomen.

IMAGING PERFORMED BY

Jenna Walsh, CVT

HOSPITAL NAME

West Eugene AH

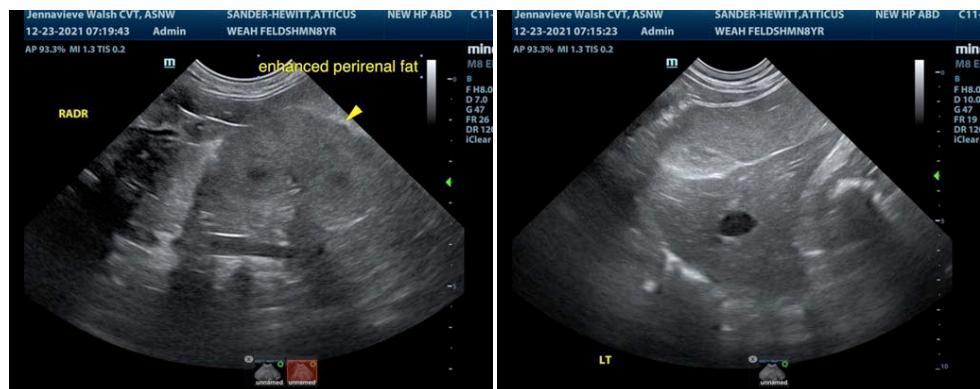
REFERRING VET

Dr. Seyler

DATE

12/22/21

Invoice
94846





PATIENT

Atticus Sandler Hewitt

SPECIES

Feline

BREED

Domestic Shorthair

SEX

Neutered male

AGE

8 years

WEIGHT

13.47 ;bs

INTERPRETED BY

Eric Lindquist, DMV,
DABVP, Cert. IVUSS

IMAGING PERFORMED BY

Jenna Walsh, CVT

HOSPITAL NAME

West Eugene AH

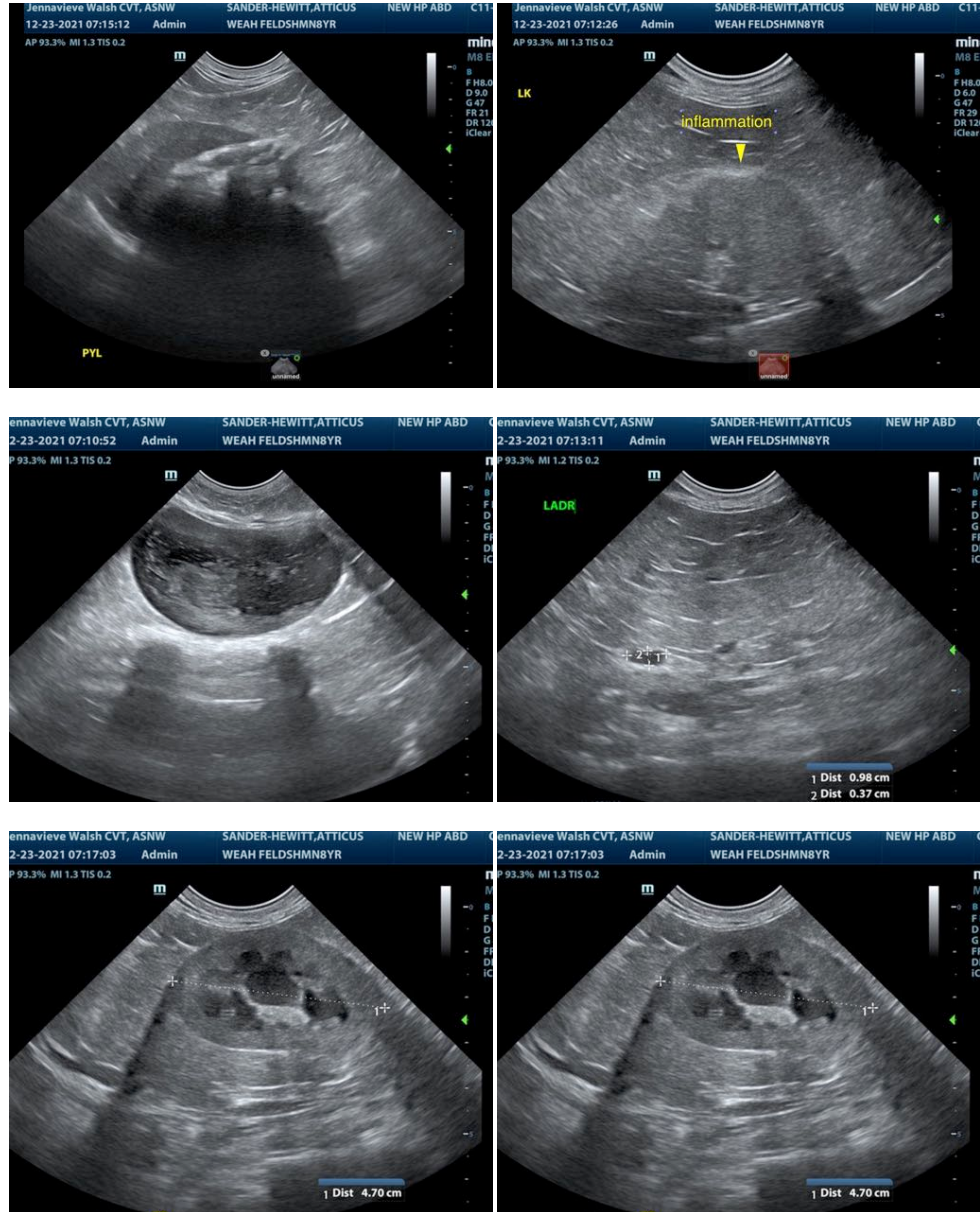
REFERRING VET

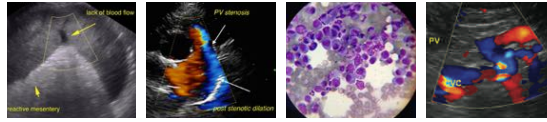
Dr. Seyler

DATE

12/22/21

Invoice
94846





PATIENT

Atticus Sandler Hewitt

SPECIES

Feline

BREED

Domestic Shorthair

SEX

Neutered male

AGE

8 years

WEIGHT

13.47 ;bs

INTERPRETED BY

Eric Lindquist, DMV, DABVP, Cert. IVUSS

IMAGING PERFORMED BY

Jenna Walsh, CVT

HOSPITAL NAME

West Eugene AH

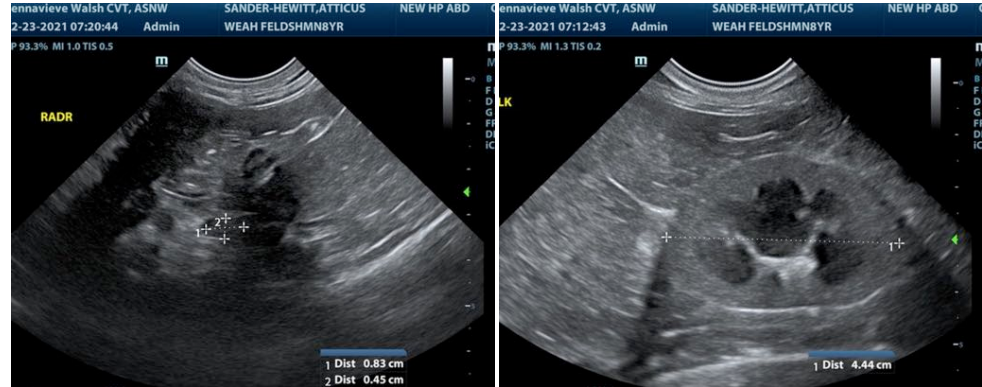
REFERRING VET

Dr. Seyler

DATE

12/22/21

Invoice
94846




The information and recommendations provided are based on the images presented by the referring veterinarian. No evaluation can be communicated regarding pathology that was not visible in the image/video clips provided.

Thank you for this referral. If the clinical or image interpretation does not parallel your findings or if I can be of any further assistance please contact me.

Eric Lindquist, DMV, DABVP, Cert. IVUSS

CEO of SonoPath.com

Eric.Lindquist@SonoPath.com



The following is an applicable excerpt from the *Curbside Guide to Diagnosis & Treatment of Sonographic Disease* offered by [SonoPath.com](http://sonopath.com) Lindquist, Frank, Lobetti, and Modler.

An essential quick guide for every general practitioner and sonographer.

<https://sonopath.com/products/curbside-guide-editing-due-release-12012015>

Fever of Unknown Origin

<http://www.sonopath.com/FUO>



PATIENT

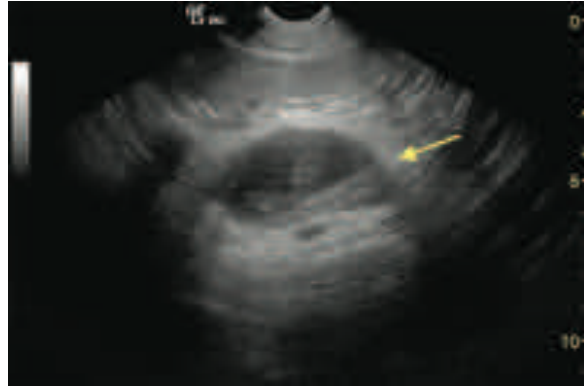
Atticus Sandler Hewitt

SPECIES

Feline

BREED

Domestic Shorthair



Long axis of the mid-abdomen in a dog with an omental abscess after foreign body penetration from the gastrointestinal tract. The hypoechoic necrotic center of the lesion is surrounded by a thick echogenic capsule and hyperechoic mesenteric fat (arrow) indicating focal peritonitis. The linear echogenic needle (5 cm depth) is barely visible owing to the density of the purulent material contained within the abscess.

SEX

Neutered male

AGE

8 years

WEIGHT

13.47 ;bs

INTERPRETED BY

Eric Lindquist, DMV,
DABVP, Cert. IVUSS

IMAGING PERFORMED BY

Jenna Walsh, CVT

HOSPITAL NAME

West Eugene AH

REFERRING VET

Dr. Seyler

DATE

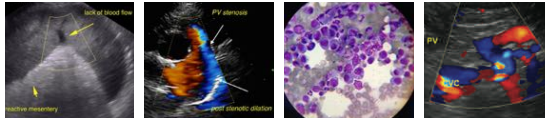
12/22/21

Invoice
94846

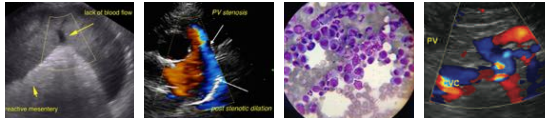
Description: The definition of a fever of unknown origin (FUO) has not been clearly defined for animals. Currently, it is either understood to be a fever that does not resolve within the period one would expect for a “self-limiting infection” being treated with appropriate antimicrobial therapy, or that for which an underlying diagnosis has not been determined despite considerable diagnostic effort. The common causes of FUO were summarized concisely in a presentation at the American College of Veterinary Internal Medicine 2004 Forum. The presenters synthesized information from three veterinary papers on the subject, which suggested the following:

Final Diagnosis	Bennett (dogs & cats)	Dunn and Dunn (dogs only)	Lunn (dogs & one cat)	Total	Percent
Infection	21	16	10	47	28
Immune	18	22	6	46	27
Bone marrow disease	4	22	2	28	16
Neoplasia (outside marrow)	0	10	2	12	7
Miscellaneous	2	12	2	16	9
No diagnosis	0	19	2	21	12
TOTALS	45	101	24	170	99

The types of infection diagnosed in this case series were varied, ranging from discospondylitis (8 cases), blastomycosis (6), and bacterial endocarditis (4), to leishmaniasis (1), prostatitis (1), and *Ehrlichia canis* infection (1); a multitude of other infectious causes also fell within the spectrum. Of the cases in which immune-mediated disease was found, 44% had immune-mediated polyarthritis. Bone marrow diseases



PATIENT	included myeloproliferative disease, myelodysplasia (8), lymphocytic leukemia (8), myeloma (3), chronic granulocytic leukemia (3), lymphoblastic leukemia, and malignant histiocytosis. The types of neoplasia located outside the bone marrow included lymphoma (6), metastatic disease (2), and neoplasms of the lung, spleen, and stomach. Finally, miscellaneous diseases included hypertrophic osteodystrophy (6), meningitis (3), portosystemic shunt (3), lymphadenitis (2), panosteitis, and intervertebral disc disease.
Atticus Sandler Hewitt	
SPECIES	Overall, the most common causes across all cases were polyarthritis (44), lymphoid neoplasia (15), discospondylitis (8), myelodysplasia (8), hypertrophic osteodystrophy (6), and blastomycosis (6).
Feline	
BREED	<u>Clinical Signs:</u> Animals usually present with either persistent or waxing and waning fevers ranging from 103°F to 106°F. Other clinical signs depend on the underlying cause of the fever. Careful and thorough physical examination is required to assess potential causes.
Domestic Shorthair	
SEX	<u>Diagnostics:</u> F.U.O etiologies are partly related to geography, and thus locale or travel history should factor into a practitioner's diagnostic approach. A patient's lifestyle may also provide clues regarding exposure to certain etiologic agents. Therefore, conducting a thorough history can unveil important pieces of the diagnostic puzzle. Physical examination is especially important and should include an inspection of all accessible lymph nodes, palpation and movement of the joints, a fundic examination, a neurological evaluation, spinal and limb palpation and range of motion tests, and a rectal examination.
Neutered male	
AGE	A minimum database should include a CBC reviewed by a clinical pathologist, as well as a biochemical profile and urinalysis. Retroviral testing should also be considered in cats. In areas where tick-borne disease is prevalent, in-house testing should be performed early. Advanced laboratory work can include: urine culture, blood culture, and infectious disease panels (PCR and/or serology). In dogs, one may screen for the following infectious agents: <i>Ehrlichia</i> spp., <i>Borrelia burgdorferi</i> , Rock Mountain Spotted Fever, <i>Bartonella</i> spp. (culture and PCR), and <i>Leptospira</i> spp. in cases of hepatic or renal involvement. In cats, one should evaluate for FeLV, FIV, feline infectious peritonitis (FIP) virus, toxoplasmosis, <i>Hemoplasma</i> spp. (<i>Mycoplasma</i>), and <i>Bartonella</i> spp. (culture and PCR). Testing for <i>Ehrlichia</i> spp., <i>Rickettsia</i> spp., and <i>Anaplasma phagocytophilum</i> can also be considered. A fungal assay is indicated if the patient lives in or has had exposure to a region with a higher incidence of fungal disease. Other infectious disease tests may be performed depending on the geographical location of the pet. Screening for <i>Brucella</i> should be done in breeding dogs. Immune-mediated disease screening can include a Coomb's test, a slide agglutination test (if the patient is anemic), and an antinuclear antibody (ANA) test. Immune disease is often a diagnosis of exclusion.
8 years	
WEIGHT	Imaging should include thoracic radiographs, abdominal ultrasound, and/or abdominal radiographs. Ultrasound can be very useful for assessing evidence of cholangiohepatitis, pyelonephritis, chronic urinary tract infection, abscess formation, peritonitis, and neoplasia; it also permits an examination of the intra-abdominal lymph nodes. An echocardiogram can offer assessment for vegetative endocarditis, whereas spinal radiographs offer assessment for discospondylitis. In cases where all other testing has proven negative and the patient has not responded to broad-spectrum antibiotics and supportive care, arthrocentesis should be considered to evaluate for septic joint disease, immune-mediated polyarthritis, and infectious disease. Finally, one can consider assessing the cerebrospinal fluid for meningoencephalitis, GME, and meningitis/arteritis. A bone marrow exam should be performed if blood dyscrasias are noted on the CBC.
13.47 ;bs	
INTERPRETED BY	
Eric Lindquist, DMV, DABVP, Cert. IVUSS	
IMAGING PERFORMED BY	
Jenna Walsh, CVT	
HOSPITAL NAME	
West Eugene AH	
REFERRING VET	<u>Treatment:</u> Treatment of the fever depends entirely on the underlying cause. Ideally, a thorough diagnostic plan will yield a diagnosis that will guide the appropriate therapeutic course. However, if an exhaustive approach has not produced a definitive diagnosis and there is no response to broad-spectrum antibiotics, trial therapy with immunosuppressive agents such as prednisolone can be considered to treat presumed immune-mediated diseases. Given the potential for negative sequelae should an underlying infection be present, one must be certain that the investigation is thorough and monitor the patient's response carefully.
Dr. Seyler	
DATE	
12/22/21	
Invoice	
94846	



PATIENT

Atticus Sandler Hewitt

SPECIES

Feline

BREED

Domestic Shorthair

SEX

Neutered male

AGE

8 years

WEIGHT

13.47 ;bs

INTERPRETED BY

Eric Lindquist, DMV,
DABVP, Cert. IVUSS

IMAGING PERFORMED BY

Jenna Walsh, CVT

HOSPITAL NAME

West Eugene AH

REFERRING VET

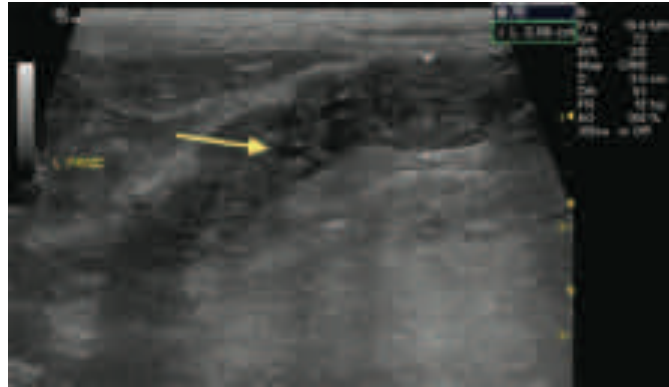
Dr. Seyler

DATE

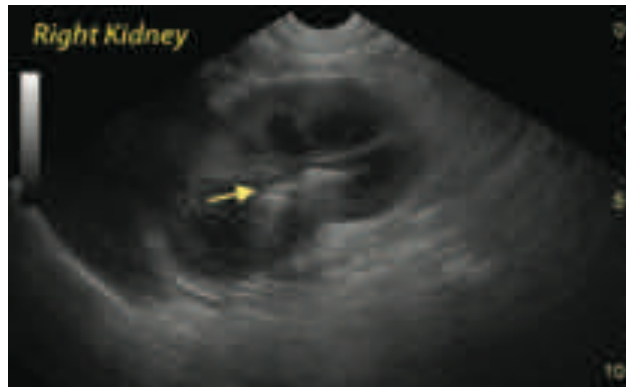12/22/21

Invoice
94846

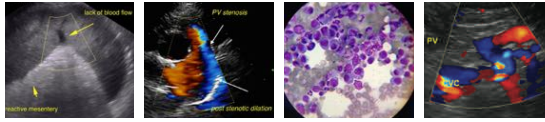
Conclusion: If a documented fever has not responded to antibiotics, antipyretics, or general nursing care, it is important to obtain a diagnosis to guide more specific treatment. A systematic physical examination and thorough history-taking will help inform further diagnostics in addition to what is revealed by the minimum database.



Long axis of the left pancreatic limb (between calipers) in a cat with pancreatitis after undergoing a renal transplant. Note the decrease in echogenicity and mild loss of regular echotexture of the swollen and irregularly contoured pancreas. Also note the mild dilation of the pancreatic duct (arrow). Focal peritonitis is evident by increased echogenicity and loss of the linear echotexture of the surrounding mesentery.



Long axis of the right kidney in a dog with pyelonephritis. Note the increased echogenicity and irregular outline of the renal crest and diverticuli and the mild dilation of the renal pelvis (arrow).



PATIENT

Atticus Sandler Hewitt

SPECIES

Feline

BREED

Domestic Shorthair

SEX

Neutered male

AGE

8 years

WEIGHT

13.47 ;bs

INTERPRETED BY

Eric Lindquist, DMV,
DABVP, Cert. IVUSS

IMAGING PERFORMED BY

Jenna Walsh, CVT

HOSPITAL NAME

West Eugene AH

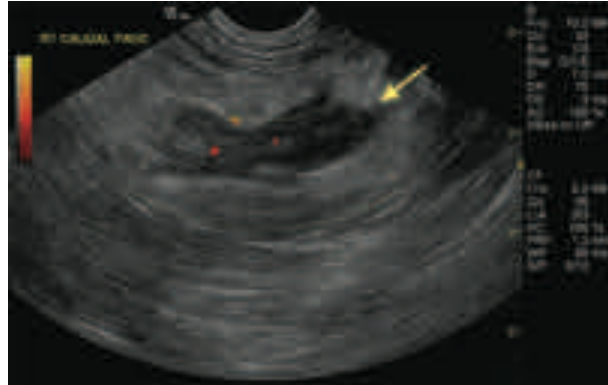REFERRING VET

Dr. Seyler

DATE

12/22/21

Invoice
94846



Long axis of the right pancreatic limb in a dog with acute pancreatitis. The swollen hypoechoic pancreas is embedded in hyperechoic mesenteric fat (arrow). Note the regional differences in blood flow intensity within the parenchyma as demonstrated by Power Doppler interrogation compatible with multifocal disruption of vascularization as a sequela of the severe inflammation.

References:

Bennet D. Diagnosis of pyrexia of unknown origin. *In Practice* 1995;17(10):470-81.

Dunn KJ, Dunn JK. Diagnostic investigations in 101 dogs with pyrexia of unknown origin. *J Sm Anim Pract* 1998;39(12):574-80.

Flood J. The diagnostic approach to fever of unknown origin in cats. *Compend Contin Educ Vet* 2009;31(1):26-31.

Flood J. The diagnostic approach to fever of unknown origin in dogs. *Compend Contin Educ Vet* 2009;31(1):14-21.

Lappin MR. The role of blood borne pathogens in feline fever of unknown origin. Proceedings from the American College of Veterinary Internal Medicine, Denver, CO, June 15-18, 2011.

Lunn KF. Fever of unknown origin: a systematic approach to diagnosis. *Compend Contin Educ Vet* 2001;23(11):976-92.

Lunn KF. Fever of unknown origin: appropriate choice of diagnostic tests. Proceedings from the American College of Veterinary Internal Medicine, Minneapolis, MN, June 9-12, 2004.