

PATIENT PRESENTING CLINICAL SIGNS

Cracker Johnson History: Coughing for months, dental disease, lenticular sclerosis
Abnormal PE/Chem/CBC/UA Results: Pulse 90, respiration 24

SPECIES

Canine

BREED

Pomeranian

SEX

Spayed female

AGE

13 years

WEIGHT

4.55 lbs

INTERPRETED BY

Eric Lindquist, DMV,
DABVP, Cert. IVUSS

IMAGING PERFORMED BY

Sara Hansen

HOSPITAL NAME

Countryside AC

REFERRING VET

Dr. Cox

DATE

12/21/22

Invoice
42307

ULTRASONOGRAPHIC EXAMINATION OF THE HEART

The echocardiogram in this patient demonstrated normal **left atrial** size based on 3 different LA measurement methods. Chamber volumes and echogenicity were normal. The cranial and caudal **mitral** valve leaflets presented vegetative thickening consistent with endocardiosis. Mitral insufficiency was centralized and mild to moderate. Doppler indicated measurable insufficiency. The **left ventricle** presented normal thicknesses with linear contour and was not dilated nor restricted. The **myocardium** presented normal echogenicity without subjective evidence of significant fibrotic or ischemic disease. **Contractility** of the ventricular walls was adequate and in normal range for this patient evidenced by the fractional shortening measurement and subjective evaluation of the different regions of the myocardium. Trivial aortic insufficiency was noted. The **right atrium** and auricle revealed normal size, structure and content. No evidence of masses was noted or chamber overload. **Tricuspid** valvular assessment demonstrated adequate linear morphology. The **right ventricle** was of normal size (1/3 diameter of LV), chordae structure, myocardial echogenicity and thickness. Minor **pulmonic** velocity was noted. No visible **pericardial** or free pleura fluid was noted. No echographically detectable evidence of infiltrative disease was visible. The cranial **mediastinum and pericardial regions** were free of masses in the visible window. The hepatic veins were not dilated.

CANINE CARDIAC PARAMETERS	MR VMAX (m/s)	TR VMAX (m/s)	LA/AO (Boon method)	LA/AO (Heart Base; Swe)	FS (%)	EF (%)	EPSS (cm)
NORMAL PARAMETER	4.5-5.5	<2.7	1.3	<1.6	28-40	40-100	<0.6
PATIENT	>5.0	1.62	1.3	1.4			0.2
CANINE CARDIAC PARAMETERS	HR (BPM)	AV VMAX (m/s)	PV MAX (m/s)	BODY WEIGHT	LA (2D short axis Base view) (cm)	LVIDd (Avg; 2D and m-mode short axis) (cm)	LVIDs (Avg; 2D and m-mode short axis) (cm)
NORMAL PARAMETER	50-100	0.7-1.7	0.7-1.6	BELOW	BELOW	BELOW	BELOW
PATIENT		2.0	0.71	4.55 lbs	1.7 max		



PATIENT **ULTRASONOGRAPHIC FINDINGS**

Cracker Johnson Stage B1 valvular disease, compensated.

SPECIES **INTERPRETATION OF THE FINDINGS & FURTHER RECOMMENDATIONS**

Canine The cough is non-cardiogenic in this patient. Primary respiratory protocol is recommended based on chest radiographs +/- chest CT would be appropriate.

BREED

Pomeranian

The heart is stable without clinical disease. No overt contraindication for anesthesia of brief to moderate duration. I suggest Torbutrol premed, Propofol induction, Isoflor maintenance or similar protocol if anesthesia is desired. Blood pressure recommended if not already performed and target white coat negative systolic pressure of < 160 mmHg. If higher than this ACE-inhibitor is suggested to reach this level. Recheck echocardiogram is recommended in 6 months, earlier if murmur grade increases or clinical signs initiate.

AGE

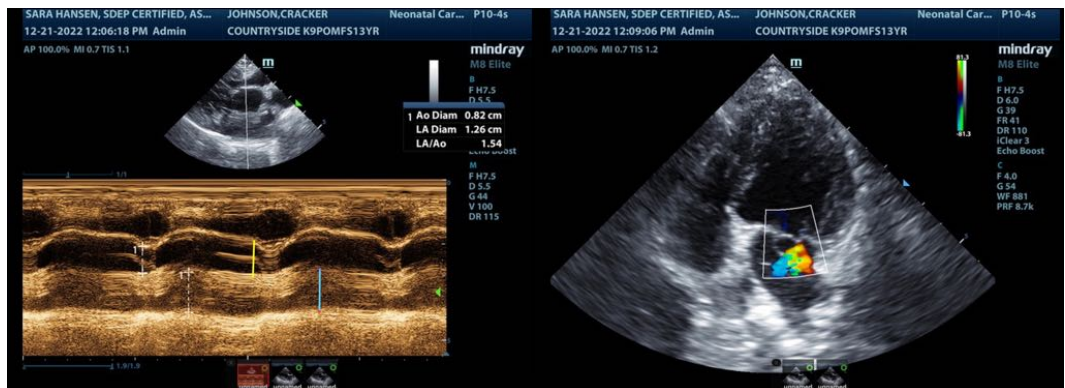
13 years

WEIGHT

4.55 lbs

INTERPRETED BY

Eric Lindquist, DMV,
 DABVP, Cert. IVUSS



IMAGING PERFORMED BY

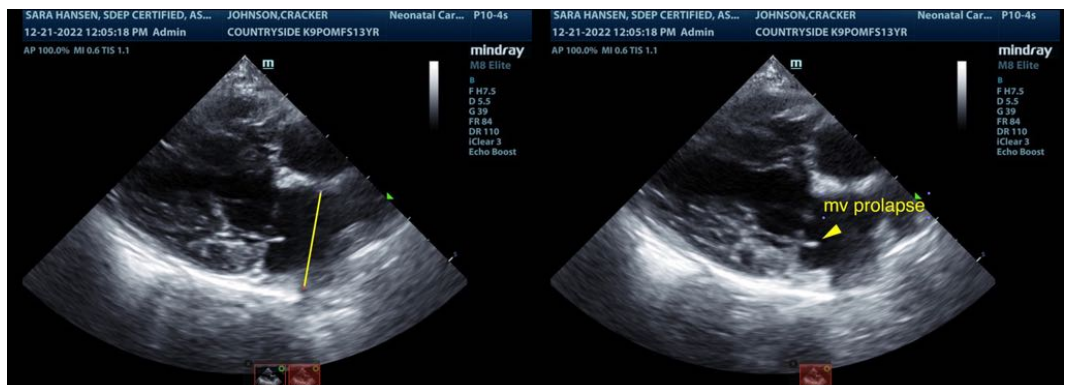
Sara Hansen

HOSPITAL NAME

Countryside AC

REFERRING VET

Dr. Cox



DATE

12/21/22

Invoice
 42307



PATIENT

Cracker Johnson

SPECIES

Canine

BREED

Pomeranian

SEX

Spayed female

AGE

13 years

WEIGHT

4.55 lbs

INTERPRETED BY

Eric Lindquist, DMV,
DABVP, Cert. IVUSS

IMAGING PERFORMED BY

Sara Hansen

HOSPITAL NAME

Countryside AC

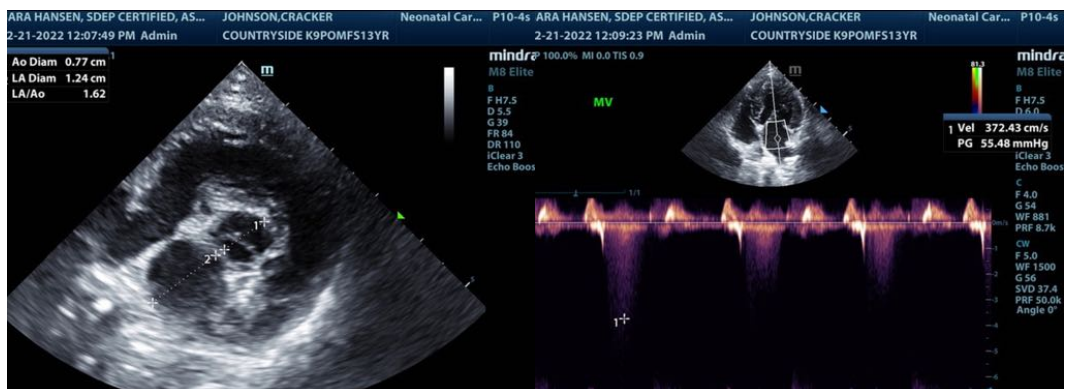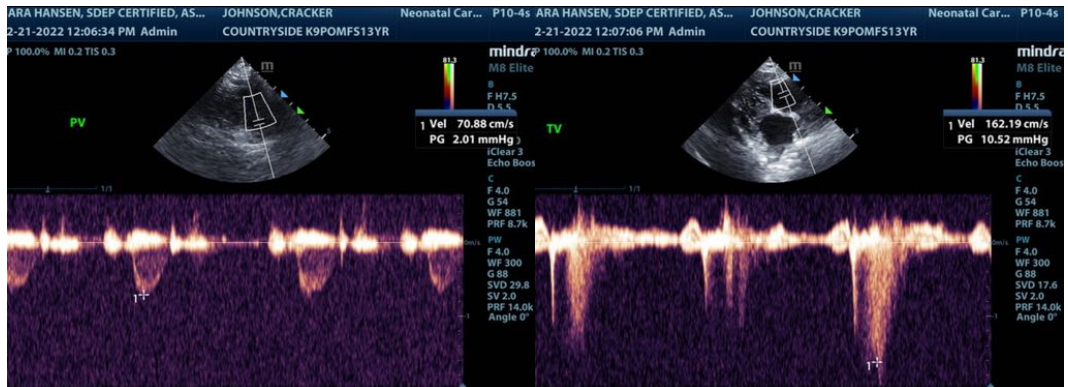
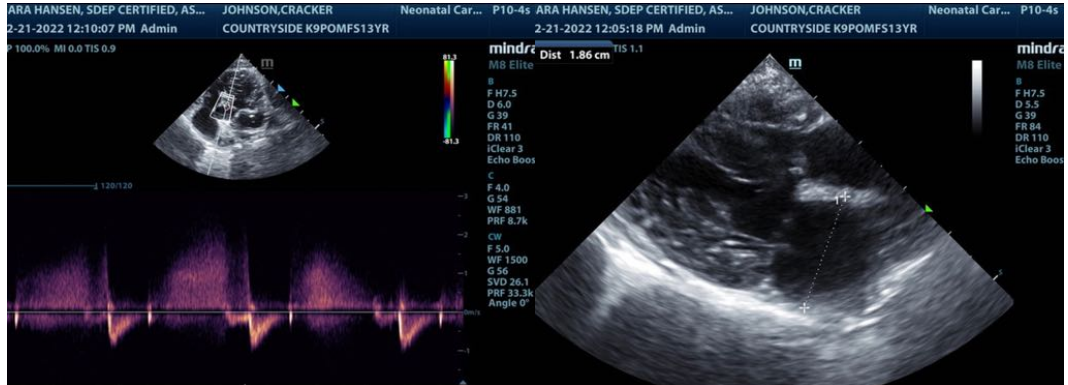
REFERRING VET

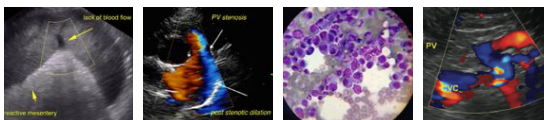
Dr. Cox

DATE

12/21/22

Invoice
42307





PATIENT

Cracker Johnson

SPECIES

Canine

BREED

Pomeranian

SEX

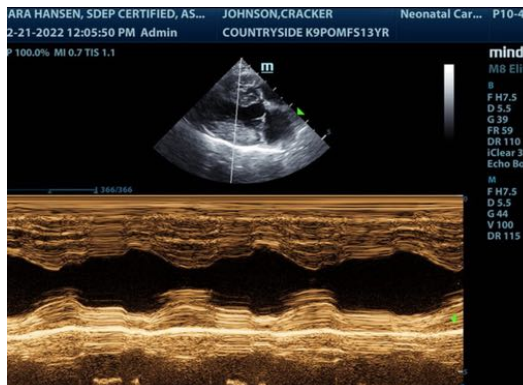
Spayed female

AGE

13 years

WEIGHT

4.55 lbs



The information and recommendations provided are based on the images presented by the referring veterinarian/sonographer. No evaluation can be communicated regarding pathology that was not visible in the image/video clips provided.

Thank you for this referral. If the clinical or image interpretation does not parallel your findings or if I can be of any further assistance please contact me.

Eric Lindquist, DMV, DABVP, Cert. IVUSS

CEO of Sonopath.com

Eric.Lindquist@SonoPath.com

INTERPRETED BY

Eric Lindquist, DMV, DABVP, Cert. IVUSS

IMAGING PERFORMED BY

Sara Hansen

HOSPITAL NAME

Countryside AC

REFERRING VET

Dr. Cox

DATE

12/21/22

Invoice
42307