



**PATIENT**

Diesel Thompson

**SPECIES**

Feline

**BREED**

Domestic Shorthair

**SEX**

Neutered male

**AGE**

14 years

**WEIGHT**

5.94 lbs

**INTERPRETED BY**

Eric Lindquist, DMV,  
DABVP, Cert. IVUSS

**IMAGING PERFORMED BY**

Jenna Walsh, CVT

**HOSPITAL NAME**

VCA Salem AH

**REFERRING VET**

Dr. Wermuth

**DATE**

12/2/21

**Invoice**

**PRESENTING CLINICAL SIGNS**

History: Chronic weight loss and constipation  
Abnormal PE/Chem/CBC/UA Results: ALT in 500s, AST in 400s. Mildly hyperthyroid- T4 grey zone FT4ED 69

**ULTRASONOGRAPHIC EXAMINATION OF THE ABDOMEN**

**Urinary System**

The **urinary bladder**, trigone, and pelvic urethra presented normal thicknesses and normal tone. The ureters were not visible which is normal. No uroliths or sediment were visualized and anechoic urine was present. No evidence of inflammatory or neoplastic changes was noted. Ureteral papillae were normal.

The **kidneys** presented a relatively uniform cortical hyperechogenicity when compared to the renal medulla, spleen and liver. No overt masses were noted. Corticomedullary definition was nebulous and the ratio favored the cortex slightly. The ureters were not visible and assumed to be normal. These changes are most consistent with chronic interstitial nephritis yet infiltrative disease could not be entirely ruled out without biopsy though neoplasia is not suspected. The right kidney measured 3.68 cm.

**Adrenal Glands**

The **adrenal glands** were uniform, yet bilaterally swollen and hypoechoic. This is most consistent with stress-induced hyperplasia. The right adrenal gland measured 0.47 cm.

**Spleen**

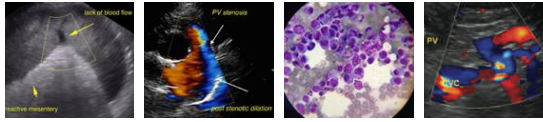
The **spleen** in this patient was uniform, yet volume contracted. Hydration status should be assessed.

**Liver**

The **liver** was diffusely hyperechoic to the falciform fat. The liver revealed moderate increased portal markings. The liver had coarse architecture. The gallbladder was mildly over distended with suspended and dependent debris, yet not to the level of emerging mucocele. However, the sludge appears to be mildly excessive. No adjunctive inflammation was noted.

**Gastrointestinal**

The **gastrointestinal tract** revealed minor variable thickening and echogenic submucosal changes most consistent with low grade end result of chronic GI disease such as IBD and may be related to malassimilation of nutrients if any weight loss is present. Reactive mesentery was noted associated with the gastrointestinal tract.



**PATIENT**

**Pancreas**

Diesel Thompson

The base and limbs of the **pancreas** were observed to be largely isoechoic to surrounding omental fat. Pancreatic duct and capsular contour were acceptably normal and parenchyma respected normal curvilinear patterns. No overt evidence of active inflammatory or neoplastic disease was noted.

**SPECIES**

Feline

**ULTRASONOGRAPHIC FINDINGS**

**BREED**

Mild diffuse intestinal thickening.

Domestic Shorthair

Chronic inflammatory hepatopathy. Non-specific chronic cholangitis, cholangiohepatitis pattern.

Chronic interstitial nephrosis renal pattern.

**SEX**

Neutered male

**INTERPRETATION OF THE FINDINGS & FURTHER RECOMMENDATIONS**

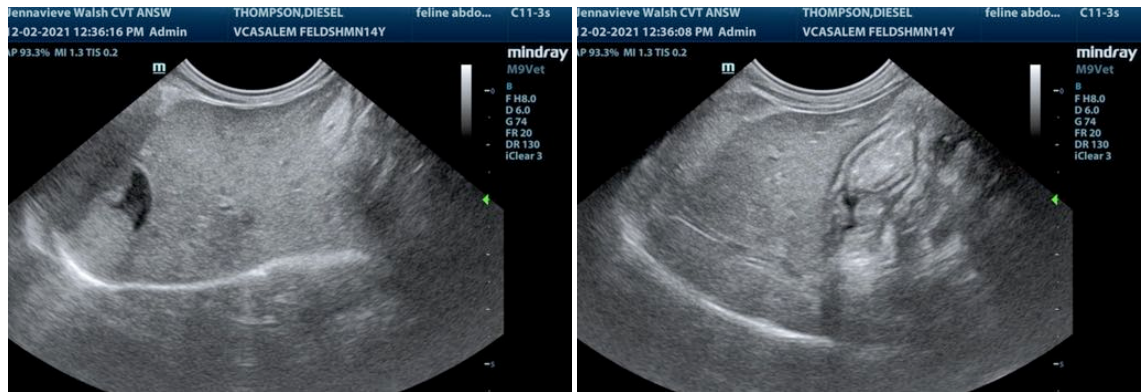
**AGE**

14 years

There was no overt evidence of neoplasia. Coagulation panel and 25-22 gauge FNA of the liver is warranted to assess for inflammatory cell type. Chronic infectious agents should be considered if exposed such as Bartonella, Toxoplasmosis.

**WEIGHT**

5.94 lbs

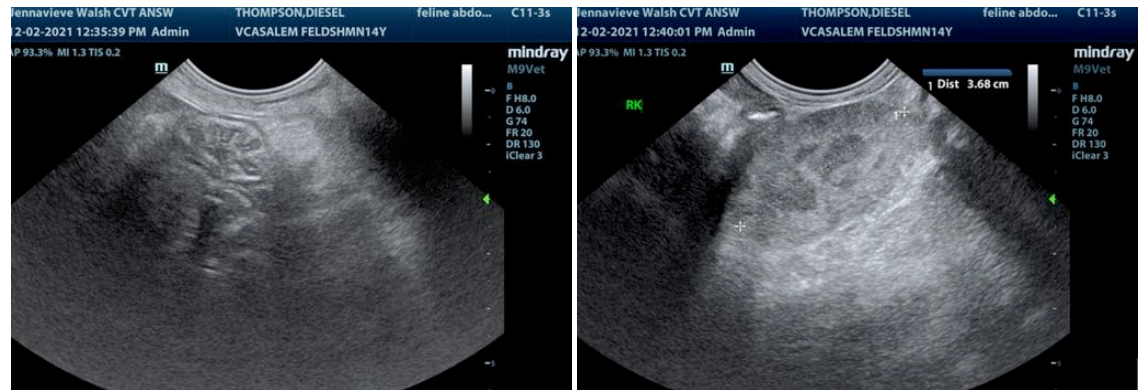


**INTERPRETED BY**

Eric Lindquist, DMV,  
DABVP, Cert. IVUSS

**IMAGING PERFORMED BY**

Jenna Walsh, CVT



**HOSPITAL NAME**

VCA Salem AH

**REFERRING VET**

Dr. Wermuth

**DATE**

12/2/21

**Invoice**



**PATIENT**

Diesel Thompson

**SPECIES**

Feline

**BREED**

Domestic Shorthair

**SEX**

Neutered male

**AGE**

14 years

**WEIGHT**

5.94 lbs

**INTERPRETED BY**

Eric Lindquist, DMV,  
DABVP, Cert. IVUSS

**IMAGING PERFORMED BY**

Jenna Walsh, CVT

**HOSPITAL NAME**

VCA Salem AH

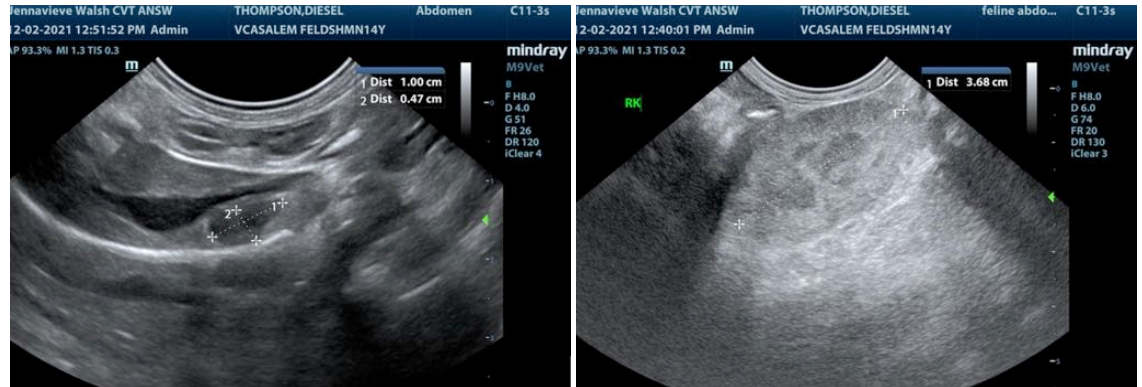
**REFERRING VET**

Dr. Wermuth

**DATE**

12/2/21

**Invoice**




The information and recommendations provided are based on the images presented by the referring veterinarian. No evaluation can be communicated regarding pathology that was not visible in the image/video clips provided.

Thank you for this referral. If the clinical or image interpretation does not parallel your findings or if I can be of any further assistance please contact me.

**Eric Lindquist, DMV, DABVP, Cert. IVUSS**

CEO of SonoPath.com

Eric.Lindquist@SonoPath.com



The following is an applicable excerpt from the *Curbside Guide to Diagnosis & Treatment of Sonographic Disease* offered by [SonoPath.com](http://sonopath.com) Lindquist, Frank, Lobetti, and Modler.

An essential quick guide for every general practitioner and sonographer.

<https://sonopath.com/products/curbside-guide-editing-due-release-12012015>

**Feline Liver Disease & Treatment Recommendations**

<http://www.sonopath.com/FelineLiverDisease>



**PATIENT**

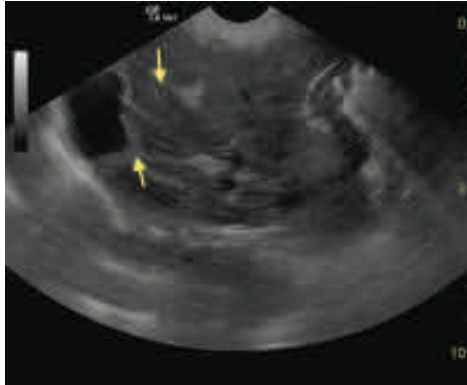
Diesel Thompson

**SPECIES**

Feline

**BREED**

Domestic Shorthair



Subxiphoid short axis of the liver in a cat with nodular hyperplasia. Note the presence of multifocal hyper/isoechoic nodules throughout the hepatic parenchyma. This is a non specific finding consistent with chronicity that merits core biopsy to evaluate architectural pathology and rule out neoplasia as opposed to FNA that would assess only cells. Note the arrows that delineate an isoechoic nodule subtly deviating the gall bladder contour.

**SEX**

Neutered male

**AGE**

14 years

**WEIGHT**

5.94 lbs

**INTERPRETED BY**

Eric Lindquist, DMV,  
DABVP, Cert. IVUSS

**Description:** Liver disease is a common clinical condition in cats; however, it can be subdivided into specific disease categories. Cats most often develop feline cholangitis, which is comprised of various forms of inflammatory liver disease or hepatic lipidosis; however, there are other disease processes, including neoplasia, infectious disease, and toxicities, that result in hepatic dysfunction. This chapter will focus predominantly on feline cholangitis and hepatic lipidosis; hepatic neoplasia is discussed in greater detail in a separate chapter.

1. Feline cholangitis complex is one of the most significant diseases in cats. The term “complex” embodies many different disease processes, each with its own signs and treatment protocols. The World Small Animal Veterinary Association (WSAVA) liver Standardization Group classifies feline cholangitis accordingly: neutrophilic cholangitis, which includes both acute and chronic neutrophilic cholangitis (these are likely extensions of the same disease process); lymphocytic cholangitis; and cholangitis associated with a liver fluke infection.

**IMAGING PERFORMED BY**

Jenna Walsh, CVT

a) Acute neutrophilic cholangitis is a suppurative disease process of the liver and is most commonly seen in young to middle-aged cats. Acute cholangitis is almost always of bacterial origin, with enteric isolates being the most common culprits (these are thought to ascend from the biliary tree). Pancreatitis and inflammatory bowel disease (IBD) are associated disease processes. Histopathologically, this disease is represented by suppurative inflammation within the walls and lumen of the biliary ducts, and may extend into the portal triads and possibly into the hepatic parenchyma.

**HOSPITAL NAME**

VCA Salem AH

**REFERRING VET**

Dr. Wermuth

b) Chronic neutrophilic cholangitis is either neutrophilic or lymphoplasmacytic, and arises from the acute form. Inflammation is centered around the portal region and includes lymphocytes, plasma cells, and neutrophils. Inflammation can also extend into the surrounding parenchyma and is sometimes noted within the lumen of the bile duct. Current research is investigating the role of *Bartonella* species in the development of chronic cholangitis; other postulated etiologies include a *Helicobacter* infection and immune-mediated processes. Biliary hyperplasia occurs secondary to the chronicity of the disease, and fibrosis and/or cirrhosis represent the end-stage manifestation of these foregoing disease processes. Cirrhosis is a rare condition in the cat because most cats either succumb or undergo successful

**DATE**

12/2/21

**Invoice**



**PATIENT**

Diesel Thompson

treatment prior to this stage. Cats with chronic neutrophilic cholangitis often have chronic pancreatitis and IBD (triaditis). These other diseases may be responsible for the immune-mediated destruction of the liver that is commonly seen with the chronic form. The fact that the bile and pancreatic ducts are anatomically close to one another in cats may be the reason for coinfection and explain why the diseases occur in tandem.

**SPECIES**

Feline

Severe lymphocytic cholangitis is defined as chronic inflammation of the biliary tract infiltrated by small lymphocytes. Cats with lymphocytic cholangitis are usually ill for months or years. This disease is more common in Europe than North America, and is manifested as a chronic inflammatory disease, which ultimately leads to fibrosis and cirrhosis. Chronic infections are thought to be the result of *Helicobacter pylori* infections and immune-mediated diseases. There is a greater predisposition in both Persian and younger cats to chronic forms.

**BREED**

Domestic Shorthair

**SEX**

Neutered male

c) Lymphocytic portal hepatitis is characterized by mild lymphocytic inflammation around the portal areas, but no inflammation within the bile ducts or hepatic parenchyma. This is a common finding upon biopsy, and although it can be nonspecific and incidental, it is also thought to indicate a reactive hepatopathy secondary to extrahepatic disease.

**AGE**

14 years

**WEIGHT**

5.94 lbs

d) In tropical and subtropical geographic areas, cholangitis is associated with fluke infestation secondary to infection with *Platynosomum* spp. Cats become infected by ingesting the second intermediate host (reptiles and amphibians). The fluke infection results in cystic dilation and bile duct thickening as well as obstruction.

**INTERPRETED BY**

Eric Lindquist, DMV,  
DABVP, Cert. IVUSS

2. Hepatic lipidosis (HL) is one of the most common causes of hepatic disease in cats. It is defined as an accumulation of lipid within the cytoplasm of the hepatocyte. This can be idiopathic (primary) or can occur secondary to other diseases, and results in anorexia and weight loss. The pathophysiology is multifactorial and due to dysregulation of lipid metabolism in a catabolic state, which leads to excess accumulation of intracellular lipid within the hepatocyte.

**IMAGING PERFORMED BY**

Jenna Walsh, CVT

Other common causes of liver enzyme elevation in cats include hepatocellular thyrotoxicosis, infectious diseases (e.g. *Toxoplasma* and FIP), and primary and metastatic neoplasia. In hepatic toxicosis, thyroid hormones have a direct toxic effect on liver cells and stimulate increased liver enzyme activity. Moreover, increased intestinal motility secondary to hyperthyroidism can cause increased oxygen utilization and thus hepatic hypoxia, which ultimately leads to hepatic dysfunction. Acute cholangitis cannot be fully ruled out without conducting a biopsy. Owner (and patient) compliance with methimazole should be evaluated. The methimazole dose may need to be increased or other treatment modalities explored, including radioactive iodine, thyroidectomy, and/or dietary therapy with restricted iodine, such as the therapeutic diet, Hill's® y/d®. It should be noted that methimazole can also cause a drug-induced toxicosis and that this can also result in liver enzyme elevation.

**HOSPITAL NAME**

VCA Salem AH

**REFERRING VET**

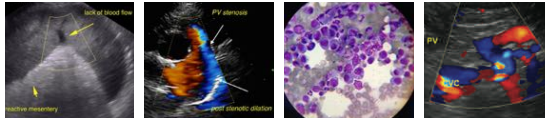
Dr. Wermuth

**DATE**

12/2/21

**Clinical signs:**

**Invoice**



**PATIENT**

Diesel Thompson

Cholangitis: Because of the acute suppurative nature of acute neutrophilic cholangitis, clinical signs commonly include pyrexia and jaundice, accompanied by vomiting, diarrhea, and lethargy. Of the four main complex types discussed above, acute cholangitis patients normally present as the most severely ill. A chemistry panel often reveals a moderate increase in ALT, ALP, GGT, bilirubin, and bile acids, while a CBC commonly shows an elevated white blood cell count (WBC) with or without a left shift.

**SPECIES**

Feline

Cats suffering from the remaining types of feline cholangitis normally display less severe signs, but have likely been sick for a longer period of time. Those with chronic neutrophilic cholangitis can have intermittent episodes of jaundice and vomiting, which are cyclic and self-resolving. Weight loss, anorexia, and lethargy are common, and one typically observes elevations in ALP, GGT, bilirubin, and bile acids. The degree of elevation in ALT and AST is variable.

**BREED**

Domestic Shorthair

**SEX**

Neutered male

Patients with severe lymphocytic cholangitis exhibit weight loss and anorexia; however, because it is a slow-moving, progressive disease, signs may be chronic and mild. Liver enzyme elevations are generally mild until the chronic phase when icterus occurs as well as ascites. Hypergammaglobulinemia is also a prominent feature of this disease.

**AGE**

14 years

Cats with fluke infestations are either asymptomatic or systemically ill with pyrexia, vomiting, anorexia, icterus, and bile duct obstruction. A CBC may indicate marked liver enzyme elevations as well as an eosinophilia. Cats with lymphocytic portal hepatitis are asymptomatic and do not demonstrate laboratory abnormalities.

**WEIGHT**

5.94 lbs

**INTERPRETED BY**

Eric Lindquist, DMV,  
DABVP, Cert. IVUSS

Hepatic lipidosis: The most common clinical signs are anorexia, vomiting, diarrhea, icterus, lethargy, depression, ptialism, and weight loss. Since HL occurs in the face of so many other diseases, clinical signs may vary and be due, in part, to the underlying disease process. Likewise, lab work abnormalities can also vary, depending on concurrent disease processes. Hepatic encephalopathy may ensue, resulting in severe weakness, depression, and ptialism. Common CBC abnormalities include a nonregenerative anemia, stress leucogram, poikilocytosis, and the presence of Heinz bodies. On the serum chemistry, an elevation in ALP is disproportionate to GGT levels, which are usually within normal limits. Serum ALT is variably increased, but typically of a lower magnitude than that of ALP. Bilirubin is increased due to intrahepatic cholestasis. Bile acids are increased, but are a superfluous indicator in the face of hyperbilirubinemia. The BUN and albumin may be normal or subnormal. Coagulation abnormalities occur in cats with HL due to vitamin K deficiency, which is a result of malabsorption in the intestines and decreased production of coagulation factors in the liver due to severe hepatic dysfunction.

**IMAGING PERFORMED BY**

Jenna Walsh, CVT

**HOSPITAL NAME**

VCA Salem AH

**REFERRING VET**

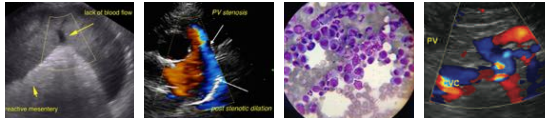
Dr. Wermuth

Cats with thyroid toxicosis mainly exhibit clinical signs of hyperthyroidism. The chief abnormalities on serum chemistry are a mild to moderate elevation in ALT and elevated T4 levels. In the event of methimazole toxicity, the ALT can also be mild to moderately elevated. Cats with hepatic neoplasia may also demonstrate similar signs to other forms of hepatic disease, display elevations in ALT, ALP, GGT, and AST, and exhibit a leukocytosis and possibly anemia of chronic disease. This condition is discussed in greater detail in the chapter on "Hepatic Neoplasia."

**DATE**

12/2/21

**Invoice**



## PATIENT

Diesel Thompson

## SPECIES

Feline

## BREED

Domestic Shorthair

## SEX

Neutered male

## AGE

14 years

## WEIGHT

5.94 lbs

## INTERPRETED BY

Eric Lindquist, DMV,  
DABVP, Cert. IVUSS

## IMAGING PERFORMED BY

Jenna Walsh, CVT

## HOSPITAL NAME

VCA Salem AH

## REFERRING VET

Dr. Wermuth

## DATE

12/2/21

## Invoice

**Diagnostics:** Ultrasound and interventional ultrasound are important means of definitively diagnosing hepatic disease in cats. An ultrasound-guided core biopsy of the liver can be performed to acquire both histopathology and aerobic/anaerobic cultures. Alternatively, a larger tissue biopsy can be obtained via laparoscopy or laparotomy. In the event that a laparotomy or laparoscopy is performed, biopsies of the small intestine and pancreas should be obtained. One will also often encounter triaditis. Ultrasound-guided centesis of the gallbladder can be done to collect bile for culture and is preferred over hepatic parenchymal cultures. Ultrasound additionally allows for visualization of choleliths and obstruction to bile flow; it also helps determine whether surgical intervention is required. In the case of HL, the sonographic appearance presents as a uniform, diffuse, dense hyperechoic parenchyma that is hyperechoic to falciform fat and spleen; however, a primary underlying disease may also be present, such as cholangitis or lymphoma. In cats with suspected HL, fine needle aspiration (FNA) is the safest way to rule this out and to evaluate for lymphoma, as cytology is especially useful in the diagnosis of both these diseases. Lipidotic livers are friable and hence bleeding can occur as a complication of biopsy due to poor tissue integrity, lack of tissue hemostasis, and possibly compromised systemic hemostasis due to poor hepatic function. Cholangitis and neoplasia can be suspected on cytology, but a hepatic biopsy is preferred in order to define architecture, inflammatory infiltrate, and fibrosis. The clinician must weigh the risks and benefits of obtaining a biopsy in patients that may have a concurrent disease or are unresponsive to conventional therapy for HL. Pretreatment with vitamin K1 and aggressive supportive care may aid in stabilizing a patient for biopsy.

Cholangitis associated with liver flukes is uncommon in North America, but if the patient is in a tropical or subtropical location, the diagnosis is either obtained by fecal examination or liver biopsy, which permits observation of the flukes and/or their eggs within the bile ducts.

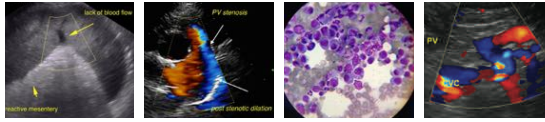
**Treatment:** The following medications are suggested in keeping with general guidelines for treatment for feline hepatic disease; however, each patient should be assessed and treated as an individual, and management should be tailored according to a specific diagnosis.

### Disease-specific recommendations:

1. Feline cholangitis complex

a) Acute neutrophilic cholangitis and chronic neutrophilic cholangitis:

- **Antibiotics:** Administration of antibiotics should ideally be based on culture and sensitivity. If a culture is not available, one may treat with broad-spectrum antibiotics, such as amoxicillin (10-20 mg/kg PO BID), amoxicillin clavulanic acid (10 mg/kg PO BID or 62.5 mg PO BID), a cephalosporin, such as cefadroxil (20 mg/kg PO BID), or enrofloxacin (5 mg/kg PO once daily). Antibiotics can be used for 4-8 weeks. Metronidazole (11-22 mg/kg PO BID) can be given as an



**PATIENT**

Diesel Thompson

anti-inflammatory medication; it also has an anaerobic spectrum. Metronidazole also decreases ammonia produced by intestinal microbes (administer at 7.5 mg/kg PO BID-TID in cases of hepatic encephalopathy).

**SPECIES**

Feline

b) Chronic neutrophilic cholangitis (lymphoplasmacytic inflammation):

**BREED**

Domestic Shorthair

- An anti-inflammatory medication should be given when biopsy reveals that there has been significant infiltration with lymphocytes and/or plasma cells, or if the patient is not responding to antibiotic medication alone (in the absence of a biopsy).
- Prednisolone should be given at 1-2 mg/kg/day. Start at a higher dose, and wean over time to every other day in decreasing dosages every 2-4 weeks following the resolution of signs. Additional immunosuppressant medications are not typically used in cats for this disease.

**SEX**

Neutered male

**AGE**

14 years

c) Severe lymphocytic cholangitis:

**WEIGHT**

5.94 lbs

- Prednisolone should be dosed at 1-2 mg/kg/day; however, it remains controversial as to whether prednisolone is in fact effective in the course of this disease.
- Ursodiol (Actigall): 10-15 mg/kg PO Q24hr.

**INTERPRETED BY**

Eric Lindquist, DMV,  
DABVP, Cert. IVUSS

d) Liver fluke infection:

- Praziquantel: Give 20-30 mg/kg PO Q24hr for 3 days.

**IMAGING PERFORMED BY**

Jenna Walsh, CVT

2. Hepatic Lipidosis

**HOSPITAL NAME**

VCA Salem AH

- Hyperalimentation is crucial in the management of HL; it may also be necessary in the management of other hepatic diseases in cats that are not eating so as to prevent hepatic lipidosis as a complication. In order to determine the caloric needs of the patient, calculate the basal energy requirement using the formula  $BER = 70 \times BW^{0.75}$ . Multiply the BER by an illness energy requirement factor (1.25-1.4 in cats) and then select a therapeutic recovery diet with enhanced protein and fat levels, such as Hill's® a/d®, CliniCare® Liquid Diet (Abbott Animal Health), Royal Canin® Recovery RS™, or Iams® Maximum-Calorie™. Feed small, frequent meals through an esophagostomy tube (E tube), percutaneous endoscopic gastrostomy tube (PEG), or nasoesophageal tube (NE) tube. Give slowly over 15-30 minutes or trickle feed as a CRI. In cats that have been anorexic for a prolonged period of time, the amount of food should be gradually increased over 3 days' time. The food should be made into a slurry and warmed, and the total amount of food divided into 4-6 feedings per day. Flush the feeding tube with 5-15 ml warm water. Pretreatment with cisapride (1.25-2.5 mg/cat PO or 0.1-0.5

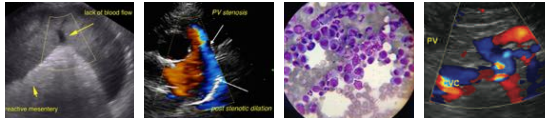
**REFERRING VET**

Dr. Wermuth

**DATE**

12/2/21

**Invoice**



**PATIENT**

Diesel Thompson

**SPECIES**

Feline

**BREED**

Domestic Shorthair

**SEX**

Neutered male

**AGE**

14 years

**WEIGHT**

5.94 lbs

**INTERPRETED BY**

Eric Lindquist, DMV,  
DABVP, Cert. IVUSS

**IMAGING PERFORMED BY**

Jenna Walsh, CVT

**HOSPITAL NAME**

VCA Salem AH

**REFERRING VET**

Dr. Wermuth

**DATE**

12/2/21

**Invoice**

mg/kg PO BID-TID) or metoclopramide (0.2-0.4 mg/kg PO or SC Q8hr) can prove helpful to improve gastric emptying; dosing should occur 30 minutes before feeding.

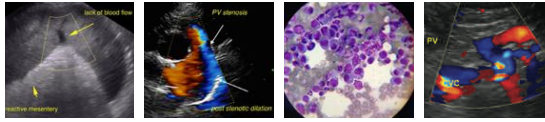
- Vitamin K1: Give 0.5-1.5mg/kg SQ or IM every 12 hours for a maximum of 2-3 doses if clotting times are increased. (The latter commonly occurs in the face of hepatic lipidosis due to decreased intestinal absorption of vitamin K as well as hepatic failure.)
- L-carnitine: Give 50-100 mg/kg PO Q24hr. L-carnitine is indicated in cats with severe hepatic lipidosis.
- Taurine: Give 250-500 mg PO Q24hr. Taurine can be administered as a supplement; it is an essential amino acid in cats.

3. Hepatic Encephalopathy:

- Lactulose: Give 0.5 ml/kg PO BID-TID to soften the stool. Lactulose helps manage hepatic encephalopathy by combining with ammonium in the GI tract and thus decreasing circulating ammonia levels. It can also be mixed into the slurry during feeding. Lactulose can also be given as a retention enema in an encephalopathic crisis.
- Metronidazole or neomycin: Give metronidazole at 7.5 mg/kg PO BID-TID. This is an antimicrobial, which reduces bacterial counts and reduces ammonia production in the colon. Alternatively, administer neomycin at 20 mg/kg PO BID-TID.
- L-Carnitine: Give 50-100 mg/kg PO Q24hr. Normally synthesized by the liver, L-carnitine enhances ammonia elimination and is indicated in cases of hepatic encephalopathy and lipidosis. Carnitine must be in the L-form.
- Diet: A low-protein diet with high amounts of biologically available protein is recommended in encephalopathic patients to reduce the nitrogen load from the breakdown of amino acids.

**General treatment recommendations for cats with either feline cholangitis complex or hepatic lipidosis:**

- IV Fluids: Fluid therapy is integral, especially in cats with severe liver disease as they are often inappetant and dehydrated. In the face of hepatic failure, avoid Lactated Ringer's solution (LRS) as lactate is metabolized by the liver. Monitor electrolytes closely. Add potassium in the form of potassium chloride (KCL); 20 mEq/L is a general starting point, but higher doses may be needed in the face of severe hypokalemia (maximum infusion rate is 0.5 mEq/kg/hr). Correct concurrent hypomagnesemia with magnesium sulfate or magnesium chloride at 0.75-1 mEq/kg/day given as a CRI for one day, and then reduce it to 0.3-0.5 mEq/kg/day. Monitor serum phosphorus levels and supplement as needed. Hypophosphatemia can occur following the reinstatement of feeding, especially in previously anorexic patients (re-feeding syndrome). Supplement phosphorus at 0.01-0.06 mmol/kg/hr using potassium phosphate or sodium phosphate.
- Vitamin B1 complex (thiamine) can also be added to the fluids at 1-2ml/liter. Note: Protect the fluid bag from light as the vitamins degrade when exposed to light.
- Vitamin B12 (cyanocobalamin) can be administered at 250 ug SC or IM weekly as needed in cases of HL or in cats with primary gastrointestinal disease.
- Famotidine can be given 0.5 mg/kg PO or IV once to twice daily as an antacid.



**PATIENT**

Diesel Thompson

**SPECIES**

Feline

**BREED**

Domestic Shorthair

**SEX**

Neutered male

**AGE**

14 years

**WEIGHT**

5.94 lbs

**INTERPRETED BY**

Eric Lindquist, DMV,  
DABVP, Cert. IVUSS

**IMAGING PERFORMED BY**

Jenna Walsh, CVT

**HOSPITAL NAME**

VCA Salem AH

**REFERRING VET**

Dr. Wermuth

**DATE**

12/2/21

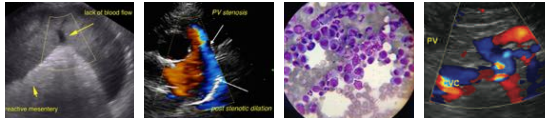
**Invoice**

- Ursodiol (Actigall): Give 10-15 mg/kg PO Q24hr, with food, to stimulate bile secretion and flow, and decrease cholestasis. It has immunomodulatory, anti-fibrotic, and choleric effects and anti-copper storage benefits; it also stabilizes mitochondrial function. Ursodiol can be compounded into a liquid formulation for cats.
- S-adenosylmethionine (S-AdoMet): Give 90 mg/cat PO on an empty stomach (1-2 hours before feeding), or a loading dose of 35-60 mg/kg once to twice daily and a maintenance dose of 20 mg/kg PO Q24hr. S-AdoMet replenishes glutathione and aids in cellular detoxification. It is also an anti-inflammatory and antioxidant.
- Antiemetics: these are used to decrease the frequency of vomiting and therefore enable enteral nutrition. A common antiemetic, metoclopramide (0.2-0.5 mg/kg SC TID 30 min before feeding or 0.01-0.02 mg/kg/hr as a CRI) has the beneficial effect of concurrently improving gastric emptying. Alternative anti-emetics include: maropitant citrate (Cerenia), which should be administered at 1 mg/kg subcutaneously once daily for up to 5 days; ondansetron (Zofran), which can be dosed at 0.1 mg/kg PO once to twice daily or 0.1-0.3 mg/kg IV BID-TID; or dolasetron (Anzemet), which can be administered at 0.5 mg/kg PO, SC, or IV Q24hr. Silybin-phosphatidylcholine (Marin) (5 mg/kg PO Q24hr) is yet another alternative; however, to date there are no evidenced-based studies in cats on the effects of milk thistle. Nevertheless, it is suggested that it acts as an antioxidant and free radical scavenger, decreases hepatotoxin binding, improves glutathione concentrations, aids in iron chelating, and promotes cholestasis.
- Vitamin E: Give 10-15 IU/kg/day PO (100-400 IU) in a water-soluble form twice daily.

Initially, in the face of hepatic failure and severe icterus, patients are hospitalized and monitored closely. Once stable, the patient can be discharged with a feeding tube if oral intake is not yet sufficient. Weight, appetite, and blood work must be carefully assessed. Specifically, ALT, SAP, serum protein, and serum albumin should initially be evaluated every 2 weeks, then monthly for the first 6 months, and subsequently every 4-6 months. A patient's response to therapy is typically assessed by their clinical condition and laboratory work; however, repeated biopsy or FNA may be necessary if the clinical response proves to be unsatisfactory.

**Common drugs to avoid when treating hepatic disease:** Halothane; sulphonamides; diazepam; azole antifungals; phenobarbital; tetracyclines; erythromycin or enrofloxacin if combined with theophylline or cisapride; and cimetidine if combined with theophylline, metronidazole, or chloramphenicol. Sedate with caution if lipidosis is present. If anesthesia is necessary for sampling or placing a feeding tube, induction with propofol should be considered with an inhalant, such as sevoflurane or isoflurane.

**Conclusion:** There are many pathological processes that can result in hepatic disease in the feline patient. Ideally, sampling is performed to obtain a definitive diagnosis, which allows for specific guidance with regards to therapy and prognosis. Adequate nutrition or hyperalimentation is critical for hepatic support when treating HL or preventing it from occurring as a secondary complication. Intensive care and monitoring are also key components of therapy in critically ill icteric cats.



**PATIENT**

Diesel Thompson

**SPECIES**

Feline

**BREED**

Domestic Shorthair

**SEX**

Neutered male

**AGE**

14 years

**WEIGHT**

5.94 lbs

**INTERPRETED BY**

Eric Lindquist, DMV,  
DABVP, Cert. IVUSS

**IMAGING PERFORMED BY**

Jenna Walsh, CVT

**HOSPITAL NAME**

VCA Salem AH

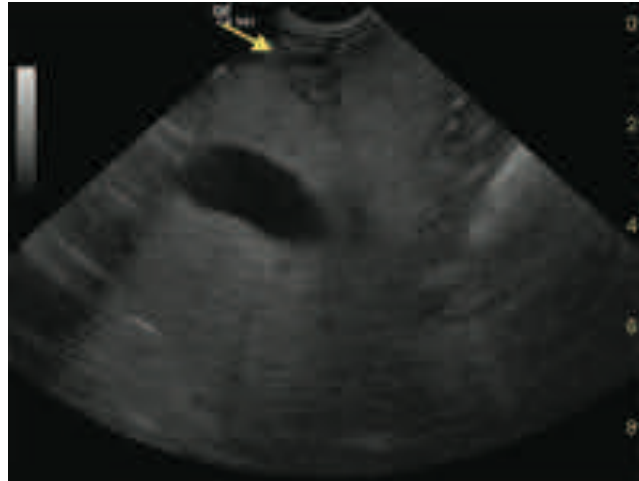**REFERRING VET**

Dr. Wermuth

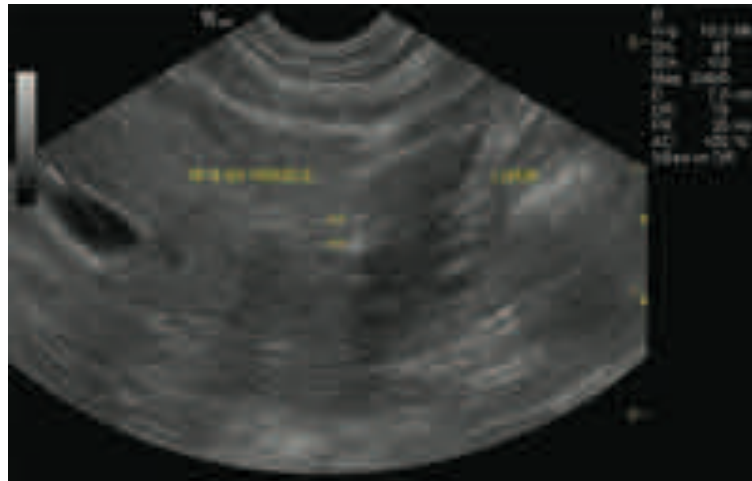**DATE**

12/2/21

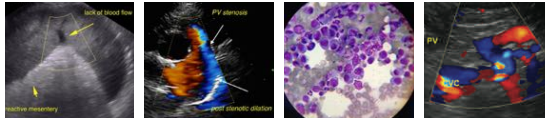
**Invoice**



Subxiphoidal long axis of the liver in a cat with hepatic lipidosis. Note the generalized increase in parenchymal echogenicity that is hyperechoic to falciform fat (arrow). The regular coarse echotexture and the visibility of the portal markings is lost. Differential diagnoses also include vacuolar hepatopathy and diffuse neoplastic infiltrate. Final diagnosis in diffuse liver disease requires sampling by FNA to evaluate cells, core biopsy to evaluate architecture and transitional (inflammatory to neoplastic) pathology.



Subxiphoidal short axis of a cat liver during ultrasound guided biopsy. The core biopsy needle is seen as echogenic line (arrowheads) within the liver parenchyma. The sonographic presentation is unremarkable in this case but the liver enzyme profile and clinical presentation indicated liver disease. Therefore, core biopsy was appropriate. At times, the clinical sonographer must sample the liver to assess clinical significance despite unremarkable sonographic findings during acute or aspecific disease. Histopathological dx: Multiple myeloma.



**PATIENT**

Diesel Thompson

**SPECIES**

Feline

**BREED**

Domestic Shorthair

**SEX**

Neutered male

**AGE**

14 years

**WEIGHT**

5.94 lbs

**INTERPRETED BY**

Eric Lindquist, DMV,  
DABVP, Cert. IVUSS

**IMAGING PERFORMED BY**

Jenna Walsh, CVT

**HOSPITAL NAME**

VCA Salem AH

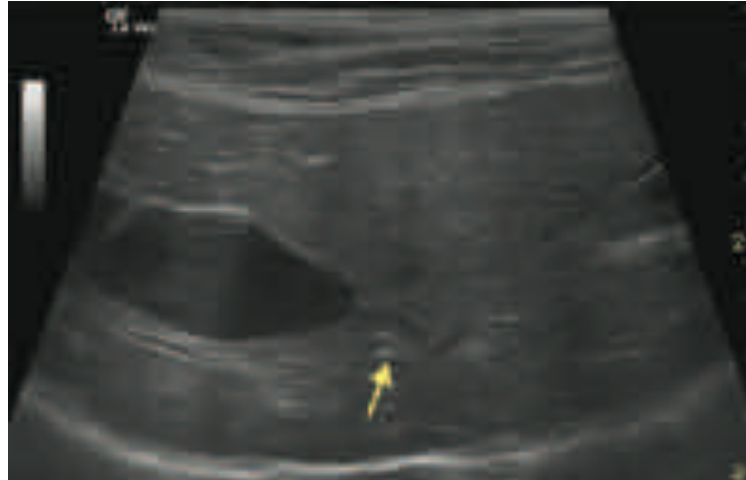**REFERRING VET**

Dr. Wermuth

**DATE**

12/2/21

**Invoice**



Subxiphoid short axis of the liver in a cat with hepatitis and significant liver enzyme elevation. The visibility of the portal markings is slightly increased (arrow). The parenchymal echotexture and echogenicity is preserved. Note the ultrasonographic changes may be very subtle despite severe inflammatory infiltration. US-guided FNA: lymphoplasmacytic cholangitis.

**References:**

Armstrong PJ, Blanchard G. Hepatic lipidosis in cats. *Vet Clin North Am Small Anim Pract* 2009;39(3):599-616.

Brian PH, Barrs VR, Martin P, et al. Feline cholecystitis and acute neutrophilic cholangitis: clinical findings, bacterial isolates and response to treatment in six cases. *J Feline Med Surg* 2006;8(2):91-103.

Brenner K, KuKanich KS, Smee NM. Refeeding syndrome in cat with hepatic lipidosis. *J Feline Med Surg* 2011;18(8):614-17.

Carreira VS, Vieira RF, Machado GF, Luvizotto MC. Feline cholangitis, cholangiohepatitis complex secondary to *Platynosomum fastosum* infection in a cat. *Rev Bras Parasitol Vet* 2008;17 Suppl 1:184-87.

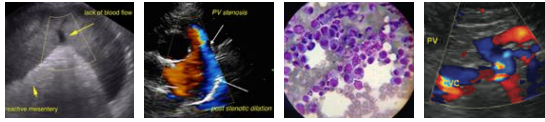
Center S. Feline **hepatic** lipidosis is a common **liver disorder**. *Feline Health Topics* 1989;4(3):1-6.

Center SA, Baldwin BH, Dillingham S, et al. Diagnostic value of serum gamma-glutamyl transferase and alkaline phosphatase activities in hepatobiliary disease in the cat. *J Am Vet Med Assoc* 1986;188:507-10.

Davenport D. Antimicrobial **therapy** for gastrointestinal, pancreatic, and **hepatic disorders**. *Probl Vet Med* 1990;2(2):374-93.

Gagne JM, Armstrong PJ, Weiss DJ, et al. Clinical features of inflammatory liver diseases in cats: 41 cases (1983-103). *J Am Vet Med Assoc* 1999;214:513.

Greiter-Wilke A, Scanziani E, Soldati S, et al. Association of *Helicobacter* with cholangiohepatitis in cats. *J Vet Intern Med* 2006;20(4):822-27.



**PATIENT**

Diesel Thompson

**SPECIES**

Feline

**BREED**

Domestic Shorthair

**SEX**

Neutered male

**AGE**

14 years

**WEIGHT**

5.94 lbs

**INTERPRETED BY**

Eric Lindquist, DMV,  
DABVP, Cert. IVUSS

**IMAGING  
PERFORMED BY**

Jenna Walsh, CVT

**HOSPITAL NAME**

VCA Salem AH

**REFERRING VET**

Dr. Wermuth

**DATE**

12/2/21

**Invoice**

Holan KM. Feline Hepatic Lipidosis. In: Bonagura JD, Twedt DC, eds: *Current Veterinary Therapy XIV*. St. Louis, MI: Saunders Elsevier; 2009:570-75.

Kordick DI, Brown TT, Shin K, Breitschwedt EB. Clinical and pathologic evaluation of chronic Bartonella henselae or Bartonella clarridgeiae infection in cats. *J Clin Microbiol* 1999;37(5):1536-47.

Mathews KA. Nutritional Support. In: Mathews KA, ed: *Veterinary Emergency and Critical Care*. Guelph, ON: Lifelearn Inc, 1996:19.1-19.29.

Otte CM, Penning LC, Rothuizen J, Favier RP. Retrospective comparison of prednisolone and ursodeoxycholic acid for the treatment of feline lymphocytic cholangitis. *Vet J* 2013;195(2):205-9.

Tams T. Management of **liver disease** in dogs and cats. *Mod Vet Pract* 1984;65(2):107-14.

Twedt DC, Armstrong PJ. Feline inflammatory liver disease. In: Bonagura JD, Twedt DC, eds: *Current Veterinary Therapy XIV*. St. Louis, MI: Saunders Elsevier; 2009:576-581.

van den Ingh TSGAM, Cullen JM, Twedt DC, et al. Morphological classification of biliary disorders of the canine and feline liver. In: Rothuizen J et al, eds: *WSAVA Standards for Clinical and Histological Diagnosis of Canine and Feline Liver diseases*. Spain: Saunders Elsevier; 2006:61-78.

Webster C, Cooper J. **Therapeutic** use of cytoprotective agents in canine and feline hepatobiliary **disease**. *Vet Clin North Am Small Anim Pract* 2009; 39(3):631-52

Weiss D, Armstrong P, Gagne J. Inflammatory **liver disease**. *Semin Vet Med Surg (Small Anim)* 1997;12(1):22-27.