



PATIENT

Asia Stewart

SPECIES

Canine

BREED

Pitbull

SEX

Spayed female

AGE

11 years

WEIGHT

59 lbs

INTERPRETED BY

Eric Lindquist, DMV,
DABVP, Cert. IVUSS

IMAGING PERFORMED BY

Sara Hansen

HOSPITAL NAME

The Veterinary
Hospital

REFERRING VET

Dr. Johnson

DATE

11/8/22

Invoice

42394

PRESENTING CLINICAL SIGNS

History: lethargy, inappetence, ascites and pleural effusion

Abnormal PE/Chem/CBC/UA Results: CBC - NSF Chem - mild elevation in GGT(16), moderate elevation in Alk Phos (341), low TP (5.1) Heart Rate and Respiratory Rates pending Blood Pressure Measurements pending Current Medications cytopoint for allergy control, cerenia today

ULTRASONOGRAPHIC EXAMINATION OF THE ABDOMEN

Urinary System

The **urinary bladder**, trigone, and pelvic urethra presented normal thicknesses and normal tone. The ureters were not visible which is normal. No uroliths or sediment were visualized and anechoic urine was present. No evidence of inflammatory or neoplastic changes was noted. Ureteral papillae were normal.

The **kidneys** revealed largely normal size and structure, corticomedullary definition and ratio (cortex 1/3 of medulla) were essentially maintained with some age-related loss of curvilinear patterns regarding the capsule and C/M junction. The cortices presented largely uniform texture with some increased echogenicity expected for his age patient. Medullary structure differed distinctly from that of the cortex and no evidence of pelvic dilation was present. The left kidney measured 6.18 cm. The right kidney measured 6.9 cm.

Adrenal Glands

Both **adrenal glands** were visualized and recognized as having normal shape, size, position and echogenicity for this breed. The phrenic vasculature, glandular echogenicity and detail were unremarkable. Capsule, cortex, and medullary definition were normal for this age patient. The left adrenal gland measured 0.6 cm.

Spleen

The **spleen** presented a smooth homogeneous parenchyma hyperechoic to liver and renal cortical parenchyma. The capsule was smooth without noticeable expansion or deviation from within the spleen or adjacent pathology. The splenic vasculature demonstrated normal volume without signs of congestion or thrombosis. No sonographic evidence of acute or chronic inflammatory, neoplastic, or infarctual changes was noted.

Liver

The **liver** was uniform with mild enlargement. Hepatic vein dilation was noted in this patient. This is consistent with passive congestion. The gallbladder presented acceptably thin walls with primarily anechoic content. The cystic and common bile ducts were normal. No pathological hepatic



PATIENT

lymphadenopathy was evident. No overt structural evidence of inflammatory, infiltrative or regenerative pathology was evident.

Asia Stewart

SPECIES

Gastrointestinal

Canine

Examination of the **gastrointestinal tract** revealed a stomach and intestine free of stasis, of normal wall thickness, acceptable curvilinear mural detail, and peristaltic activity. Small and large intestine demonstrated normal luminal chyme and stool consistency respectively. No obstructive or overt infiltrative disease was noted. No associated abnormal lymphatic activity was noted.

BREED

Pitbull

SEX

Spayed female

Pancreas

The base and limbs of the **pancreas** were observed to be largely isoechoic to surrounding omental fat. Pancreatic duct and capsular contour were acceptably normal and parenchyma respected normal curvilinear patterns. No overt evidence of active inflammatory or neoplastic disease was noted.

AGE

11 years

Free Abdomen

A large amount of ascites was noted in the abdomen.

WEIGHT

59 lbs

ULTRASONOGRAPHIC EXAMINATION OF THE HEART

The echocardiogram in this patient demonstrated normal **left atrial** size based on 3 separate methods of LA evaluation. The cranial and caudal **mitral** valve leaflets presented normal linear structure, extension in systole, and union in diastole with normal kinesis. The **left ventricle** presented normal thicknesses with linear contour and was not dilated nor restricted. The **myocardium** presented normal echogenicity without subjective evidence of significant fibrotic or ischemic disease. **Contractility** of the ventricular walls was adequate and in normal range for this patient evidenced by the fractional shortening measurement and subjective evaluation of the different regions of the myocardium. The **left ventricular outflow** tract demonstrated normal laminar flow and subjective structural integrity. Tamponade effect was noted with partial collapse of the **right auricle**. No overt masses were noted; however, an underlying neoplastic pathology cannot be ruled out. **Tricuspid** valvular assessment demonstrated adequate linear morphology and kinesis. The **right ventricle** was of normal size (1/3 diameter of LV), chordae structure, myocardial echogenicity and thickness. **Pulmonary outflow** tract assessment revealed normal valve structure, laminar flow, and diameter (approx. 1:1 pa/ao ratio). A large amount of **pericardial** effusion was noted in this patient.

INTERPRETED BY

Eric Lindquist, DMV,
DABVP, Cert. IVUSS

**IMAGING
PERFORMED BY**

Sara Hansen

HOSPITAL NAME

The Veterinary
Hospital

REFERRING VET

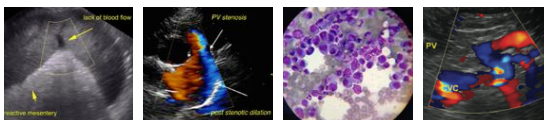
Dr. Johnson

DATE

11/8/22

Invoice

42394



PATIENT

Asia Stewart

SPECIES

Canine

BREED

Pitbull

SEX

Spayed female

AGE

11 years

WEIGHT

59 lbs

INTERPRETED BY

Eric Lindquist, DMV,
DABVP, Cert. IVUSS

IMAGING PERFORMED BY

Sara Hansen

HOSPITAL NAME

The Veterinary
Hospital

REFERRING VET

Dr. Johnson

DATE

11/8/22

Invoice

42394

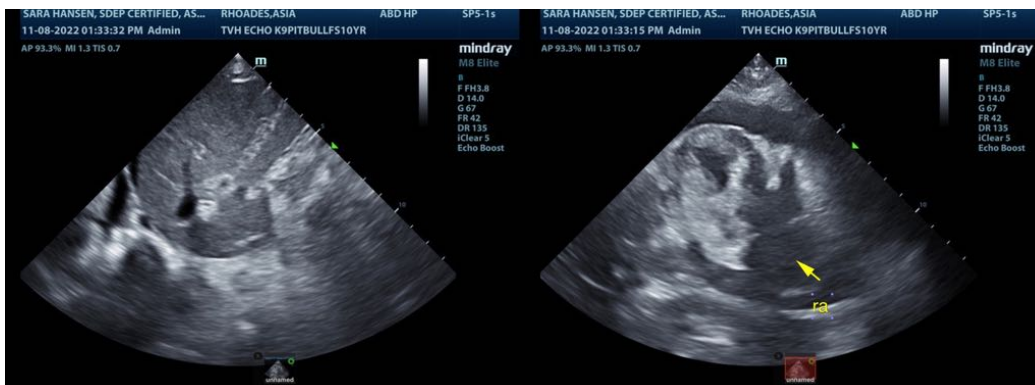
CANINE CARDIAC PARAMETERS	MR VMAX (m/s)	TR VMAX (m/s)	LA/AO (Boon method)	LA/AO (Heart Base; Swe)	FS (%)	EF (%)	EPSS (cm)
NORMAL PARAMETER	4.5-5.5	<2.7	1.3	<1.6	28-40	40-100	<0.6
PATIENT			1.0	1.18	51	83	0.22
CANINE CARDIAC PARAMETERS	HR (BPM)	AV VMAX (m/s)	PV MAX (m/s)	BODY WEIGHT	LA (2D short axis Base view) (cm)	LVIDd (Avg; 2D and m-mode short axis) (cm)	LVIDs (Avg; 2D and m-mode short axis) (cm)
NORMAL PARAMETER	50-100	0.7-1.7	0.7-1.6	BELOW	BELOW	BELOW	BELOW
PATIENT		1.9		59 lbs		4.1	

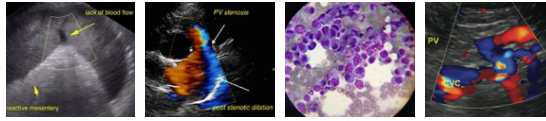
ULTRASONOGRAPHIC FINDINGS

Pericardial effusion with tamponade effect and secondary passive congestion liver pattern. Suspect underlying occult neoplastic process or idiopathic pericardial effusion. Pericarditis is less likely.

INTERPRETATION OF THE FINDINGS & FURTHER RECOMMENDATIONS

Pericardiocentesis is recommended therapeutically and diagnostically with fluid analysis +/- culture. Recheck echocardiogram is recommended in 10-14 days if the patient is stable or earlier if decompensation occurs. A mass may emerge on recheck or further stabilization can occur as well if idiopathic causes are present.





PATIENT

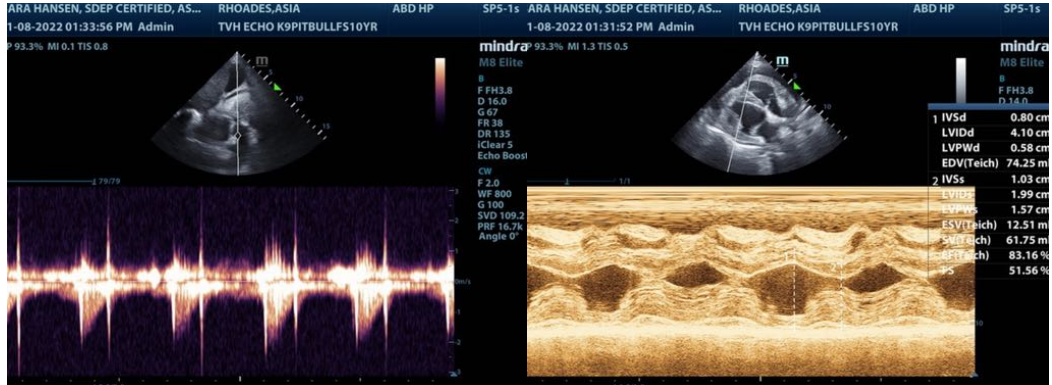
Asia Stewart

SPECIES

Canine

BREED

Pitbull



SEX

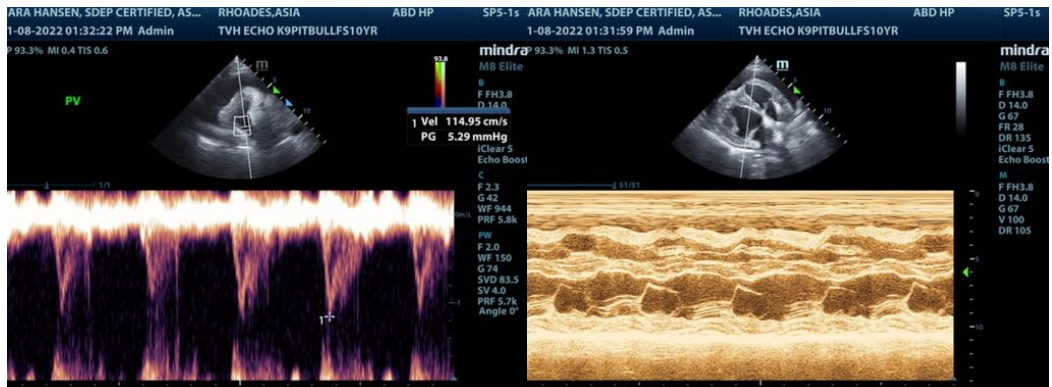
Spayed female

AGE

11 years

WEIGHT

59 lbs



INTERPRETED BY

Eric Lindquist, DMV,
DABVP, Cert. IVUSS

IMAGING PERFORMED BY

Sara Hansen

HOSPITAL NAME

The Veterinary
Hospital

REFERRING VET

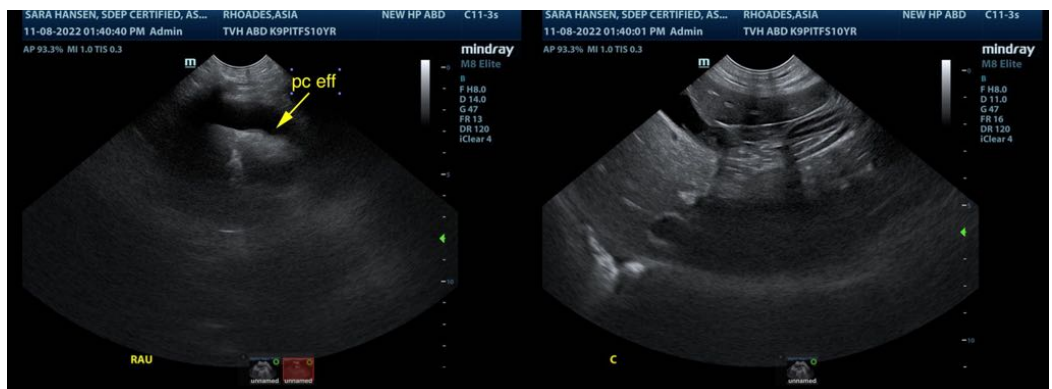
Dr. Johnson

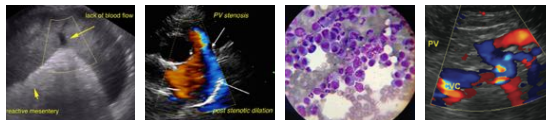
DATE

11/8/22

Invoice

42394





PATIENT

Asia Stewart

SPECIES

Canine

BREED

Pitbull

SEX

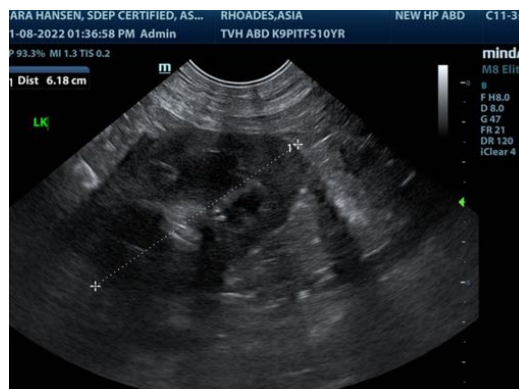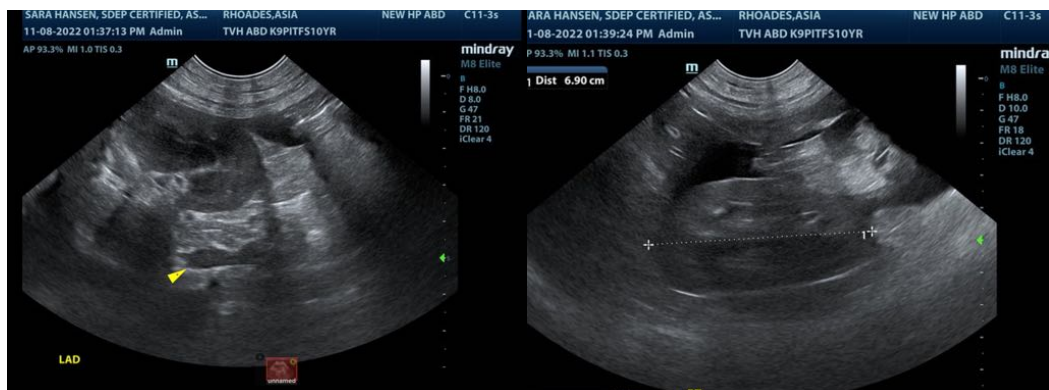
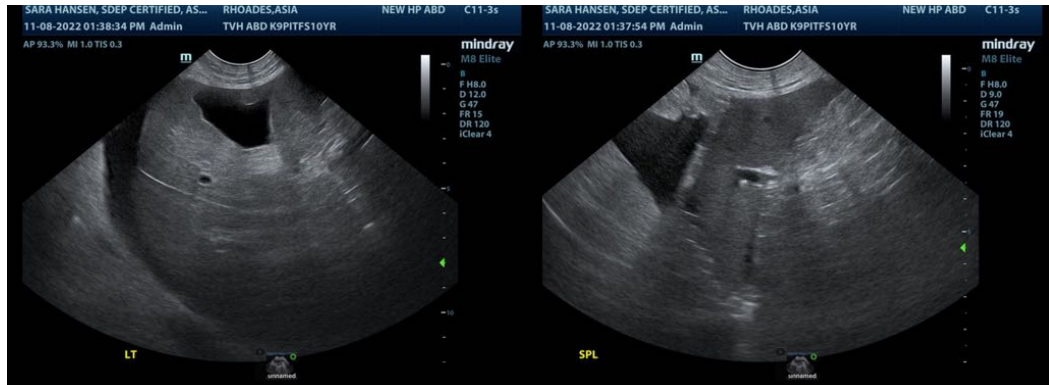
Spayed female

AGE

11 years

WEIGHT

59 lbs



INTERPRETED BY

Eric Lindquist, DMV,
DABVP, Cert. IVUSS

IMAGING PERFORMED BY

Sara Hansen

HOSPITAL NAME

The Veterinary
Hospital

REFERRING VET

Dr. Johnson

DATE

11/8/22

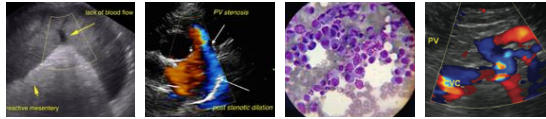
Invoice

42394

The information and recommendations provided are based on the images presented by the referring veterinarian/sonographer. No evaluation can be communicated regarding pathology that was not visible in the image/video clips provided.

Thank you for this referral. If the clinical or image interpretation does not parallel your findings or if I can be of any further assistance please contact me.

Eric Lindquist, DMV, DABVP, Cert. IVUSS
 CEO of Sonopath.com



PATIENT

Eric.Lindquist@SonoPath.com

Asia Stewart

SPECIES

Canine

BREED

Pitbull

SEX

Spayed female

AGE

11 years

WEIGHT

59 lbs

INTERPRETED BY

Eric Lindquist, DMV,
DABVP, Cert. IVUSS

**IMAGING
PERFORMED BY**

Sara Hansen

HOSPITAL NAME

The Veterinary
Hospital

REFERRING VET

Dr. Johnson

DATE

11/8/22

Invoice

42394