



PATIENT PRESENTING CLINICAL SIGNS

Loki Hill History: Pet originally presented for bloodwork for a dental. Current Medications Denamarin 225 once daily
Original bloodwork 9-2 had ALT of 416 and BUN of 34 Follow-up labs after Denamarin used for over a month performed 11-9-21 ALT 662 AST 90 BUN went from 34 to 42 11-16 pt/ptt performed along with bile acids bile acids were increased at 45 mol/L PT/PTT results were WNL

SPECIES

Canine

BREED

Labrador Poodle Mix

SEX

Neutered male

AGE

10 years

WEIGHT

28 lbs

ULTRASONOGRAPHIC EXAMINATION OF THE ABDOMEN

Urinary System

The **urinary bladder**, trigone, and pelvic urethra presented normal thicknesses and normal tone. The pelvic urethra was imaged 2.0 cm beyond the cystourethral junction. The ureters were not visible which is normal. No uroliths or sediment were visualized and anechoic urine was present. No evidence of inflammatory or neoplastic changes was noted. Ureteral papillae were normal.

The **kidneys** revealed largely normal size and structure, corticomedullary definition and ratio (cortex 1/3 of medulla) were essentially maintained with some age-related loss of curvilinear patterns regarding the capsule and C/M junction. The cortices presented largely uniform texture with some increased echogenicity expected for this age patient. Medullary structure differed distinctly from that of the cortex and no evidence of pelvic dilation was present. The left kidney measured 5.78 cm. The right kidney 5.0 cm.

INTERPRETED BY

Eric Lindquist, DMV, DABVP, Cert. IVUSS

IMAGING PERFORMED BY

Jenna Walsh, CVT

HOSPITAL NAME

Corvallis VH

REFERRING VET

Dr. Gross

DATE

11/30/21

Invoice
94210

Adrenal Glands

Both **adrenal glands** were visualized and recognized as having normal shape, size, position and echogenicity for this breed. The phrenic vasculature, glandular echogenicity and detail were unremarkable. Capsule, cortex, and medullary definition were normal for this age patient. The left adrenal gland measured 1.98 x 0.4 cm at the cranial pole and 0.5 cm at the caudal pole. The right adrenal gland measured 0.5 cm.

Spleen

The **spleen** presented a smooth homogeneous parenchyma hyperechoic to liver and renal cortical parenchyma. The capsule was smooth without noticeable expansion or deviation from within the spleen or adjacent pathology. The splenic vasculature demonstrated normal volume without signs of congestion or thrombosis. No sonographic evidence of acute or chronic inflammatory, neoplastic, or infarctual changes was noted.

Liver

The **liver** revealed slight coarse architecture. Slightly increased portal markings were noted. The gallbladder revealed a minor amount of debris that appears physiologic.



PATIENT

Loki Hill

Gastrointestinal

SPECIES

Canine

Examination of the **gastrointestinal tract** revealed a stomach and intestine free of stasis, of normal wall thickness, acceptable curvilinear mural detail, and peristaltic activity. Small and large intestine demonstrated normal luminal chyme and stool consistency respectively. No obstructive or overt infiltrative disease was noted. No associated abnormal lymphatic activity was noted.

BREED

Labrador Poodle Mix

Pancreas

The base and limbs of the **pancreas** were observed to be largely isoechoic to surrounding omental fat. Pancreatic duct and capsular contour were acceptably normal and parenchyma respected normal curvilinear patterns. No overt evidence of active inflammatory or neoplastic disease was noted.

SEX

Neutered male

ULTRASONOGRAPHIC FINDINGS

Non-specific inflammatory hepatopathy, chronic.

AGE

10 years

INTERPRETATION OF THE FINDINGS & FURTHER RECOMMENDATIONS

Leptospirosis titers are warranted. FNA could be considered for further definition or surgical or laparoscopy based biopsy for further definition. Portal hypoplasia with secondary chronic inflammatory disease is suspected.

WEIGHT

28 lbs

INTERPRETED BY

Eric Lindquist, DMV,
DABVP, Cert. IVUSS

Hepatic Support for Bile Acid Elevation +/- Hepatic Encephalopathy

Royal Canin Hepatic Support diet or Hills L/D, Metronidazole (7.5 mg/kg PO bid) over the next 14 days, Lactulose (Oral: 3.1-3.7 g/5 ml lactulose in a syrup base) long term to target 2-3 soft stools/day, with a high-quality protein supplement of minor amount of yogurt or cheddar cheese. Monitor bile acids, with attention paid to dropping albumin, BUN or cholesterol. SAME and nutraceuticals as needed. Ursodiol (10-15 mg/kg p.o. q24h) can be considered as hepatoprotectant and to enhance bile flow. Zinc serum level keep between 200–500 ug/dl. If deficient then Tx zinc acetate 1-3 mg/kg/day. Gastrointestinal protectants are recommended if the patient is anorexic.

IMAGING PERFORMED BY

Jenna Walsh, CVT

HOSPITAL NAME

Corvallis VH

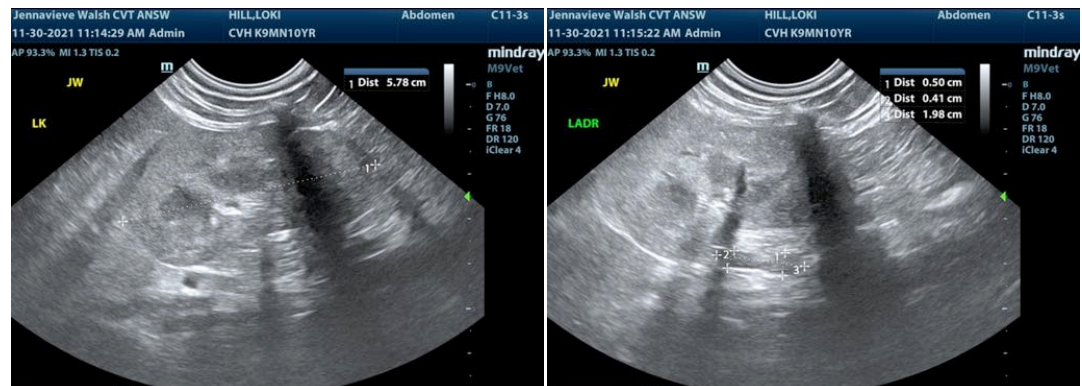
REFERRING VET

Dr. Gross

DATE

11/30/21

Invoice
94210





PATIENT

Loki Hill

SPECIES

Canine

BREED

Labrador Poodle Mix

SEX

Neutered male

AGE

10 years

WEIGHT

28 lbs

INTERPRETED BY

Eric Lindquist, DMV,
DABVP, Cert. IVUSS

IMAGING PERFORMED BY

Jenna Walsh, CVT

HOSPITAL NAME

Corvallis VH

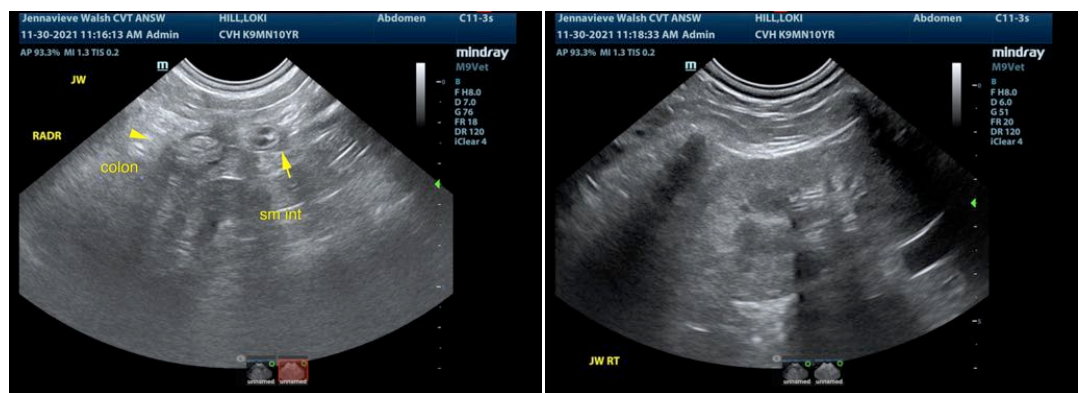
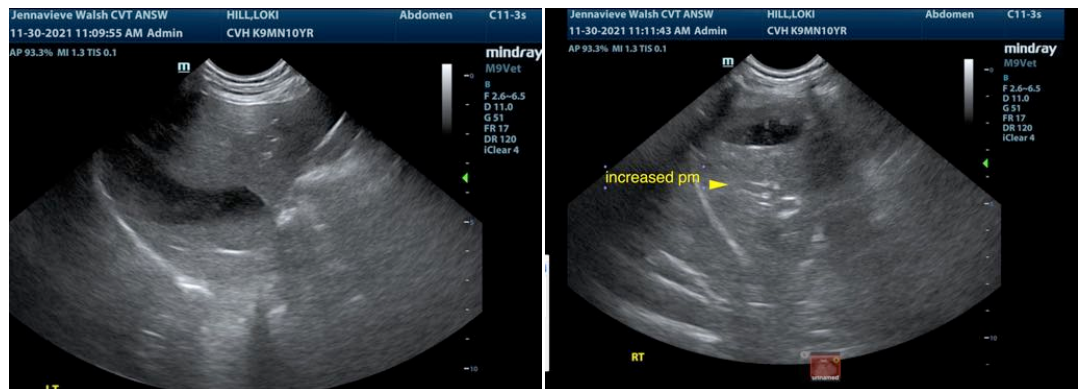
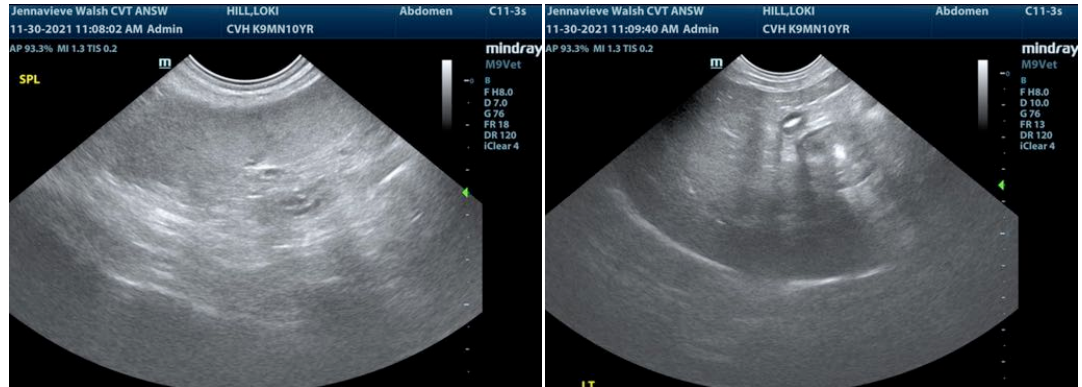
REFERRING VET

Dr. Gross

DATE

11/30/21

Invoice
94210





PATIENT

Loki Hill

SPECIES

Canine

BREED

Labrador Poodle Mix

SEX

Neutered male

AGE

10 years

WEIGHT

28 lbs

INTERPRETED BY

Eric Lindquist, DMV,
DABVP, Cert. IVUSS

IMAGING PERFORMED BY

Jenna Walsh, CVT

HOSPITAL NAME

Corvallis VH

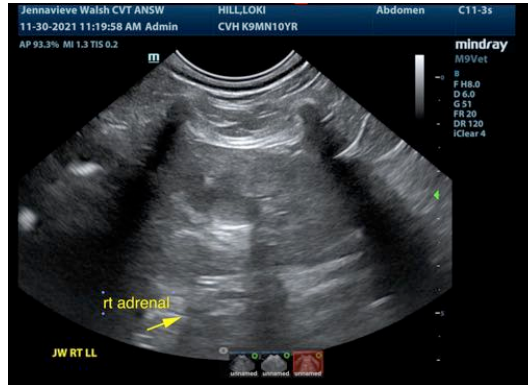REFERRING VET

Dr. Gross

DATE

11/30/21

Invoice
94210



The information and recommendations provided are based on the images presented by the referring veterinarian. No evaluation can be communicated regarding pathology that was not visible in the image/video clips provided.

Thank you for this referral. If the clinical or image interpretation does not parallel your findings or if I can be of any further assistance please contact me.

Eric Lindquist, DMV, DABVP, Cert. IVUSS

CEO of Sonopath.com

Eric.Lindquist@SonoPath.com