



PATIENT

Lark Purdue

SPECIES

Canine

BREED

Labrador

SEX

Spayed Female

AGE

11 years

WEIGHT

72 lbs

INTERPRETED BY

Eric Lindquist, DMV,
DABVP, Cert. IVUSS

IMAGING PERFORMED BY

Jenna Walsh, CVT

HOSPITAL NAME

Countryside AC

REFERRING VET

Dr. Cox

DATE

10/27/21

Invoice
92692

PRESENTING CLINICAL SIGNS

History: left sided firm submandibular swelling - r/o; foreign body, mass, reactive tissue, mast cell tumor, insect bite, open enlarged lymph node - left prescapular and submandibular node overweight dental disease Current Medications AmoxiTriClav 500mg BID, Carprofen 75mg BID

ULTRASONOGRAPHIC EXAMINATION

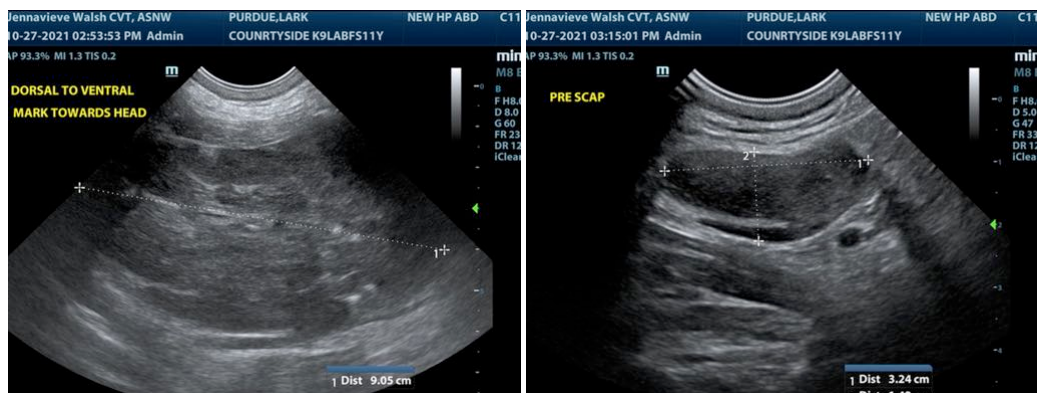
A prescapular lymph node was enlarged, hypoechoic and round measuring 3.24 x 1.42 cm. A submandibular mass was noted and measured 9.2 x 5.48 cm. A significant amount of cellulitis was present in the submandibular region. A cystic component was noted to the mass and measured 1.4 cm. The mass was completely undifferentiated and disorganized. It may be deriving from the salivary gland if the swelling is in that region.

ULTRASONOGRAPHIC FINDINGS

Undifferentiated mass with regional lymphadenopathy and cellulitis. Possible salivary gland origin; however, the structure was completely undifferentiated.

INTERPRETATION OF THE FINDINGS & FURTHER RECOMMENDATIONS

CT of the region is recommended. The mass was largely non vascular and does not appear to be associated with the thyroid. However, this is not a clean surgical scenario as significant lymphadenopathy and regional inflammation was noted. There was no obvious foreign body noted; however, this cannot be completely ruled out. Surgical debridement with lymph node biopsy and referral as well as assessment for any foreign matter may be the correct approach if no neoplasia is found on aspirate results. The primary mass appears fairly encapsulated; however, a significant amount of disrupted cellulitis type architecture was noted throughout the region.





PATIENT

Lark Purdue

SPECIES

Canine

BREED

Labrador

SEX

Spayed Female

AGE

11 years

WEIGHT

72 lbs

INTERPRETED BY

Eric Lindquist, DMV,
DABVP, Cert. IVUSS

IMAGING PERFORMED BY

Jenna Walsh, CVT

HOSPITAL NAME

Countryside AC

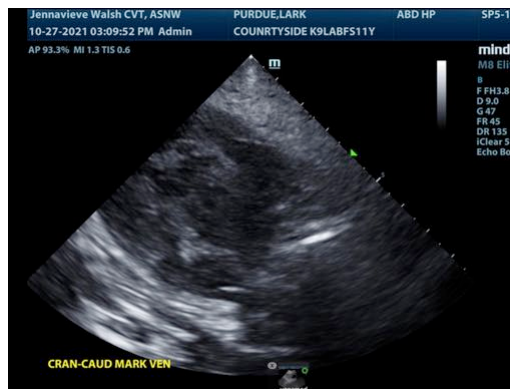
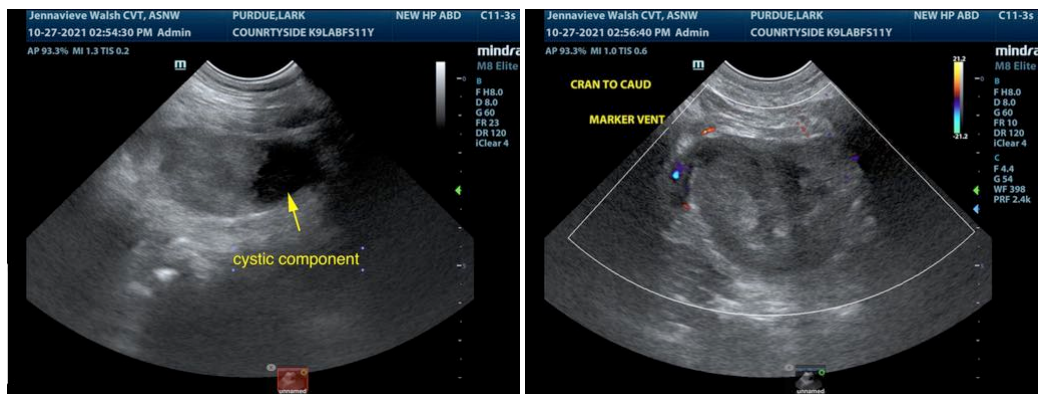
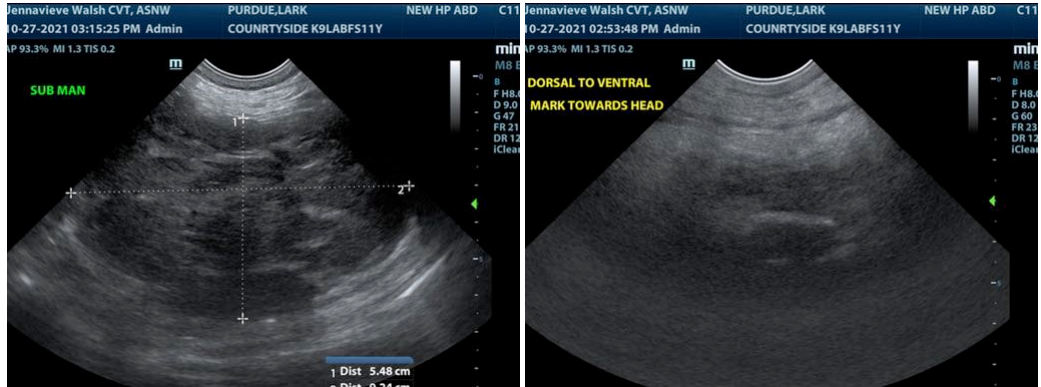
REFERRING VET

Dr. Cox

DATE

10/27/21

Invoice
92692



The information and recommendations provided are based on the images presented by the referring veterinarian. No evaluation can be communicated regarding pathology that was not visible in the image/video clips provided.

Thank you for this referral. If the clinical or image interpretation does not parallel your findings or if I can be of any further assistance please contact me.

Eric Lindquist, DMV, DABVP, Cert. IVUSS

CEO of Sonopath.com



PATIENT

Eric.Lindquist@SonoPath.com

Lark Purdue

SPECIES

Canine

BREED

Labrador

SEX

Spayed Female

AGE

11 years

WEIGHT

72 lbs

INTERPRETED BY

Eric Lindquist, DMV,
DABVP, Cert. IVUSS

**IMAGING
PERFORMED BY**

Jenna Walsh, CVT

HOSPITAL NAME

Countryside AC

REFERRING VET

Dr. Cox

DATE

10/27/21

Invoice
92692