

**PATIENT PRESENTING CLINICAL SIGNS**

Tank Jacek

History: Presented today for recurrent inappetence, possible linked to pancreatitis, minimal response to medication and support/hospitalization.

**SPECIES**

Abnormal PE/Chem/CBC/UA Results: None on IH blood work of issue on today's lab work. Current Medications Tramadol 75 BID; Pred 15 mg SID; Mirtazapine 7.5 SID,

Canine

**BREED**

Australian Shepherd

**SEX**

Neutered male

**AGE**

7 years

**WEIGHT**

32.2 lbs

**INTERPRETED BY**

Eric Lindquist, DMV,  
DABVP, Cert. IVUSS

**IMAGING PERFORMED BY**

Sara Hansen

**HOSPITAL NAME**

Eugene AH

**REFERRING VET**

Dr. Polk

**DATE**

10/20/22

**Invoice**

40204

**ULTRASONOGRAPHIC EXAMINATION OF THE ABDOMEN**

**Urinary System**

The **urinary bladder**, trigone, and pelvic urethra presented normal thicknesses and normal tone. The ureters were not visible which is normal. No uroliths or sediment were visualized and anechoic urine was present. No evidence of inflammatory or neoplastic changes was noted. Ureteral papillae were normal.

The **kidneys** revealed normal size and structure, corticomedullary definition and ratio for this age. The cortices presented largely uniform texture with normal echogenic relationship to liver and spleen. Medullary structure differed distinctly from the cortex and no evidence of pelvic dilation was present. The capsules were acceptably uniform without significant irregularities. The left kidney measured 5.35 cm. The right kidney measured 5.37 cm.

**Adrenal Glands**

Both **adrenal glands** were visualized and recognized as having normal shape, size, position and echogenicity for this breed. The phrenic vasculature, glandular echogenicity and detail were unremarkable. Capsule, cortex, and medullary definition were normal for this age patient. The right adrenal gland measured 1.83 x 1.1 cm at the cranial pole and 0.47 cm at the caudal pole. The left adrenal gland measured 1.89 x 0.53 cm at the caudal pole and 0.42 cm at the cranial pole.

**Spleen**

The **spleen** presented a smooth homogeneous parenchyma hyperechoic to liver and renal cortical parenchyma. The capsule was smooth without noticeable expansion or deviation from within the spleen or adjacent pathology. The splenic vasculature demonstrated normal volume without signs of congestion or thrombosis. No sonographic evidence of acute or chronic inflammatory, neoplastic, or infarctual changes was noted.

**Liver**

The **liver** images submitted revealed subjectively normal liver size, contour, and structure. Parenchymal echogenicity was naturally coarse and hypoechoic to the spleen. Vascular and biliary tracts were of normal volume with no evidence of congestion. The gallbladder presented acceptably thin walls with primarily anechoic content. The cystic and common bile ducts were normal. No pathological hepatic



## PATIENT

lymphadenopathy was evident. No overt structural evidence of inflammatory, infiltrative or regenerative pathology was evident.

Tank Jacek

## SPECIES

### Gastrointestinal

Canine

Examination of the **gastrointestinal tract** revealed an unremarkable stomach and small intestine regarding structure. There were minor areas of luminal fluid noted. There was no evidence of obstructive pattern. Curvilinear patterns were retained throughout the gastrointestinal tract. Areas of hyperperistalsis were noted. This is consistent with response to irritation. The colon was unremarkable.

## BREED

Australian Shepherd

## SEX

Neutered male

### Pancreas

The base and limbs of the **pancreas** were observed to be largely isoechoic to surrounding omental fat. Pancreatic duct and capsular contour were acceptably normal and parenchyma respected normal curvilinear patterns. No overt evidence of active inflammatory or neoplastic disease was noted.

## AGE

7 years

## ULTRASONOGRAPHIC FINDINGS

Gastroenteritis presentation.

## WEIGHT

32.2 lbs

## INTERPRETATION OF THE FINDINGS & FURTHER RECOMMENDATIONS

There was no evidence of significant visceral disease. The Prednisone may be suppressing the presentation. There is no evidence of significant visceral disease. The Prednisone may be suppressing a more significant presentation. Gi protocol, diet change, broad spectrum anti-parasitic protocol and fecal test is all indicated.

## INTERPRETED BY

Eric Lindquist, DMV,  
DABVP, Cert. IVUSS

## IMAGING PERFORMED BY

Sara Hansen

## HOSPITAL NAME

Eugene AH

## REFERRING VET

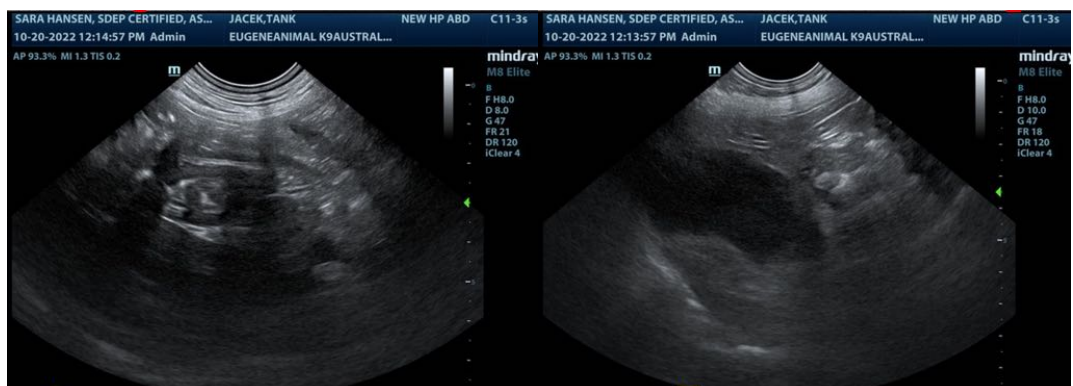
Dr. Polk

## DATE

10/20/22

## Invoice

40204





**PATIENT**

Tank Jacek

**SPECIES**

Canine

**BREED**

Australian Shepherd

**SEX**

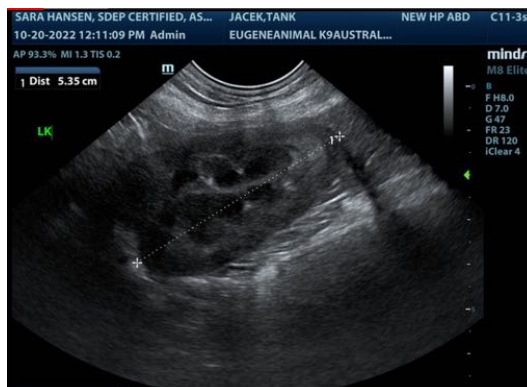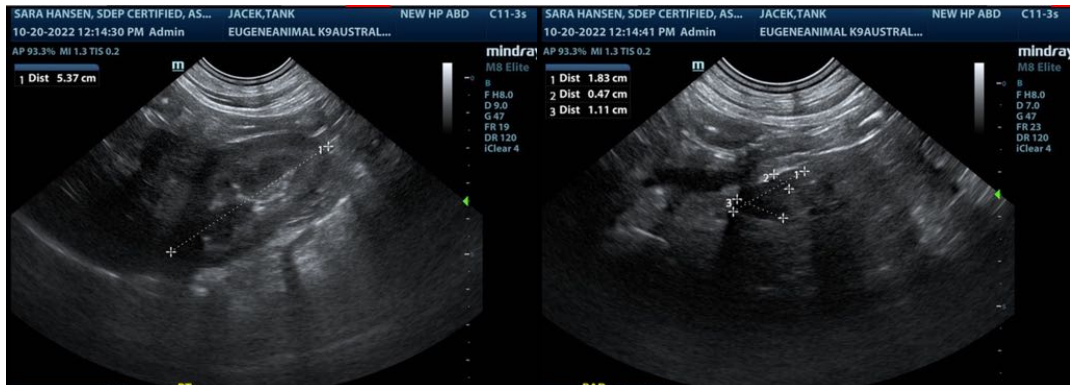
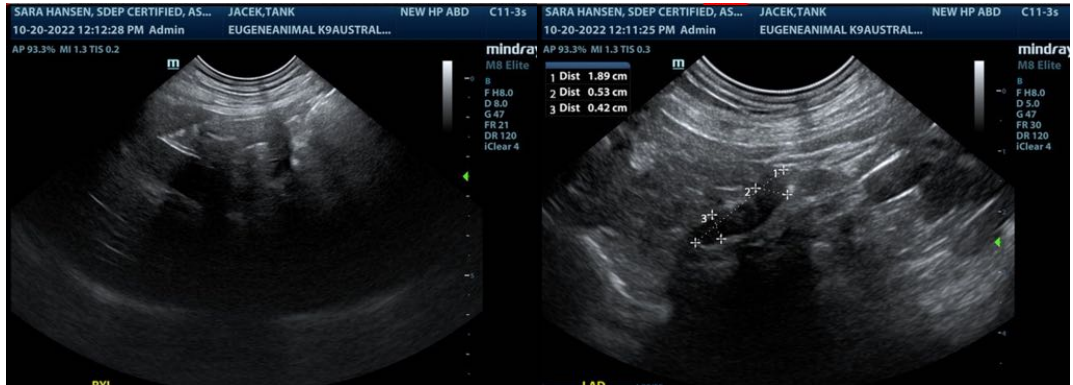
Neutered male

**AGE**

7 years

**WEIGHT**

32.2 lbs



**INTERPRETED BY**

Eric Lindquist, DMV,  
DABVP, Cert. IVUSS

**IMAGING PERFORMED BY**

Sara Hansen

**HOSPITAL NAME**

Eugene AH

**REFERRING VET**

Dr. Polk

**DATE**

10/20/22

**Invoice**

40204

The information and recommendations provided are based on the images presented by the referring veterinarian/sonographer. No evaluation can be communicated regarding pathology that was not visible in the image/video clips provided.

Thank you for this referral. If the clinical or image interpretation does not parallel your findings or if I can be of any further assistance please contact me.

**Eric Lindquist, DMV, DABVP, Cert. IVUSS**

CEO of Sonopath.com